

GENERAL STAFF MEETING  
UNIVERSITY HOSPITALS  
UNIVERSITY OF MINNESOTA

## CONTENTS

	PAGE
I. ANOUNCEMENTS	
1. CLINICO-PATHOLOGICAL .....	1
2. CHICAGO DERMATOLOGICAL SOCIETY .....	1
3. GLENN TUTTLE .....	1
4. JOSEPH A. WEINBERG .....	1
5. AWAY .....	1
6. STATE MEDICAL MEETING .....	1
7. MORTALITY REPORT .....	1
8. C. R. BARDEEN .....	1 - 2
II. APPENDICITIS ABSTRACTS (Cont.)	
FACTS, MOTIVE, MATERIAL, MORTALITY, TIME FACTOR, PER- FORATION-PERITONITIS, SOLUTION, DIAGNOSIS, SUMMARY ...	2 - 3
III. CASE REPORT	
PITUITARY TUMOR (ADENOMA) .....	4 - 7
IV. CASE REPORT	
GLIOMA OF INFUNDIBULUM .....	7 - 9

## ANNOUNCEMENTS

1. Clinico-pathological conference May 8, 1931 at 11 A.M. in Todd Amphitheater. Case to be selected.
2. Chicago Dermatological Society meets at call of its president, our own Henry Lichelson, in Minneapolis, Thursday, May 14, 1931 (evening). Richard Sutton, of Kansas City, Dermatology's Trader Horn will tell of his experiences. Cases will be presented, stories will be told.
3. Glenn Tuttle, former interne University Hospitals, now in missionary service in Africa, home on furlough, visits hospitals, marvels at changes. Speaks freely of black water fever, other tropical diseases. Welcome! A man is known by the company he keeps: former internes by the records they leave. Tuttle's records are credit to him.
4. Joseph A. Weinberg, distinguished young Omaha surgeon, liaison officer, preclinical and clinical medicine, University of Nebraska School of Medicine, receives weekly bulletin, reads same. Noting clinics, George Gray Ward, Jr., surgical tuberculosis, he came to meetings Tuesday, May 5. Saw hospital, met men. Left in evening pleased with hospitality, things he had seen, promised to return and spend more time. Everyone who met him was charmed with his manner, glad of his interest in coming, compliments Nebraska for its good fortune in having so promising a "nucleus" for future development.
5. Away. J. C. Litzenberg to Nebraska State Medical Association, Kansas City; H. A. Rieman to Rockefeller Institute reunion; Irvine McQuarrie and Associate Stoesser to East to speak of "water, water everywhere, and not a drop to drink, I have epilepsy".
6. State Medical Meeting: called outstanding event in history. Symposium of unusual merit, marked interest in Citizens Aid Society Memorial Lecture by suave, scholarly, distinguished George Gray Ward, Jr., of New York. Clinics outstanding feature, with large crowds, intense interest (selective). Presentations of wealth of material by alert clinicians spoke eloquently of

progress made. Impossible to single out any one because of unusual excellence of all. Audiences left with more kinds of "mindness", cancer, obstetric, orthopedic, etc., than ever before. Chairman expresses gratitude to all, marvels at ease of job, felt like "Gabriel" blowing trumpet, gathering clinically elect from all corners of earth.

7. Mortality report postponed until next week.

8. C. R. Bardeen, Dean, Medical School, University of Wisconsin, said in part, J.A.M.A. 96, 1511 (May 2) 1931: "One thing sought for in preceptor system at Wisconsin (sending students to practitioners for "experience" during the senior year) is to emphasize social as well as scientific aspect of medicine. In these times of stress and strain, trying to readjust medical practice to the needs of society (Note: not trying to adjust society to the needs of medical practice), it is especially important to get students to thinking along social lines. The back ground of preceptor plan is to develop "state medicine" in Wisconsin, not in the ordinary sense of bureaucratic centralization at public expense, but state medicine in the sense of cooperation of all forces in state looking to preservation of community health by cooperation of practitioners with state health officials and educational institutions, the kind of cooperation that not only encourages competition but also integration so that it all works to the advancement of medicine." Need for such plants for attempted "social awakening" of medical profession is obvious in cancer problem. Jones, T.E., Amer. Jour. Obst. and Gyn. 21:187-197 (Feb) 1931 reviewed 325 cases of carcinoma of cervix (1920-29). In cases seen in 1929 disease was just as far advanced as in 1920 notwithstanding lay publicity in interval; e.g., American Society for Control of Cancer. At first glance it would appear the cancer education is not succeeding. Splendid presentation by Mrs. Wallgren last week of social factors involved in delay in treatment of cancer of female genitalia showed most patients were aware of change in health (doubt) but uncertain and

ineffective in making medical contacts. Because of no provision for direct diagnostic clinic, sponsored by society (lay and medical) as in tuberculosis, contacts are frequently deferred for economic reasons. Conclusion which must be reached is that cancer is a social problem (time factor and specialized treatment). Motives in education are social, advertising (utilitarian (or decorative) and personal gain to advertiser) propaganda (usually selfish promotion). Most successful is advertising which arouses doubt, desire of possession of object and ease of acquisition, e.g., Doubt - halitosis (even your best friend will not tell you), Listerine (the object of your desire), ease of acquisition (any drug store). No advertising campaign is launched until all details are arranged. At present time malignancy suspects may contact own physician (education) if no economic barrier exists. If barrier exists or physician is not known social stigmata? is attached to primary consultation with "cancer clinic"; not so with tuberculosis (social approval for all classes). Until such time as the "doubts" raised by direct public health education in cancer can be satisfied only by prompt and thorough examination at the cancer clinic or your own physician (as in tuberculosis) the program will lag and the results in 1941 will be same as in 1931. As time goes on burden of diagnosis in tuberculosis is being more and more placed on shoulders of public health without loss of personal prestige to physician. Will the day ever arrive for cancer? A "socially minded profession" and a cooperating public is the answer. Applied social science (social work), a comparatively new profession is making rapid strides. Misunderstood (generally) by the medical profession? (even some of our own group?) It is not primarily interested in clerical work (admission of patients, follow up) except as they relate to the patient's own welfare. Engaged in the great problem of "individual adjustment" the work is primarily for benefit of patient and his medical condition. Motivated by knowledge of social and medical affairs (and not emotional factors) they assist in treatment, collect data for furthering knowledge (science, art, research). Report of Candidate Wallgren is first major contribution to be given to staff with

more to follow. All credit to Supt. Fesler for social vision, Frances Money for organization and development of department to high level of efficiency in short time (under great difficulties) and to Elizabeth Gardner for excellent correlation between Department of Sociology, Medical School and Hospital in training fifth year medical social workers.

## II. APPENDICITIS ABSTRACTS (Cont.)

Facts: Bower, J.O., J.A.M.A. 96: 1461-1465 (May 2) 1931 has splendid survey of subject: Entire article should be read. Figures detailed here for comparison with our figures, No. 28, Apr. 30, 1931.

1. Motive: 1913-1923, U.S. mortality rate of acute appendicitis (22.3%), Philadelphia (18%). Authorized by A. A. Cairns, director of Dept. of Public Health.

2. Material: 5,121 patients, 27 hospitals, 364 surgeons, average 13 to hospital. Time limits not stated. Survey by one person with assistance of another.

3. Age, sex, mortality by age-sex:

<u>Age</u>	<u>%</u>	<u>Males</u>	<u>deaths</u>	<u>Females</u>	<u>Death</u>
			<u>%</u>		<u>%</u>
1-10	12.1	347	6.6	274	6.9
11-20	35.2	982	3.5	821	3.3
21-30	27.5	872	4.0	541	2.4
31-40	13.6	464	7.3	233	10.0
41-50	6.4	206	15.5	117	8.5
51-60	3.5	100	21.0	81	16.0
61-70	1.5	49	22.5	30	26.7
71-80	.08	3	33.3	1	100.0

Note: Greatest number 11-20 (35.2%) least 71-80 (.08%); (88.4%) under 40, (11.6%) over 40. Males predominate in every decade. Death rates higher in males in every decade except 1-10 (6.9-6.6%), 31-40 (10.0-7.3%), 61-70 (26.7-22.5%), 71-80 (100.-33.3%). % female to % male.

4. Time factor: Cases - 5,121, deaths 306 (5.97%). Individual surgeons varied from 0-20%. Lowest hospital mortality (1.64%), highest (11.29%). Hours from onset to operation all aver-

age (61.17) lowest hospital (38.61), highest (79.8). Hours between onset and operation with recovery, all (56.5); lowest hospital (44.1), highest (80.17). With deaths (95.06), lowest hospital (38.4), highest (267.4). Admitted in 24 hours, death rate (2.55%); 48 hours (6.31%); 72 hours (8.59%) over 72 hours (11.83%). Note: Total mortality (5.97%), recovered cases duration 56.5 hours, died 95.06 hours. Mortality increased by delay (2.55-6.31-8.59-11.83%).

5. Perforation - peritonitis: incidence clean (57.1%) peritonitis (42.9%). Perforations (42.73%). Lowest hospital (18.18%), highest (66.66%). Local peritonitis (68.26%) lowest hospital (33.33%) highest (91.1%). General peritonitis (31.74%) lowest hospital (8.9%) same hospital as one with highest local! highest (66.66%). Note: nearly half had peritonitis, nearly half were perforated (42.9-42.73%) local peritonitis to general (2-1).

6. Relation to months: Lowest (Feb)-3.8% highest (Mar) 8.2%, next highest (Apr-May) 7.2%.

7. Laxatives: Deaths - total (306); deaths - laxatives given (147), deaths - laxatives not given (13). Not stated (146), deaths laxatives given (91.8%). Note: no control figures on recovered cases. This question is not yet settled. Ochsner delay treatment noted but not studied.

8. Cause of death: peritonitis (96.35%) general (80.5%) local (19.5%) other causes (3.65%). Note ratio of general peritonitis to local, incidence (1-2) deaths (4-1).

9. Hospital stay: without peritonitis (13.04) days; with peritonitis (23.4) days. At \$3.00 a day (average) loss by delay \$66,972. If each life is worth \$5000, loss in deaths is \$1,060,000.

10. Solution: 300,000 stickers to 3,813 physicians "In presence of abdominal pain give nothing by mouth. Never give a laxative. Apply an ice bag to the abdomen. Call your family physician. Abdominal pain which persists for six hours is usually dangerous." To be sent to patients? Placards in drug stores (2000). Druggist to ask purchaser of laxa-

tive if it is to be used for abdominal pain, special lectures in schools of pharmacy, radio talks, staff meeting reports, letters to referring physicians and staff and follow ups on warnings.

11. Results in one hospital: reduction in time of onset to operation (24.8%), perforation reduction (46.6%), mortality reduction (5.41-3.12%) 42.3%.

12. Diagnosis: Pain (100%), nausea (35.2-42.3%), vomiting (50-80.9%) local tenderness (89.5%) rigidity (40.6-65.5%) increased temperature (68.9-84.4%) increased pulse (44.1-84.4%) leucocytosis (79.7-95.0%). Note only one symptom is always present - pain, only one sign is uniformly present - tenderness (89%), only one corroborative test is found - leucocytosis (80%). Findings which increase in number with associated peritonitis are vomiting, rigidity, increased temperature, pulse, leucocytosis. Text book picture analysis revealed symptomatology of peritonitis.

#### Summary:

1. Acute appendicitis is a public health hospital problem.

2. Philadelphia hospital mortality 5,121 cases, deaths 347 (5.97%).

3. Disease most common under 40 and in males.

4. Death rate highest in males and over 40.

5. Mortality is in proportion to delay (56.5-95.06 hours), 2.55-6.31-8.59-11.83%.

6. Nearly half are perforated and have peritonitis.

7. Local peritonitis is twice as common as general.

8. Death rate in general to local peritonitis is (4-1).

9. Laxative problem is studied without control of recovered cases?

10. In first 24 hours, 1 patient in every 39 dies (even if operated on), in 48 hours 1 in 17, in 72 hours 1 in 13, over 72 hours 1 in 9. If operated in first 12 hours 99 out of 100 will recover. Gangrene and general peritonitis may take place in 6 hours.

11. Problem is 90% pre-hospital and 10% hospital.

**III. CASE REPORT**

PITUITARY TUMOR (ADENOMA). Path.  
Henrikson.

The case is that of an adult white male, 64 years of age, admitted to the University Hospitals 3-20-31 and died 3-22-31 (2 days).

Vision

1928 Vision began to fail gradually. Nocturia off and on.

Gall bladder

Spring 1929 developed weakness, fatigue, anorexia, dizzy spells, pain in right side and under right shoulder blade.

Liver anemia

June 1929 Consulted physician who had x-rays made. Gall bladder said to be suspicious. Consulted second physician who diagnosed anemia and prescribed liver. Has taken it ever since. Anorexia more marked if he stops the liver a short time.

Neuritis, memory

1930 Began to lose weight. Developed pain in legs and numbness and tickling in feet and hands. Insomnia troublesome. Chills at times. Memory began to fail. Had to give up responsible positions, because he was afraid to leave home for fear he would be unable to remember where he lived. Had attack when mind would go blank for two days, then gradually he would recall things. Vision becoming poorer.

Diplopia

Nov. 1930 Began to see double. Dizzy spells more frequent. Staggered when he walked.

1-26-31 Entered University Dispensary. P.E.-- Mucous membranes pale. Left pupil reacts sluggishly to light. Vision very poor. Fields limited. Teeth absent. B.P. 138-84. Reflexes normal. Hb 85; rbc's 4,480,000; Wbc's 9,400.

No acid

1-27-31 Feces positive for blood.

Gastric contents - no free Hcl. Urine - negative.

Sellar erosion

1-28-31 Referred to neurology to check for subacute combined degeneration.

Sebaceous cyst in center of scalp. Upper

and lower plates. General kyphosis. Eyes--Bitemporal hemianopsia. Can count fingers with both eyes open but none with only one open. Exophthalmus. Horizontal nystagmus. Right pupil larger than left, both react sluggishly. Optic atrophy of left disc. Reflexes--biceps and triceps 2+ Tests for toe reflexes and clonus--0. Tremor of hands on extension. Romberg negative. Female distribution of suprapubic hair. X-ray of skull ordered--report--Erosion of posterior clinoid process and compression of floor suggesting tumor in this region. Re-examination suggested. Wassermann negative.

1-31-31 Referred to eye--retinae and maculae negative except for arteriosclerosis and paling of optic discs especially left. R 20/200 and L 20/200 without glasses. R 20/100 and L 20/100 with glasses.

Gone

2-2-31 X-ray of skull - posterior clinoid process not visualized. Depression of floor. Enlargement of entire sella turcica. Findings consistent with brain tumor.

Fields

2-3-31 No improvement with refraction. Visual fields--form fields show bitemporal hemianopsia. Color fields markedly contracted. Some difficulty seeing small colored test objects.

2-4-31 Advised to enter University Hospital for operation for brain tumor. Unable to sleep nights until physician gave medicine. Now sleeps 8-10 hours a night.

Headache

3-2-31 Failed to keep appointment to enter Hospital. Developed first headache. Confined chiefly to top of head.

3-4-31 Entered University Hospitals. He lost 15-20# in last year. Laboratory--Hb 98; wbc's 6,900; P 55; L 42; M 3. Spinal fluid--clear. Pressure 150 mm of water. Jugular compression 225 mm of water. Cells - 0. Nonne - negative. Noguski positive. Colloidal gold -- 333353000. Wassermann - negative. B.U.N. 13.5. Urine - numerous Wbc's; occ hyaline casts. T 98.6; P 98.

3-5-31 No complaints. Feels fine.

Disturbed

3-6-31 Restless. Uncooperative. Woke up disoriented and excited.

3-7-31 Demands his clothes. Wants to see Superintendent of Hospital.

3-8-31 Neurological examination - Inspection--sox on, but garters over pajamas and fastened into pajamas. Attempted to pull bath robe and pajama coat off over his head. Some difficulty in distinguished odors in tests. Middle abdominal reflexes--3, lower- 4; cremaster-0. Tests for toe reflexes and clonus normal. Muscle tone poor. Slight tremor. Coordination normal. Fingers all hypotonic. Hair in axilla and legs scant; none on chest. Straight pubic hair. Diagnosis: Pituitary tumor encroaching on left. Eye consultation--Fields smaller than on previous examination.

3-9-31 Thinks there are "spooks" around here. Forgets where he puts things. Wants to know if he can have breakfast at 4 P.M. Blood sugar tolerance test--1st, .08; 2nd .127; 3rd .160; and 4th .140.

X-ray

3-10-31 X-ray of chest - Nodule in left upper lobe, exact nature of which cannot be made out. May be metastasis.

3-11-31 Loses self in hall. Confused. Crying. Hears voices. Tried to find wife in next room during night.

Lucid

3-12-31 Much disturbed because of his actions last night. Wants to go home until things "clear up". Realizes he does things which he should not. Thought a fight was going on in next room; got up to see. Very angry when told to go back to bed. Imagines something is wrong. Was sure nurses needed protection. Says liquor is being made here and is going to take the matter to court tomorrow.

Worse

3-13-31 Much confused. Insists on going home.

3-14-31 Very discouraged when told of operation and prognosis. Not as confused today.

Better

3-15-31 Elated because of good night's sleep.

3-16-31 Very pleasant. Laughs about his doings when confused and remembers what he did during the previous days.

3-17-31 Discharged. To return for operation in three days.

3-20-31 Returned for operation. Melancholy.

3-21-31 8:00 A.M.-- to operating room. Operation: Under novocaine infiltration and a few minutes of ethylchloride inhalation, a horse-shoe shaped flap was turned down over the right frontal area. The frontal lobe was lifted up and the anterior portion of the tumor exposed where it was anterior to the chiasma of the optic nerve. Severe bleeding was produced from a vessel in the sulcus along the posterior border of left wing of sphenoid, and patient became unconscious following this hemorrhage. The tumor mass was needled in an attempt to aspirate it but it was a solid tumor. The right ventricle was tapped to decrease the tension previous to the closure. The usual closure was made. 11:30 A.M.-- returned from operating room unconscious. P 90; R 22. 12:25 P.M.--B.P. 140/100. Face cyanotic. Sutures taken through tongue to hold it up. "Convulsion" of facial muscles. 12:33 P.M.--"Convulsion" ceased. 12:40 P.M.--pulse irregular; whole body shaking. 1:20 P.M.--"Convulsion" lasted 3 min. 2:10 P.M.--"Convulsion" lasted 7 min. 2:45 P.M.--"Convulsion" lasted 5 min. 3:45 P.M.--"convulsion" lasted 3-1/2 min. 3:50 P.M.--pulse 128. Some bleeding in dressings. Continuous proctoclysis. 8 P.M.--slight "convulsion". 8:30 P.M. 34 cc bloody fluid by spinal puncture. 8:45 P.M.-- 25 cc of 50% glucose intravenously. 9:30 P.M.--breathing labored. 10:30 P.M. choking from secretions in throat. B.P. 78/138. 11 P.M.--pulse poor quality. Turned on side to drain mucous from mouth. 11:30 P.M.--breathing shallow. External heat applied to body. 12 M-- pulse weakening. 1 A.M.--B.P. 68/36. Bilateral positive Babinski. Right side of face paralyzed. Pupils do not react to light. 2 A.M.--pulse almost imperceptible. 5 A.M.--respirations labored. Pulse imperceptible. P 120; T 103. 7 A.M.--much foul mucous draining from mouth. 8:15 A.M.--very foul odor from drainage from mouth. 8:25 Exitus.

Autopsy: The body is that of a white male, 175 cm. long, weighing 180#, well nourished, and well developed. Rigor is present; hypostasis is purplish and posterior; no cyanosis, edema, no

jaundice. The pupils are regular and equal, measuring 2 mm. in diameter. The right diaphragm is at the 4th intercostal space and the left at the 4th rib. The pubic hair has female distribution. The hair has been shaven off the head. There is an operative wound on the right side of the head. The abdominal fat is 2 cm. thick.

The PERITONEAL CAVITY contains no fluid. The APPENDIX hangs over the brim of the pelvis and extends downward into the pelvis. It is 6 cm. long.

PLEURAL CAVITIES. 20 cc. of straw-colored fluid is found in the right. There are two grayish-white plaques in the visceral pleura in the left apex. The PERICARDIAL SAC is normal.

The HEART weighs 350 Gm. The foramen ovale is closed. The coronaries contain a few yellowish, calcified areas but are patent throughout. There is a firm, grayish-pink, irregular patch 3 x 1 mm. at the margin of the right aortic leaflet. There is a similar but smaller patch below the margin of the posterior aortic leaflet. The mitral valve is normal.

The ROOT OF THE AORTA shows only moderate sclerosis.

The RIGHT LUNG weighs 550 Gm. and the LEFT 650 Gm. Both show congestion at the bases.

The SPLEEN weighs 150 Gm. and is very soft and, on cross section, shows deep, purplish-red, very friable pulp.

The LIVER weighs 1350 Gm. There are gray, thickened patches on the surface beneath the intercostal margin.

The GALL BLADDER is slightly dilated and contains a brownish fluid which passes downward through the ducts on pressure over the fundus. The common duct is patent.

The GASTRO-INTESTINAL TRACT is normal.

The PANCREAS is normal and weighs 125 Gm.

THE ADRENALS show postmortem autolysis of the medulla.

The LEFT KIDNEY weighs 145 Gm. and the RIGHT weighs 140 Gm. There is coarse pitting over the surface. On sections made by cutting, the cortex bulges. Two small cysts 2 mm. in diameter containing light yellow fluid are found in the right kidney. There are hemorrhagic patches at the base of the BLADDER.

The abdominal AORTA shows moderate sclerosis.

The GENITAL ORGANS show female distri-

bution of suprapubic hair, otherwise normal.

The lymph NODES are not felt.

The organs of the NECK are not examined.

HEAD. There is the usual flap incision from the level of the upper margin of the ear to the midline of the head extending from 2 cm. above the right eyebrow posteriorly to a point 1.5 cm. behind the posterior margin of the ear. It is 7 cm. wide at the base. The diameter is 13 x 13 cm. On opening the suture line, a portion of the cerebrum is found bulging through along the osteal margin. There are no signs of infection. The dura has been opened by radiating spoke-like incisions. The triangular flaps are shriveled and lie along the osteal margin. The right frontal lobe is softened. On lifting the brain up from the floor of the calvarium, intradural and subarachnoid hemorrhage is found over the base, especially on the right side. There is a tumor the size of two conjoined walnuts (5 x 4 x 4 cm.) arising from the floor of the third ventricle and involving the pituitary gland. It is a light gray-pink, soft and nodular, the nodules varying in size from 5 x 2 mm. It extends slightly to the left, encroaching on the left cerebral peduncle. Considerable lateral pressure is exerted on the optic chiasm. The root of the fifth nerve is incorporated in the tumor mass on the left side. The posterior clinoid processes are eroded. The posterior wall of the right sphenoid sinus is eroded and pus can be seen within it. The specimen is preserved intact and sent to the Neurologic Department, who will describe the brain and tumor after sections have been made.

#### Diagnosis

1. Pituitary tumor (adenoma).
2. Subtemporal decompression.
3. Intra-dural and subarachnoid hemorrhages at base of brain.
4. Erosion of both posterior clinoid processes.
5. Erosion into right sphenoid sinus.
6. Encephalomalacia of the frontal and temporal lobes (post-operative).
7. Hypostatic congestion of the lungs.
8. Slight chronic passive congestion of liver and spleen.
9. Rheumatic endocarditis (aortic).
10. Moderate coronary sclerosis.
11. Moderate arteriosclerosis.

12. Female distribution of supra-pubic hair.

13. Puncture wounds in antecubital spaces.

14. Old healed pleural tuberculosis at left apex.

Comment:

Note signs of increased pressure, local signs and hormonal (pubic hair). Starts out like gall bladder disease, pernicious anemia (did he have it as well?). Note loss of memory early, diplopia, sellar erosion. Operation complicated by uncontrollable bleeding. (Illustrations).

IV. CASE REPORT

GLIOMA OF INFUNDIBULUM. Path.  
Henrikson.

The case is that of an adult white female 47 years of age, admitted to Health Service 2-16-31 and died 2-16-31 (3 hours).

Vision

12-14-26 - Complains of eye trouble. Eyes corrected. R 15/20, L 15/40. Hearing: both ears have 0% loss. B.P. 130/82. Weight 135#. Height 63-3/4". Urine negative. 1020 spec. grav. Kolmer negative. Hb. 80%.

Infections

3-12-28 Weight 135#. Vision R 20/70, L 20/70. Corrected R and L 20/30. Hearing - right 2% loss. L 3% loss. Vital capacity 2,000 cc. B.P. 112/85, Hb. 68%. Complains of having had 4 colds this winter. Acute rhinitis present on examination. Advised to drink more water.

Pain, dizziness

4-15-29 Attacks of pain in the head and dizziness began.

Eyes

4-15-30 Complains of aching eyes, sensitivity of eyes to light and inflamed lids. Is just learning to wear bifocals. Suddenly developed pain over the top of the head, dizziness and blurring of vision. Recurred with increased severity for 4 days, then stopped suddenly on 5th day. Physical examination - Weight 136#. T 98.6, P 88, B.P. 130/74. Urine negative. Except for one devitalized

tooth there were no positive findings. Diagnosis - 1. Subarachnoid hemorrhage (?). 2. Probably some vasomotor intracranial disturbance.

Headache, attacks

5-20-30 Entered Health Service because of continuation of severe frontal headaches associated with great physical oppression and a sensation as though a cloud were closing in about her. These attacks last 5-45 minutes and leave as suddenly as they come. Lately they have been coming as often as every hour, leaving her weak and miserable. Physical examination - Fundi appear normal. Advise refraction. Knee jerks, biceps and triceps reflexes hyperactive. B.P. 142/104. Menstruates regularly. Urine negative. Hb. 100%, WBCs 8,850, P 60, L 36, M 6, E 2. U.N. 13.06, Creatinine 1.06. Sugar .110, Kolmer negative.

Gone

5-21-30 Comfortable.

5-25-30 No more headaches since day of admission. Discharged.

5-26-30 Sinus x-rays - negative. Still having trouble wearing bifocals. Media clear. Fundus negative. Tension of eyeballs to palpation negative.

Tonsils?

10-10-30 T. 99.2. Moist rales in right base. Increased bronchial breathing. Tonsillectomy which was to have been done tomorrow postponed.

Faints

10-15-30 Fainted suddenly at noon without warning. Regained consciousness in bed in Health Service. Had terrific headache, felt dizzy and weak. Another two attacks later in day, not associated with fainting. Began in back of neck as a dull ache, then the frontal region ached terrifically. Feels better in dark with eyes closed. Ice caps help at times. Her friends state that they can tell by her eyes when she is to have an attack. Occasionally a ringing and dull ache is present in her ears. Left ear seems to pulsate at times. She also has a fullness in her soft palate during headaches. Physical examination - Tonsils enlarged. Varicose veins above the knees. Laboratory - Hb. 102%, WBCs 8,350, P 64, L 35, B 1. Urine - Spec. grav. 1010. Negative. 10-16-30 Complains of headaches. Given



luminal, gr. i, H. S.

10-17-30 Only one headache of short duration. Neurological examination - Showed the pupils slightly irregular and ovoid. Diagnosis cannot be made on available data. Should have thorough study. Advise trying trichlorethylene.

10-18-30 9:30 A.M. Spinal puncture. No headaches. Slept well.

#### Gone

10-19-30 Comfortable. No complaints.

10-20-30 Discharged.

#### X-ray - Sella

12-23-30 X-ray of skull - There seems to be a slight increase of intracranial pressure. A slight amount of calcification is present within the pineal gland. There is also a dense calcified shadow in the region of the right parietal bone approximately 1/2 - 1" away from the skull. The exact nature of calcification is not evident. It may be either within the brain substance or probably within the dura. The sella turcica appears to be somewhat larger than normal. There is definite depression of floor. Diagnosis:  
1. Increased intracranial pressure. 2. Slight enlargement of the sella turcica. 3. Calcification within the skull, type undetermined.

#### Edema

1-9-31 Ophthalmoscopic examination - Shows early papilledema in each eye, more marked on right. The arterial caliber seems somewhat irregular, and light streak is likewise variable (evidence of arteriolar-sclerosis?).

There is a moderate reduction of hearing on left - nerve deafness type. The reflexes are normal. Neurologically there were no other abnormal findings.

#### Final illness

2-16-31 Severe headache. 4:20 P.M. became unconscious. Pulse 40. 4:30 P.M. Becoming conscious. Neurological examination was made at once. Except for an ophthalmoscopic examination which showed mild edema of right nerve head and slight edema of left, there were no abnormal findings. The patient chatted and joked as usual. P 72. 5:30 P.M. Complained of headache and became unconscious in wheel chair on way to station <sup>CV</sup> from health service. 5:40 P.M. P 96, irregular, rapid and weak. Respirations

normal. Pulse gradually became stronger, although remained totally irregular. 5:50 P.M. P 120, B.P. 108/7  
6 P.M. P 108, Responds when spoken to. 6:10 P.M. P 96. Pain in back of head. No paralysis. Lumbar puncture advised if attacks continued. 6:15 P.M. complains of fullness over temporal region. 6:20 P.M. More comfortable. 6:30 P.M. Sleeping. 6:45 P.M. Severe headache. Moaning. Crying out with pain. Restless. Emesis of 100 cc. of yellowish fluid. Pulse slow and irregular. 6:55 P.M. responds when spoken to. Mind not clear. Pulse very weak and fast at times. 7:10 P.M. Mind clearer, P 96 and of better quality. 7:40 P.M. More comfortable. Laughing and talking. 7:50 P.M. Gave several moans and became unconscious. Breathing stertorous. Rate 24. 8 P.M. Face flushed, then pale, then deeply cyanotic. Artificial respirations begun. 8:10 P.M. Pulse faint. Respirations stopped. 8:15 P.M. Gasped. Frothed at the mouth. 8:20 P.M. Pronounced dead. Diagnostic impressions: Probably a frontal brain tumor (more likely right than left sided)

#### Autopsy

There are 5 vaccination marks on left arm close together. The length is 5'5". Weight 164#. Development and nourishment are good. Rigor is present. Hypostasis is purplish and posterior. There is no edema. There is marked cyanosis of finger tips and lips. There is no jaundice. The pupils measure 5 mm. in diameter each and are regular. The diaphragm is at 3rd rib on left, the right 4th rib. There are extensive adhesions between diaphragmatic surface of liver and diaphragm, between spleen and liver, and between spleen and diaphragm. The appendix is retrocecal, atrophic type and bound down in peritoneal fat. There are a few adhesions to right upper lobe of lung on right.

The heart is small, weighing 250 grams. There are a few arteriosclerotic patches at base of aorta. The coronaries are patent and not sclerotic.

The left lung weighs 340 grams, the right 380 grams. There is generalized congestion.

The SPLEEN weighs 180 grams and is very soft and flabby. It is deep purplish red and markedly congested. The LIVER weighs 1400 grams and is also very

soft. The surface is roughened due to the many adhesions to diaphragm on all parts of the upper surface. The GALL BLADDER is normal. The DUCTS are patent. The COLON is markedly redundant.

The PANCREAS weighs 125 grams and is purplish red. It is very soft, the lobulations are distinct and congestion is present throughout. The ADRENALS show some postmortem autolysis. The LEFT KIDNEY weighs 150 grams, the RIGHT 200 grams. Both are markedly congested. The capsules strip easily. The kidney markings appear normal. The BLADDER is distended with urine. The interior surface is smooth. The CUL DE SAC is obliterated and it appears as though the UTERUS were missing. A small lump can be felt to the left of the rectum. On removing the genital organs, the UTERUS was found to be very small, and was situated on the left side of the rectum posteriorly. There were 2 small polyps in the cervix. The left OVARY was small and contained a hazel nut sized cyst. The right was markedly atrophied, but no cysts were present. On opening the cyst of the left ovary, a clear fluid poured out. The vaginal mucosa contains a great number of small brownish spots 1-2 cm in diameter.

The HEAD is opened and the convolutions of the brain are markedly flattened, and look slightly anemic. There is a small, soft, brownish tumor replacing the infundibulum and extending on the floor of the 3rd ventricle. There is slight dilatation of the lateral ventricle. There is thinning of the posterior clinoid process and cone-formation in the anterior and posterior fossa.

#### Diagnosis

1. Infiltrating glioma of the infundibulum.
2. Slight hydrocephalus.
3. Congestion of the liver, spleen, kidneys, pancreas and lungs.
4. Senile atrophy of the uterus, with multiple polyps of the cervix.
5. Ovarian retention cysts.
6. Redundant colon.
7. Puncture wounds of the right ear.

#### Addition to Diagnosis

8. Multiple tuberculoid structures in the lungs.

#### Microscopic sections of the:

1. Liver show fatty metamorphosis around central veins and few small focal areas of lymphocytic infiltration.

2. Spleen show sinuses engorged with red cells. Malpighian corpuscles prominent.

3. Kidneys show areas of marked engorgement by red cells. In these places cells lining proximal tubules are swollen and encroach on lumen.

4. Pancreas show changes due to post-mortem autolysis.

5. Uterus show marked thickening of vessels. Cells lining tubules contain very little cytoplasm. The polyps seen grossly are benign. The ovaries are atrophic. Only a few corpora albicans are seen.

6. Adrenals and Pituitary gland are normal.

7. Heart show areas of fatty metamorphosis.

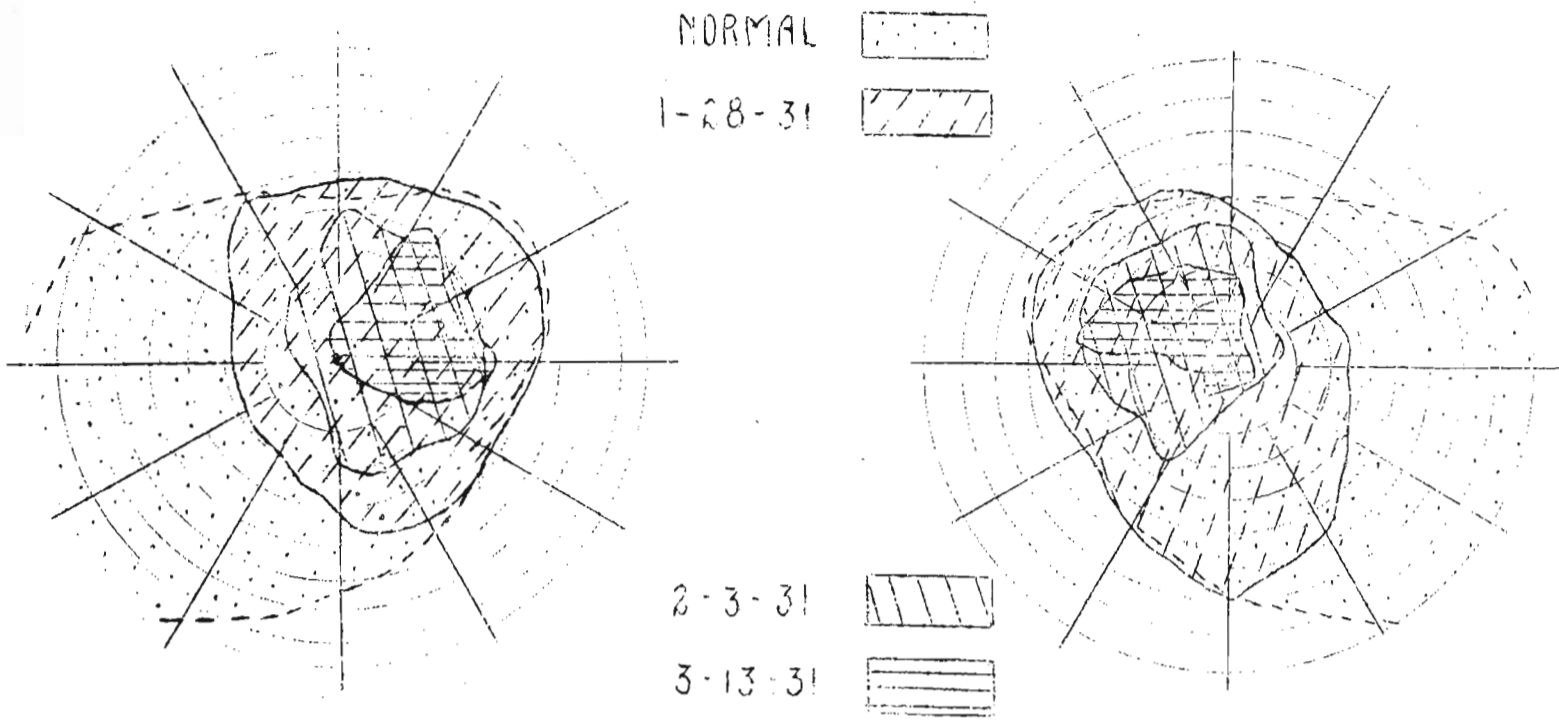
8. Brain show glial cell infiltration in floor of third ventricle. There are oval cells showing mitosis in small patch of red cells on outer surface of one section.

9. Lungs show small patches of round-cell infiltration scattered fairly thickly throughout the parenchyma. In these patches are spitheloid cells forming fairly definite tubercles. Stains for tubercle bacilli fail to show the bacilli.

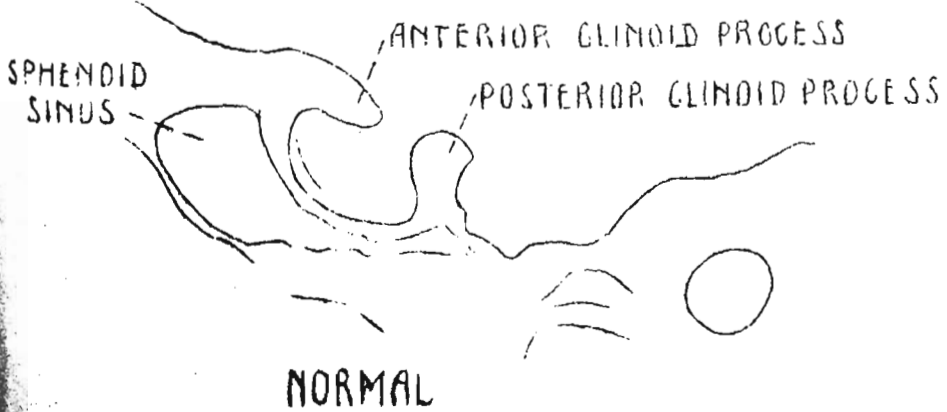
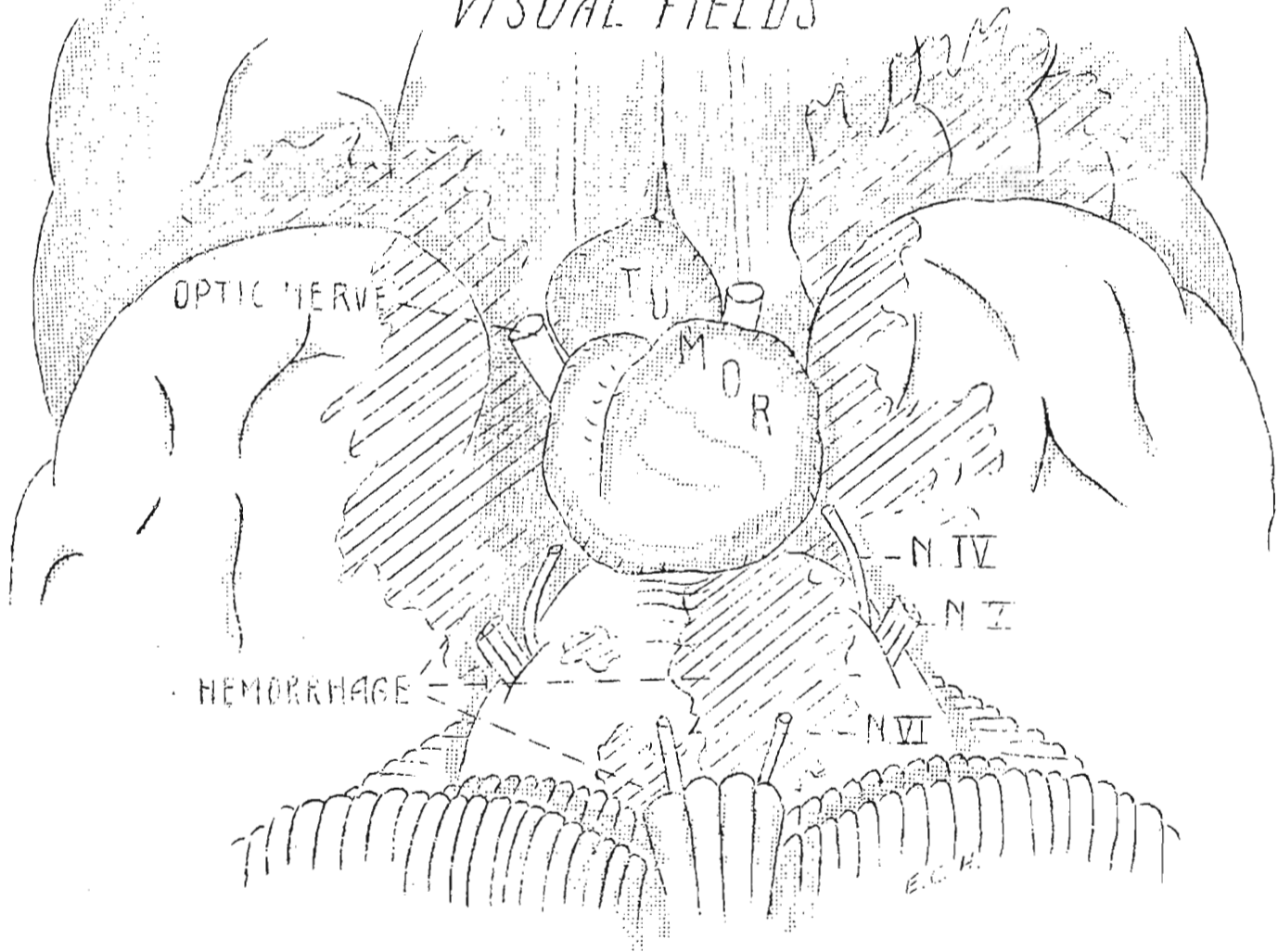
#### Comment:

Signs of increased intracranial pressure suggested brain tumor. Pressure signs (local) in sella turcica, eyes (vision and grounds), no fields done. Unusual finding of small tumor of infundibulum, of malignant location. Tuberculoid structures in lungs did not have same appearance as brain tumor. (Illustrations).

CASE I.



VISUAL FIELDS



XRAY TRACINGS

CASE 2.

