

**Proximal bone levels of plateau-designed,
press fit implants adjacent to a natural teeth
and implants**

A THESIS

SUBMITTED TO THE FACULTY OF THE GRADUATE SCHOOL
OF THE UNIVERSITY OF MINNESOTA

BY:

Alfredo Montes Imeri, D.D.S.

IN PARTIAL FULFILLMENT OF THE REQUIREMENTS
FOR THE DEGREE OF
MASTER OF SCIENCE

December 2009

© Alfredo Montes Imeri 2009

ACKNOWLEDGMENTS

I gratefully acknowledge the support of the **Bicon Implant Center** in Boston, MA, for their cooperation and access to patient records.

A special thanks to **Dr. Vincent Morgan** for his enthusiasm and for treating me so nice and made me feel so welcome at Bicon Implant Center in Boston, MA

I would like to thank **Dr. John Schulte** and **Dr. James Holtan** for their help and support during my residency and throughout this study. I am always going to be thankful to them for the great opportunity of doing The Graduate Prosthodontics' Residency.

Also, I gratefully acknowledge **Dr. Heather Conrad** for her friendship, participation and help in this study.

DEDICATION

I dedicate this thesis to my dear wife, **Mariela L. Pineda Donis**, for her love, support, and for always being by my side.

To my parents, **Heinz Montes** and **Telma Imeri de Montes** for their unconditional support, understanding and love.

To my brother **Julio Montes Imeri** and my sister **Ivonne Montes Imeri**, for their love, and support.

ABSTRACT

STATEMENT OF PROBLEM. Successful implant treatment requires a favorable biological response of living tissues to a foreign material. Even with a favorable pre-surgical evaluation, negative changes such as crestal bone loss can occur after the implant is placed, which can result in an esthetic failure. Controlling crestal bone loss around an implant placed adjacent to a natural tooth or to another implant represents an important challenge for present day prosthodontics. Guidelines on the distance between an implant and a natural tooth or another implant have been published as being an important factor in proximal bone preservation.

PURPOSE. The purpose of this study was to retrospectively evaluate pre-treatment and post-treatment proximal bone levels of a single tooth, plateau-designed, press fit implants (Bicon®) utilizing a locking tapered, implant to abutment connection adjacent to a natural teeth and to a plateau design Bicon® implants. The bone levels were evaluated separately for those implants that were closer to a natural tooth or to another implant than the recommended guidelines. Bone levels were also measured on mesial and distal surfaces of all implants as well as the crestal bone levels between 2 implants. The relationship between implant spacing and crestal bone levels was to be determined.

MATERIAL AND METHODS. A retrospective cohort study was designed to evaluate pre-treatment and post-treatment proximal bone levels of a single tooth, plateau-designed, press fit implants (Bicon®) utilizing a locking tapered, implant to abutment connection adjacent to a natural teeth and to a plateau design Bicon® implants. The cohort was derived from patients who received 1 or more single tooth, plateau-designed, press fit implants between 1995 and 2005. One hundred and sixty-nine implants with 338 proximal surfaces were included in this study. Of the 338 proximal surfaces, 120 were adjacent to a natural tooth, 192 were adjacent to an implant, and the remaining 26 surfaces were adjacent to an edentulous area. The mean follow-up time was 4 ± 2.3 years. Bone levels and changes in bone levels over time were determined by direct measurement of non-standardized digital periapical radiographs. All measurements were made by using a software measuring tool (DIGORA; Soredex, Tuusula, Finland) at $\times 3.0$ magnification. Student T-tests were used to evaluate the statistical significance between pre-treatment and post-treatment proximal bone levels of natural teeth adjacent to implants. Level of significance was set to alpha 0.05. Descriptive statistics were used to report bone levels on implants adjacent to a natural tooth, another implant, or an edentulous area, as well as the crestal bone levels between 2 implants.

RESULTS. There was no significant difference ($P=0.25$) between pre-treatment proximal bone levels and post-treatment proximal bone levels on a single tooth, plateau-designed, press fit implants (Bicon®) utilizing a locking tapered, implant to abutment connection adjacent to a natural teeth and plateau design Bicon® implants.

CONCLUSIONS. Bone levels on implant surfaces adjacent to another implant and bone levels on natural teeth adjacent to implants can be expected to remain unchanged post-treatment when a single tooth, plateau-designed, press fit implant is placed closer than the recommended distance away from the natural tooth or to another implant.

TABLE OF CONTENTS

Acknowledgements	i
Dedication	ii
Abstract	iii
Table of Contents	iv
List of Tables	v
List of Figures	vi
Introduction	1
Literature Review	2
Purpose	10
Null Hypothesis (H_0)	10
Alternative Hypothesis (H_1)	11
Material and Methods	12
Results	18
Discussion	21
Conclusion	25
References	26

LIST OF TABLES

Table I. Descriptive statistics of all proximal implant surfaces 20

Table II. Descriptive statistics of proximal implant surfaces closer to a natural tooth or another implant than the recommended guidelines 20

LIST OF FIGURES

Figure 1. Dental implants with locking taper abutments	15
Figure 2. Vertical and horizontal radiographic implant measurements	15
Figure 3. Measurements made between an implant and natural tooth	16
Figure 4. Measurements made between adjacent implants	16
Figure 5. Measurements made on an implant adjacent to an edentulous area	17

INTRODUCTION

From a historical perspective, osseointegrated root-form dental implants were primarily used to treat completely edentulous patients.¹ Emphasis was placed on improving function for these patients, while esthetic requirements assumed a lesser position of importance. As a result, esthetics was often compromised due to an unfavorable implant location as well as poor soft and hard tissue management. As implant dentistry evolved, partially edentulous patients began seeking replacement of individual teeth in the esthetic zone with an expectation of a natural appearance.

The transition from primarily treating completely edentulous patients who are interested in an improvement in function, to partially edentulous patients with esthetic demands, has created a number of challenges for present day prosthodontics. One of the most important of these challenges is how to control or manage crestal bone loss around an implant after the abutment has been placed. Crestal bone loss has been documented around the perimucosal portion of dental implants and can range from minimal bone loss to complete failure of the implant.^{2,3}

LITERATURE REVIEW

Crestal bone loss is frequently correlated to implant failure.⁴ Problems associated with implant failure are often related to biomechanical factors, rather than biological ones.⁴ Crestal bone loss, with an accompanying loss of the interdental papilla, has the potential to change a pleasing esthetic result in the anterior region into an esthetic failure.

Adell¹ conducted a 15 year study of osseointegrated implants and reported that a greater magnitude of bone loss occurred during the first year than in following years. However, it is important to note that bone loss was measured from the first thread of the implant and not from the top of the implant in this study.

Many theories have been proposed to explain crestal bone loss. Branemark⁵ was one of the first to document crestal bone loss. He reported that marginal crestal bone loss during the first year after abutment placement was ≥ 1.5 mm. He speculated that this change was a response to surgical trauma. He also reported that following the initial loss of crestal bone, a steady state of bone loss of 0.1 mm per year could be expected. Others have confirmed these findings and have contributed additional knowledge in this area. Quirynen⁶ found that an average of 0.93 mm of bone loss occurred during the first year, with a range of 0.4 to 1.6 mm and a mean loss of 0.1 mm per year subsequently. Cox⁷ reported crestal bone loss of ≤ 1.6 mm during the first year after implant loading. Avivi-Arber⁸ stated that after the first year, bone loss will be 0.22 mm per year.

Most root-form osseointegrated implants are placed at the level of the crest or submerged in the bone. Many surgical protocols recommend the placement of endosteal implants at or below the crest of the bone during the first stage surgery and observe bone loss following second stage surgery.⁹ A 2 stage surgical protocol is recommended to

decrease the movement of the implant and subsequent crestal bone loss.¹⁰ Berglundh¹⁰ has shown that 0.5 mm of bone loss can occur below the implant-abutment connection within 2 weeks after second stage surgery and abutment connection in dogs.² This may be attributed to surgical trauma. A period of 3 to 6 months should be allowed for osseointegration to occur before loading an implant.⁵

Implant designs that use a screw-retained abutment are the most prone to develop crestal bone loss during the first year of function.¹ This type of abutment to implant connection results in a micro gap between the abutment and implant. The presence of this micro gap has been implicated as a cause of crestal bone loss observed during this first year of function.^{11,12}

A radiographic study by Hermann¹³ noted that there was vertical crestal bone loss associated with the presence of a micro gap. He reported that the vertical bone loss from the abutment-implant connection in 2-piece implant systems averaged 2 mm.

An interesting study by Assenza¹⁴ suggests that crestal bone loss is relative to the location of the micro gap. Implants placed above the crestal bone, at the level of the crestal bone, and submerged in the bone, all lost bone to the first thread of the implant. Although crestal bone loss can be prevented by moving the micro gap away from the bone by approximately 2 mm, implants in an esthetic area zone need to be submerged to have the height to develop proper tooth contours. Implant manufactures have addressed this problem by fabricating ‘one stage’ implants which move the micro gap away from the bone; however, these implants are difficult to use in the esthetic zone.¹⁵

King¹² and Hermann¹³ evaluated the influence of the size of the micro gap on crestal bone loss. In both studies, 60 implants were placed in edentulous mandibles of 5

foxhound dogs 1 mm above the alveolar crest. The implants were subdivided into groups with micro gaps of <10 μm , 50 μm , or 100 μm . The major difference between these studies was that abutments and implants were welded together in one study and in the other non-welded. Both authors concluded that significant crestal bone loss occurs in 2-piece non-welded implants, regardless of micro gap size. Others suggest that it is the micro-motion between the abutment and implant followed by bacterial colonization of the micro gap that causes the bone loss.¹⁶

Misch¹⁷ suggests the stress concentration at the crestal bone area is the cause for this bone loss. A healthy implant to bone contact will permit an adequate stress transmission and avoid a pathologic overload. The distribution of stress occurs when bone is in direct contact with the implant and the proper stress distribution is an important factor in maintaining marginal crestal bone level.^{1,18} Stress concentration at the bone-implant interface may result in early implant failure. Stress transmitted from the implant to the bone without any appreciable movement requires a close approximation of the implant into the bone. If stress transmitted to the bone is too strong, a micro-movement could develop, leading to a loss of osseointegration.¹⁹

Recently, the idea of platform switching as a mean of preventing crestal bone loss has been advocated.²⁰ Platform switching is a concept in which the abutment is narrower than the implant, creating a step in the geometry of the implant-abutment connection. Platform switching to prevent crestal bone loss supports the theory advocated by Misch¹⁷ who believes stress concentration is the cause of bone loss. It has been reported that when the abutment is narrower than the implant, less stress is transmitted to the crestal bone than with conventionally shaped abutments.²¹ These theories have not been proven to be

true and further investigation into the cause of crestal bone loss associated with a micro gap needs to be accomplished.

James²² was the first to conduct a study investigating the biological space of dental implants. He suggested that hemidesmosomes help to create a structure that can act as a biological seal around implants. Tarnow²³ also believes that the implant-abutment complex develops a biologic width similar to that of a natural tooth. On the other hand, McKinney²⁴ stated that collagenous components cannot physiologically adhere to or become embedded into the implant body as they do in the cementum of a tooth.

The biologic width described for implants is related to the sulcus depth, whereas the biologic width for natural teeth is related to the height of the combined connective tissue-epithelial attachment.²⁵ Another difference between natural dentition and implants is the number of gingival fibers observed. In a natural dentition there are about 11 fibers compared to only 2 present with implants.²⁶ These types of fibers, which are not periodontal, do not insert into the implant body below the implant-abutment as they do into the cementum of the natural teeth;²⁶ therefore, the theory that an implant develops a biological width similar to that of a tooth, resulting in crestal bone loss may be questionable.

Bone density plays an important role in dental implants as it provides mechanical stabilization during osseointegration and it allows a better distribution and transmission of stress from the implant to the bone interface.²⁷ Bone density is also an important factor to consider when selecting implant design, surgical technique, and timing for osseointegration, and loading.²⁷

Bone density is correlated to the prognosis of dental implant survival. The density of the bone relates to the amount of bone contact at the interface which can determine the predictability of the implant loading protocol.²⁸ Success rate of dental implants will vary based on the intraoral location, with those placed in the anterior region of the mandible having higher success rates than those placed in the posterior area of the maxilla. Studies have suggested that the difference may be related to the quality of bone in different anatomical areas.^{1,29-31}

In describing the surgical procedure associated with mandibular fixed detachable complete dentures, Adell¹ indicated the ideal distance between 2 implant sites was 3.5 mm, the equivalent of an implant diameter at that time. In a diagram showing the relationship between adjacent natural teeth and implant fixed partial dentures, Hobo³² recommended a minimum distance of 3 mm between 2 implants or between an implant and natural tooth.

Based on these recommendations, practitioners have commonly placed 4 mm diameter implants with a 7 mm distance between their centers, thereby preserving 3 mm of bone between the implants. In order to achieve a 7 mm distance from the center of 1 implant to the next, implant surgical positioning guides were developed.³³

Tarnow²³ evaluated 36 adjacent pairs of implants which were placed in 1 of 2 groups for a period of 3 years. Group 1 included implant pairs that were separated by more than 3 mm, while group 2 included implant pairs that were separated by less than 3 mm. He reported that the average radiographic bone loss from the edge of the implant-abutment connection was 1.5 mm. Those implants separated by more than 3 mm had crestal bone loss of 0.45 mm, while those implants separated by less than 3 mm had

crestal bone loss of 1.04 mm. As a result, Tarnow²³ recommended that implants not be placed closer than 3 mm to each other to minimize crestal bone loss.

Tarnow^{23,25} and Hermann¹³ quantified crestal bone changes that can occur after abutment connection. From their results, crestal bone changes after abutment connection during the first year of function can be summarized as follows: 1.5 mm of lateral bone loss from the edge of the abutment-implant connection and 2 mm of vertical bone loss from the abutment-implant connection. For implants placed in the esthetic zone, this crestal bone loss may result in an unfavorable soft tissue change. The risk increases when adjacent implants are placed closer together than the recommended guidelines.

Another important consideration is how the micro gap influences bone levels on teeth adjacent to implants. Esposito³⁴ radiographically evaluated marginal bone loss on tooth surfaces adjacent to an implant. With 71 implants evaluated over 3 years, the average bone loss associated with anterior teeth was 1.4 ± 1.5 mm. The authors stated that there was a strong correlation between marginal bone loss around a tooth adjacent to an implant and the horizontal distance between the implant and tooth.

Krennmair³⁵ also documented the influence of the horizontal distance between implants and teeth as it relates to proximal bone loss. In this study, the average bone loss associated with anterior teeth was 1.6 ± 1 mm when the horizontal distance between the tooth and implant in the anterior region was 1.5 ± 0.6 mm. In the posterior region, the average bone loss was only 0.4 ± 0.3 mm when the average horizontal distance between the tooth and implant was 2.8 ± 0.8 mm.

Based on the results of these studies,^{13,23,25,34,35} there is a higher risk of crestal and proximal bone loss around the implant and natural tooth the closer the implant is placed

to the tooth. This is the basis for guidelines that have been developed for implant placement. Saadoun³⁶ recommends that there should be 1.5 to 2 mm of lateral space between an implant and a tooth and 3 to 3.5 mm of lateral space between implants. If the teeth to be replaced are the 2 central incisors, the distance between the two implants should be greater, 4 to 4.5 mm. It was also suggested to use smaller diameter implants or fewer implants in the esthetic zone when the spacing is not available. The rationale for this suggestion is that when the bone is thin there will be a tendency for bone resorption to occur until it reaches a point of adequate thickness, which will be more apical. The authors explain that it is important to respect the biological space in order to obtain moldable interproximal soft tissues and the formation of acceptable papillae. Maintenance of crestal and marginal bone around implants and teeth is necessary if interdental papillae are to retain proper form and contour.

Gestaldo³⁷ studied the effect of the vertical and horizontal distances between implants and between implants and teeth on the presence of the interdental papilla. This study evaluated the interproximal area both mesial-distally and apical-coronally in relation to 176 inter-proximal surfaces and found that when the vertical distance between the contact point and the bone crest was 3 to 5 mm, and the horizontal distance was 3, 3.5, or 4 mm, the papilla was present in each instance. When the horizontal distance was less than 3 mm, the papilla was absent regardless of the vertical distance between the contact point and the bone crest. Crestal bone loss around an implant most notably affects the esthetics due to the loss of the interdental papilla and creates problems in developing a proper emergence profile for the restoration.³⁸

Hatley³⁹ investigated the effects of implant proximity on inter-implant bone height in rabbits by separating the implants by 1, 1.5, and 3 mm. The implants remained uncovered and a second stage surgery was not completed, thereby avoiding a micro gap. Since there was no bone loss, the study questioned the vascularity theory for crestal bone loss which hypothesized that the proximity of the implants could limit the amount of inter implant bone and compromise the inter-osseous tissue vascularity.

An implant system (Bicon; Bicon Inc, Boston, Mass) is available that incorporates a bacterially-sealed, 3 degree locking taper, implant to abutment connection, rather than a screw connection with a micro gap (Fig. 1). The high frictional force created by the locking taper breaks down the titanium oxide layers and the metals are fused together in a cold weld, resulting in the absence of a micro gap between the implant and the abutment.⁴⁰ This system also has a sloping shoulder, which allows for more bone at the crest compared to a straight or flared implant.

PURPOSE

The purpose of this study was to retrospectively evaluate pre-treatment and post-treatment proximal bone levels of a single tooth, plateau-designed, press fit implants (Bicon®) utilizing a locking tapered, implant to abutment connection adjacent to a natural teeth and to a plateau design Bicon® implants. The bone levels were evaluated separately for those implants that were closer to a natural tooth or another implant than the recommended guidelines. Bone levels were also measured on mesial and distal surfaces of all implants as well as the crestal bone levels between 2 implants. The relationship between implant spacing and crestal bone levels will be determined.

HYPOTHESIS

Null Hypothesis (H_0)

There will be no significant difference in pre-treatment and post-treatment proximal bone levels of a single tooth, plateau-designed, press fit implants (Bicon®) utilizing a locking tapered, implant to abutment connection adjacent to a natural teeth and to a plateau design Bicon® implants, regardless of whether the implant is placed closer or not than the recommended distance away from the natural tooth or to another implant (Bicon®).

Alternative Hypothesis (H₁)

There will be a significant difference in pre-treatment and post-treatment proximal bone levels of a single tooth, plateau-designed, press fit implants (Bicon®) utilizing a locking tapered, implant to abutment connection adjacent to a natural teeth and to a plateau design Bicon® implants, regardless of whether the implant is placed closer or not than the recommended distance away from the natural tooth or to another implant (Bicon®).

MATERIAL AND METHODS

A retrospective cohort study was designed to evaluate pre-treatment and post-treatment proximal bone levels of a single tooth, plateau-designed, press fit implants (Bicon®) utilizing a locking tapered, implant to abutment connection adjacent to a natural teeth and to a plateau design Bicon® implants, as well as to measure bone levels on mesial and distal surfaces of all implants and the crestal bone levels between 2 implants. The relationship between implant spacing and bone levels was also to be evaluated. The cohort was derived from patients who received 1 or more single tooth, plateau-designed, press fit implants (Bicon; Bicon Inc) (Fig. 1) placed and restored by clinicians at the Implant Dentistry Centre in Boston between 1995 and 2005.

One hundred and sixty-nine implants with 338 proximal surfaces were included in this study. Of the 338 proximal surfaces, 120 were adjacent to a natural tooth, 192 were adjacent to an implant, and the remaining 26 surfaces were adjacent to an edentulous area. The mean follow-up time was 4 ± 2.3 years. Radiographs with gross distortion, poor contrast, and displaying poor definition of the implant and bone levels were eliminated from the study.

A chart review was conducted to obtain digital periapical radiographs which could be analyzed to measure bone levels on implants and natural teeth. All radiographs were made using the paralleling technique. The following information was gathered by chart review and recorded in a spreadsheet (Excel, Microsoft Office 2003; Microsoft Corp, Redmond, Wash):

- Implant supported crown tooth number
- Structure adjacent to mesial and distal surface of implant (tooth, implant, nothing)

- Implant diameter and length
- Implant staging (immediate or delayed placement)
- Date of implant placement
- Date of pre-treatment and post-treatment radiographs

Bone levels and changes in bone levels over time were determined by direct measurement of non-standardized digital periapical radiographs. All measurements were made by using a software measuring tool (DIGORA; Soredex, Tuusula, Finland) at $\times 3.0$ magnification. Measurements were recorded to the nearest 0.1 mm.

Vertical distortion in the radiograph was determined by measuring the length of the implant on the radiograph and subtracting the actual length. This resulted in a positive or negative number which was divided by the actual length of the implant and multiplied by 100 to establish the percent of vertical distortion. All vertical measurements were adjusted for each individual film by first calculating the percent vertical distortion that was present in the film (Fig. 2).

The same method was used to determine the horizontal distortion. The width of the implant was measured on the radiograph and then the actual width was subtracted resulting in a positive or negative number. This number was divided by the actual width of the implant and multiplied by 100 to establish the percent horizontal distortion for each film. All horizontal measurements were converted using the percent horizontal distortion established for each film (Fig. 2).

Measurements were made of the following areas of interest:

- A. Horizontal distance between the implant and a natural tooth or another implant
(Figs. 3 and 4)
- B. Bone level on the implant surface (Figs. 3, 4, and 5)
- C. Proximal bone levels on a natural tooth from the cemento-enamel junction (CEJ)
to the crest of bone (Fig. 3)
- D. Crestal bone level between 2 implants (Fig.4)

Student T-tests were used to evaluate the statistical significance between pre-treatment and post-treatment proximal bone levels of implants adjacent to a natural teeth and to implants. Level of significance was set to alpha 0.05. Descriptive statistics were used to report bone levels on implants adjacent to a natural tooth, another implant, or an edentulous area, as well as the crestal bone levels between 2 implants.



Figure 1. Dental implants with locking taper abutments.

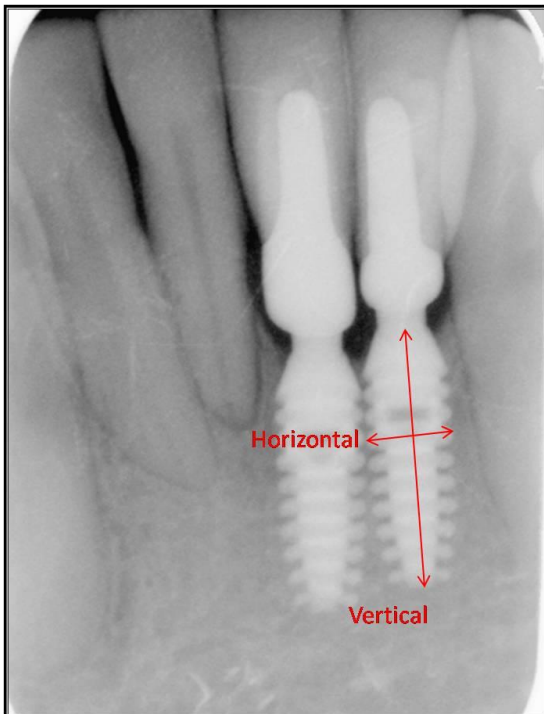


Figure 2. Vertical and horizontal radiographic implant measurements.

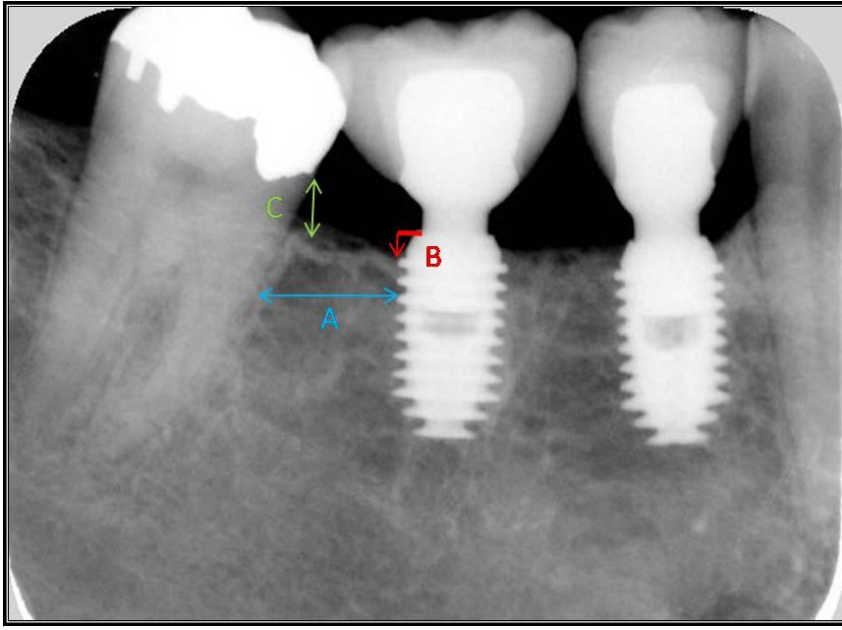


Figure 3. Measurements made between an implant and natural tooth.

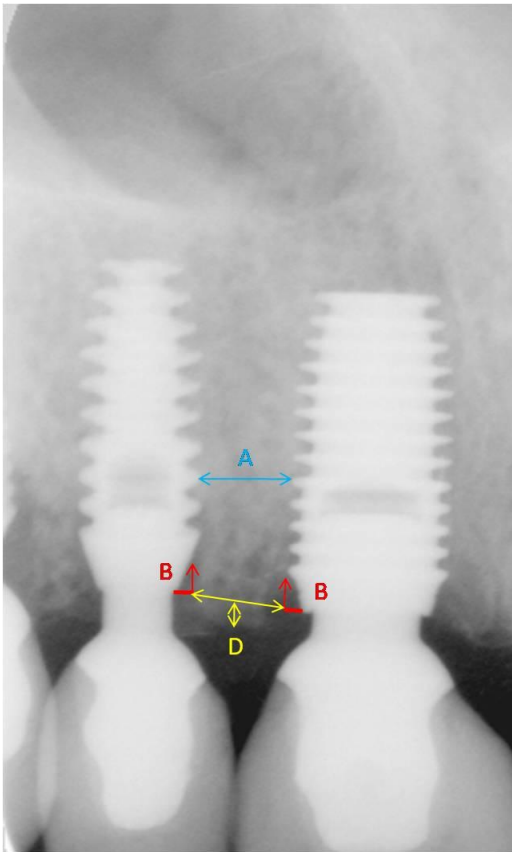


Figure 4. Measurements made between adjacent implants.

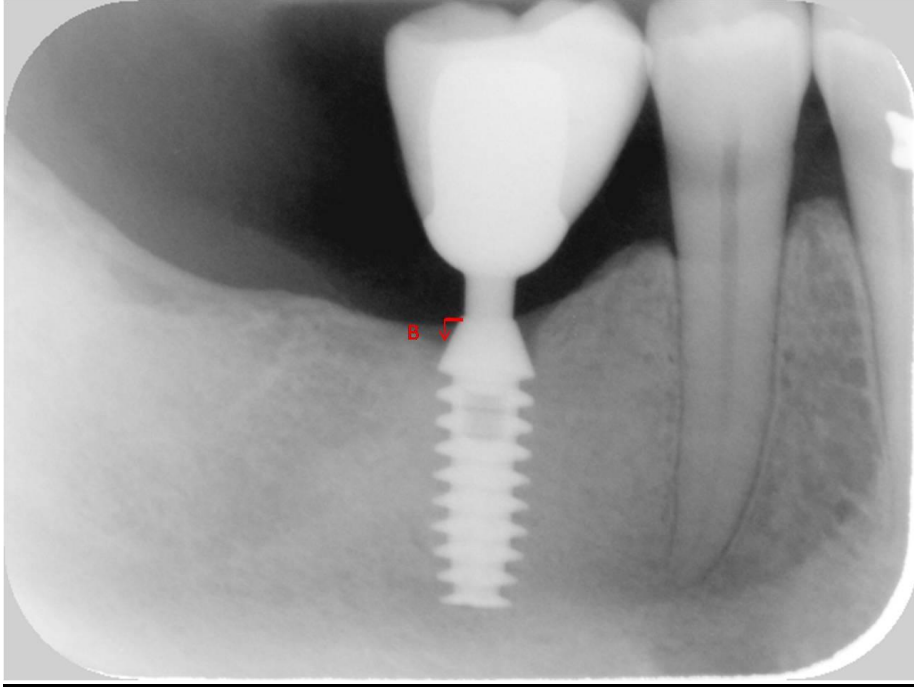


Figure 5. Measurements made on an implant adjacent to an edentulous area.

RESULTS

Table I summarizes the results for all implant surfaces. The average distance between an implant surface and a natural tooth was 2.6 ± 1.7 mm. Bone levels on the implant were located 0.4 ± 0.4 mm from the top of the implant down on the sloping shoulder. The location of the proximal bone on the tooth surface from the CEJ was 2.1 ± 1.4 mm pre-treatment and 2.2 ± 1.6 mm post-treatment. There was no significant difference ($P=0.25$) between pre-treatment proximal bone levels and post-treatment proximal bone levels on natural teeth adjacent to single tooth, plateau-designed, press fit implants.

The distance between implant surfaces adjacent to each other was 2.4 ± 1.4 mm. The bone level on the sloping shoulder was 0.6 ± 0.6 mm from the top of the implant. Crestal bone levels between adjacent implants were 0.8 ± 1.4 mm above a line connecting the top of adjacent implant surfaces.

Twenty six implant surfaces were adjacent to an edentulous area. The bone level on the sloping shoulder of these implant surfaces was 0.6 ± 0.6 mm from the top of the implant.

Table II summarizes the results for those implant surfaces which are closer than the recommended guidelines of 2 mm to a natural tooth or 3 mm to another implant. The average distance between 52 implant surfaces and a natural tooth was 1.0 ± 0.5 mm. The bone level on the sloping shoulder was 0.4 ± 0.8 mm from the top of the implant. Pre-treatment proximal bone levels on the natural tooth from the CEJ were 2.4 ± 1.4 mm while post-treatment proximal bone levels were 2.7 ± 1.4 mm. There was no significant difference ($P=0.25$) between pre-treatment proximal bone levels and post-treatment

proximal bone levels on natural teeth adjacent to single tooth, plateau-designed, press fit implants when the implant was placed closer than the recommended distance away from the natural tooth.

The 122 implant surfaces that were adjacent to each other were separated by 1.5 ± 0.8 mm. The bone levels on the sloping shoulder were 0.8 ± 0.8 mm from the top of the implant. Crestal bone levels were 0.8 ± 1.0 mm above a line connecting the top of adjacent implants.

Table I. Descriptive statistics of all proximal implant surfaces

Implant Surfaces	Adjacent to Natural Tooth	Adjacent to Implant	Adjacent to Edentulous Area
Number of Surfaces	120	192	26
A – Average Distance (mm)	2.6 ± 1.7	2.4 ± 1.4	
B – Bone Level (mm)	0.4 ± 0.4	0.6 ± 0.6	0.6 ± 0.6
C – Proximal Bone Pre-Treatment (mm)	2.1 ± 1.4		
C – Proximal Bone Post-Treatment (mm)	2.2 ± 1.6		
D – Crestal Bone Levels Above Line (mm)		0.8 ± 1.4	

Table II. Descriptive statistics of proximal implant surfaces closer to a natural tooth or another implant than the recommended guidelines

Implant Surfaces	Adjacent to Natural Tooth	Adjacent to Implant
Number of Surfaces	52	122
A – Average Distance (mm)	1.0 ± 0.5	1.5 ± 0.8
B – Bone Level (mm)	0.4 ± 0.8	0.8 ± 0.8
C – Proximal Bone Pre-Treatment (mm)	2.4 ± 1.4	
C – Proximal Bone Post-Treatment (mm)	2.7 ± 1.4	
D – Crestal Bone Levels Above Line (mm)		0.8 ± 1.0

DISCUSSION

Of the 338 radiographically measured proximal implant surfaces that were included in this study, 174 surfaces were closer to a natural tooth or another implant than the recommended guidelines.^{1,23,33}

The data support the acceptance of the null hypothesis as there was no significant difference in pre-treatment and post-treatment proximal bone levels of a single tooth, plateau-designed, press fit implants (Bicon®) utilizing a locking tapered, implant to abutment connection adjacent to a natural teeth and to a plateau design Bicon® implants, regardless of whether the implant is placed closer or not than the recommended distance away from the natural tooth or to another implant (Bicon®).

The results in this study compared to those on Krennmair,³⁵ Tarnow,²³ and Esposito,³⁴ are more favorable when an implant is placed closer to a natural tooth or to an adjacent implant.

In this study, 52 implant surfaces were a distance of 1.0 ± 0.5 mm from the natural dentition. The bone level pre-treatment was 2.4 ± 1.4 mm and post-treatment was 2.7 ± 1.4 mm. On Krennmair's³⁵ study, the average bone loss associated with anterior teeth was 1.6 ± 1 mm when the horizontal distance between the tooth and implant in the anterior region was 1.5 ± 0.6 mm. In the posterior region, the average bone loss was only 0.4 ± 0.3 mm when the average horizontal distance between the tooth and implant was 2.8 ± 0.8 mm. He concluded that there was a significant influence of the horizontal distances on proximal bone loss when an implant was placed in a closer distance to a natural dentition. In his study implant survival rate, peri-implant structures, and prosthetic complication rates were evaluated. Crowns and periodontal status of adjacent

teeth were compared at crown placement and at the last examination. Only the horizontal distance from the implant edge to adjacent teeth was calculated and compare for anterior and posterior regions, bone loss was determined by observing the radiographs.

Esposito³⁴ evaluated marginal bone loss at natural tooth surfaces facing a Branemark implant. The average bone loss associated with anterior teeth was 1.4 ± 1.5 mm. One of the factors considered in this study was the horizontal distance between an implant and an adjacent natural tooth. It was concluded that there is a strong correlation between marginal bone loss around a tooth adjacent to an implant and the horizontal distance between the implant and adjacent natural tooth. With decreased distance the bone loss increased. In his study the following factors were considered: age, cause of tooth loss, vertical relation between fixture and teeth, distance between adjacent teeth, distance between fixture and natural tooth, jaw region. Measurements were similar to those in our study.

The results obtained in our study suggest that this implant system may be placed closer to a natural tooth with no change in pre-treatment and post-treatment proximal bone levels.^{1,5,41}

In this study one hundred twenty two implant surfaces were in a distance of 1.5 ± 0.8 mm from another implant. Crestal bone levels were 0.8 ± 1 mm above the line that connects both implants. These distances between adjacent implants or an implant and a natural tooth were closer than published recommendations. Tarnow²³ reported in his study that the average radiographic bone loss from the edge of the implant-abutment connection was 1.5 mm. Those implants separated by more than 3 mm had crestal bone loss of 0.45 mm, while those implants separated by less than 3 mm had crestal bone loss

of 1.04 mm. He concluded that there is a lateral component to the bone loss around implants in addition to the more commonly discussed vertical component. When implants are not spaced more than 3 mm, the lateral component of bone loss can result in greater inter-implant crestal bone loss. One of the differences between his study and ours is that crestal bone loss was measured from the crest of the bone to the top of the implant, and the rationale of this is that he was evaluating the effect of inter-implant distance on the height of inter-implant bone crest.

The distances between implant-tooth and implant-implant in our study are less than those recommended by Saadoun.³⁶

Implant design has been found to be an important factor in maintaining marginal bone levels against functional loading. The implant system evaluated in this study differs from others in regards to the abutment-implant connection. The abutment connects to the implant by means of a 3 degree locking taper, creating a cold solder joint and a bacterial seal.^{40,42} The unique architecture with a sloping shoulder follows the concept of platform switching, advocated by Lazzara.²⁰ He concluded that in a of 13 year observation period, no greater bone loss was observed when compared to conventional two-piece implants. This design supports the theory of Misch¹⁷ who believes that stress concentration to be the cause of bone loss. This explains why the results of this study showed no change in proximal bone levels pre-treatment and post-treatment when implants were placed adjacent to a natural tooth, if the abutment is narrower than the implant, less stress is transmitted to the crestal bone when compared to conventionally shaped abutments.²¹

Crestal bone loss has been attributed to several factors or a combination of factors including surgical trauma,⁴³ colonization of pathologic bacteria in the implant sulcus,^{44,45}

position of the implant's rough-smooth border,⁴⁶ stress concentration at the crestal bone,^{47,48} biologic width,⁴⁹ and the size and location of the microgap.^{11,15} Also, by increasing the implant surface area contacting the bone, stress concentration at the crestal bone can be decreased by either increasing the implant length or diameter, modifying the surface treatment or design, or by placing the implant in higher quality bone.^{27,50}

Some of the limitations of this study included the follow-up time of 4 ± 2.3 years and a sample size of 169 implants, both of which could be increased in order to detect a statistically significant difference. There was also potential for investigator error in the measurement of the radiographs as well as potential for distortion of the radiographic image. Other limitations included the retrospective design of the study, lack of clinician calibration, and the evaluation of a single implant system. Future studies need to evaluate pre-treatment and post-treatment proximal bone levels prospectively with different implant designs.

CONCLUSION

This retrospective cohort study was designed to evaluate pre-treatment and post-treatment proximal bone levels of a single tooth, plateau-designed, press fit implants (Bicon®) utilizing a locking tapered, implant to abutment connection adjacent to a natural teeth and to a plateau design Bicon® implants, as well as to measure bone levels on mesial and distal surfaces of all implants and the crestal bone levels between 2 implants. The cohort was derived from patients who received 1 or more single tooth, plateau-designed, press fit implants at a private practice between 1995 and 2005. Proximal bone levels can be expected to remain unchanged post-treatment when a single tooth, plateau-designed, press fit implant is placed closer than the recommended distance away from the natural tooth or to another implant.

REFERENCES

1. Adell R, Lekholm U, Rockler B, Branemark PI. A 15-year study of osseointegrated implants in the treatment of the edentulous jaw. *Int J Oral Surg* 1981;10:387-416.
2. Linkow LI. Statistical analyses of 173 implant patients. *Oral Implantol* 1974;4:540-62.
3. Tonetti MS. Advances in periodontology. *Prim Dent Care* 2000;7:14952.
4. Goodacre CJ, Bernal G, Rungcharassaeng K, Kan JY. Clinical complications with implants and implant prostheses. *J Prosthet Dent* 2003;90:121-32.
5. Branemark PI, Hansson BO, Adell R, Breine U, Lindstrom J, Hallen O, et al. Osseointegrated implants in the treatment of the edentulous jaw. Experience from a 10-year period. *Scand J Plast Reconstr Surg Suppl* 1977;16:1-132.
6. Quirynen M, Naert I, van Steenberghe D. Fixture design and overload influence marginal bone loss and fixture success in the Branemark system. *Clin Oral Implants Res* 1992;3:104-11.
7. Cox JF, Zarb GA. The longitudinal clinical efficacy of osseointegrated dental implants: a 3-year report. *Int J Oral Maxillofac Implants* 1987;2:91-100.
8. Avivi-Arber L, Zarb GA. Clinical effectiveness of implant-supported single-tooth replacement: the Toronto Study. *Int J Oral Maxillofac Implants* 1996;11:311-21.
9. Shin YK, Han CH, Heo SJ, Kim S, Chun HJ. Radiographic evaluation of marginal bone level around implants with different neck designs after 1 year. *Int J Oral Maxillofac Implants* 2006;21:789-94.
10. Berglundh T, Lindhe J, Ericsson I, Marinello CP, Liljenberg B, Thomsen P. The soft tissue barrier at implants and teeth. *Clin Oral Implants Res* 1991;2:81-90.

11. Hermann JS, Schoolfield JD, Schenk RK, Buser D, Cochran DL. Influence of the size of the microgap on crestal bone changes around titanium implants. A histometric evaluation of unloaded non-submerged implants in the canine mandible. *J Periodontol* 2001;72:1372-83.
12. King GN, Hermann JS, Schoolfield JD, Buser D, Cochran DL. Influence of the size of the microgap on crestal bone levels in non-submerged dental implants: a radiographic study in the canine mandible. *J Periodontol* 2002;73:1111-7.
13. Hermann JS, Cochran DL, Nummikoski PV, Buser D. Crestal bone changes around titanium implants. A radiographic evaluation of unloaded nonsubmerged and submerged implants in the canine mandible. *J Periodontol* 1997;68:1117-30.
14. Assenza B, Scarano A, Petrone G, Iezzi G, Thams U, San Roman F, et al. Crestal bone remodeling in loaded and unloaded implants and the microgap: a histologic study. *Implant Dent* 2003;12:235-41.
15. Piattelli A, Vrespa G, Petrone G, Iezzi G, Annibali S, Scarano A. Role of the microgap between implant and abutment: a retrospective histologic evaluation in monkeys. *J Periodontol* 2003;74:346-52.
16. Callan DP, O'Mahony A, Cobb CM. Loss of crestal bone around dental implants: a retrospective study. *Implant Dent* 1998;7:258-66.
17. Misch CE, Suzuki JB, Misch-Dietsh FM, Bidez MW. A positive correlation between occlusal trauma and peri-implant bone loss: literature support. *Implant Dent* 2005;14:108-16.
18. Branemark PI. Osseointegration and its experimental background. *J Prosthet Dent* 1983;50:399-410.

19. Skalak R. Biomechanical considerations in osseointegrated prostheses. *J Prosthet Dent* 1983;49:843-8.
20. Lazzara RJ, Porter SS. Platform switching: a new concept in implant dentistry for controlling postrestorative crestal bone levels. *Int J Periodontics Restorative Dent* 2006;26:9-17.
21. Bozkaya D, Muftu S, Muftu A. Evaluation of load transfer characteristics of five different implants in compact bone at different load levels by finite elements analysis. *J Prosthet Dent* 2004;92:523-30.
22. James RA, Kelln EE. A histopathological report on the nature of the epithelium and underlying connective tissue which surrounds oral implants. *J Biomed Mater Res* 1974;8:373-83.
23. Tarnow DP, Cho SC, Wallace SS. The effect of inter-implant distance on the height of inter-implant bone crest. *J Periodontol* 2000;71:546-9.
24. McKinney R, Steflik DE, Koth DL. Evidence for a junctional epithelial attachment to ceramic dental implants. A transmission electron microscopic study. *J Periodontol* 1985;56:579-91.
25. Tarnow DP, Eskow RN. Considerations for single-unit esthetic implant restorations. *Compend Contin Educ Dent* 1995;16:778-88.
26. Vacek JS, Gher ME, Assad DA, Richardson AC, Giambarresi LI. The dimensions of the human dentogingival junction. *Int J Periodontics Restorative Dent* 1994;14:154-65.
27. Misch CE. Density of bone: effect on treatment plans, surgical approach, healing, and progressive bone loading. *Int J Oral Implantol* 1990;6:23-31.

28. Degidi M, Scarano A, Iezzi G, Piattelli A. Histologic analysis of an immediately loaded implant retrieved after 2 months. *J Oral Implantol* 2005;31:247-54.
29. Jaffin RA, Berman CL. The excessive loss of Branemark fixtures in type IV bone: a 5-year analysis. *J Periodontol* 1991;62:2-4.
30. Becker W, Becker BE, Alsuwyed A, Al-Mubarak S. Long-term evaluation of 282 implants in maxillary and mandibular molar positions: a prospective study. *J Periodontol* 1999;70:896-901.
31. Davies JE. Understanding peri-implant endosseous healing. *J Dent Educ* 2003;67:932-49.
32. Hobo S, Ichida I, Garcia LT. *Osseointegration and occlusal rehabilitation*. 1st ed. Chicago: Quintessence Pub; 1999:78-121.
33. Palacci P, Ericsson I, Engstrand P, Ranger B. *Optimal implant positioning and soft tissue management for the Branemark system*. 1st ed. Chicago: Quintessence Pub; 1995:4-58.
34. Esposito M, Ekstubbbe A, Grondahl K. Radiological evaluation of marginal bone loss at tooth surfaces facing single Branemark implants. *Clin Oral Implants Res* 1993;4:151-7.
35. Krennmair G, Piehslinger E, Wagner H. Status of teeth adjacent to single-tooth implants. *Int J Prosthodont* 2003;16:524-8.
36. Saadoun AP, Le Gall MG, Touati B. Current trends in implantology: part II-- treatment planning, aesthetic considerations, and tissue regeneration. *Pract Proced Aesthet Dent* 2004;16:707-16.

37. Gastaldo JF, Cury PR, Sendyk WR. Effect of the vertical and horizontal distances between adjacent implants and between a tooth and an implant on the incidence of interproximal papilla. *J Periodontol* 2004;75:1242-6.
38. Misch CE, Qu Z, Bidez MW. Mechanical properties of trabecular bone in the human mandible: implications for dental implant treatment planning and surgical placement. *J Oral Maxillofac Surg* 1999;57:700-8.
39. Hatley CL, Cameron SM, Cuenin MF, Parker MH, Thompson SH, Harvey SB. The effect of dental implant spacing on peri-implant bone using the rabbit (*Oryctolagus cuniculus*) tibia model. *J Prosthodont* 2001;10:154-9.
40. Dibart S, Warbington M, Su MF, Skobe Z. In vitro evaluation of the implant-abutment bacterial seal: the locking taper system. *Int J Oral Maxillofac Implants* 2005;20:732-7.
41. Albrektsson T, Zarb G, Worthington P, Eriksson AR. The long-term efficacy of currently used dental implants: a review and proposed criteria of success. *Int J Oral Maxillofac Implants* 1986;1:11-25.
42. Muftu A, Mulcahay HL, Chapman R. Comparison of *Streptococcus Sanguis* penetration through various implant abutment connection mechanisms. *J Dent Res* 1997;76 Special Issue:1813.
43. Gomez-Roman G. Influence of flap design on peri-implant interproximal crestal bone loss around single-tooth implants. *Int J Oral Maxillofac Implants* 2001;16:61-7.
44. Mombelli A, van Oosten MA, Schurch E, Jr, Land NP. The microbiota associated with successful or failing osseointegrated titanium implants. *Oral Microbiol Immunol* 1987;2:145-51.

45. Lee KH, Maiden MF, Tanner AC, Weber HP. Microbiota of successful osseointegrated dental implants. *J Periodontol* 1999;70:131-8.
46. Hammerle CH, Bragger U, Burgin W, Lang NP. The effect of subcrestal placement of the polished surface of ITI implants on marginal soft and hard tissues. *Clin Oral Implants Res* 1996;7:111-9.
47. Mihalko WM, May TC, Kay JF, Krause WR. Finite element analysis of interface geometry effects on the crestal bone surrounding a dental implant. *Implant Dent* 1992;1:212-7.
48. O'Mahony A, Bowles Q, Woolsey G, Robinson SJ, Spencer P. Stress distribution in the single-unit osseointegrated dental implant: finite element analyses of axial and off-axial loading. *Implant Dent* 2000;9:207-18.
49. Cochran DL, Hermann JS, Schenk RK, Higginbottom FL, Buser D. Biologic width around titanium implants. A histometric analysis of the implanto-gingival junction around unloaded and loaded nonsubmerged implants in the canine mandible. *J Periodontol* 1997;68:186-98.
50. Misch CE. Consideration of biomechanical stress in treatment with dental implants. *Dent Today* 2006;25:80-5.