

ASDH
176.

MEDICAL BULLETIN

UNIVERSITY OF *Minnesota*



in this issue

- THE CLASS OF 1943 (MARCH)
- MANIFESTATIONS OF LEUKEMIA
- PSYCHOMOTOR EPILEPSY
- RENAL DISEASE EVALUATION

VOLUME XXXV, NUMBER 6

FEBRUARY 1964

W. ALBERT SULLIVAN, JR., M.D.
Editor

EIVIND HOFF, JR.
Managing Editor

GERARD W. FRAWLEY
WESLEY W. SPINK, M.D.

ADMINISTRATIVE SPONSORS

University of Minnesota Hospitals
RAY M. AMBERG, *Director*

Minnesota Medical Foundation
CORRIN H. HODGSON, M.D., *President*
VERNON D. E. SMITH, M.D., *Vice-President*
N. L. GAULT, JR., M.D., *Secretary-Treasurer*
EIVIND HOFF, JR., *Executive Director*

University of Minnesota Medical School
O. MEREDITH WILSON, *President*
University of Minnesota
ROBERT B. HOWARD, M.D., *Dean*
College of Medical Sciences
H. MEAD CAVERT, M.D., *Assistant Dean*
N. L. GAULT, JR., M.D., *Assistant Dean*

Minnesota Medical Alumni Association
NEIL M. PALM, M.D., *President*
JAMES C. MANKEY, M.D., *Vice-President*
ROBERT H. MONAHAN, M.D., *Vice-President*
DUANE C. OLSON, M.D., *Secretary*
L. G. IDSTROM, M.D., *Treasurer*

UNIVERSITY OF MINNESOTA
Medical Bulletin

Official Publication of
UNIVERSITY OF MINNESOTA HOSPITALS
MINNESOTA MEDICAL FOUNDATION
MINNESOTA MEDICAL ALUMNI ASSOCIATION
Circulation this issue 6,500

VOLUME XXXV

February 1964

NUMBER 6

C O N T E N T S

SURVEY ARTICLE

The Class of March, 1943 210

STAFF MEETING REPORTS

*The Gastrointestinal and Anorectal
Manifestations of Leukemia*

DAVID L. SIEGAL, M.D., and
WILLIAM C. BERNSTEIN, M.D. 230

*Psychological Correlates of Unilateral Temporal
Lobectomy in Psychomotor Epileptics*

MANFRED J. MEIER, Ph.D., and
LYLE A. FRENCH, M.D., Ph.D. 233

*Use of Radioisotopic Techniques for the
Evaluation of Renal Disease*

MERLE K. LOKEN, Ph.D., M.D.,
ROBERT E. STEJSKAL, M.D., and KURT AMPLATZ, M.D. . . 236

MEDICAL FOUNDATION NEWS 240

ALUMNI DEATHS 244

Published monthly from September through June at Minneapolis, Minn. No advertising accepted. Second class postage paid. Address all correspondence to The Editor, University of Minnesota Medical Bulletin, 1342 Mayo Bldg., University of Minnesota, Minneapolis, Minn. 55455.



Alumni Survey



CLASS OF 1943 (MARCH)

Answering wartime needs, the University of Minnesota Medical School graduated a total of 222 doctors in 1943. In only one other year (1946) has the 75-year-old Medical School produced as many graduates.

Two entire classes completed their training in 1943—six months apart—under the “accelerated curriculum” of World War II. One group finished in March, the other in December. (The latter group will be surveyed in the next issue.)

The Class of March, 1943 was received almost en masse by the Armed Forces after only nine-month internships. Many of its members had worked their way full time through college and Medical School as waiters, bus drivers, and clerks. One was a professional wrestler. And all won their MB degrees by passing the dreaded “comprehensive examinations” which once taxed the stamina and knowledge of all medical students at Minnesota. As senior medical students, they enjoyed a certain prestige which was to vanish when research and specialized training became part of medical school in postwar years.

Several men distinguished themselves in the thickest fighting of World War II. Fate called on one to help save the life of Japanese Premier Tojo during a suicide attempt in 1946. (Tojo died later on the gallows as a convicted war criminal.)

Nine members of the 111-member class are known to be deceased. Another, Robert Hanson, could not be located. One hundred and one others were traced:

David M. Anderson has been a urologist at the St. Louis Park (Minn.) Medical Center for the last 13 years. He trained at Minneapolis V.A. Hospital, and is now on the attending staff there. He is also a clinical assistant professor at the Medical School. David served in the Army in Europe from 1944-46. His wife is Bernyce G. Lawrence of Minneapolis. They live at 5425 Mt. Normandale Curve, Bloomington 31, Minn., with their children, Karen, 19; David, 17; Bruce, 15; Kristin, 13; Kathryn, 12; and Blair, 8.

Harold C. Anderson is medical director of the Gaylord Hospital, Wallingford, Conn. He trained in internal medicine at the New Haven Hospital, spent three years at the Rockefeller Institute in New York, and then served two years as medical director of Irvington House, Irvington-on-Hudson, New York. He also spent a year at Cambridge University in England on a Fulbright grant doing immunology, and served two years in the Navy 1953-55. Single, he has been at Wallingford since 1958.

Richard W. (Dick) Anderson is full time professor of psychiatry at the University of Minnesota Medical School, but is now on a year's sabbatical leave to study community psychiatry in England. He has been at Minnesota ten years and has spent 19 years in the field of psychiatry, including 1943-46 service in the Army. He lives at 1318 W. 47th St., Minneapolis, with his wife, Bette Ann, and Peter, 19; John, 15; and Eric, 8.

William T. Anderson has found general practice "very gratifying" for 20 years, and has spent 11 years in the same location. He lives at 5116 10th Ave. S., Minneapolis, with his wife, Frances, who was a nurse at Deaconess Hospital. They have two sons and two daughters, and share the enjoyment of family fishing, hunting, traveling, and camping.

Amelia Bauer Kahn is a housewife, mother of three boys, and part time in the private practice of psychiatry in Franklin, N.C. Her husband is Dr. Joseph W. Kahn, a general practitioner in that city. The family home is at 106 Harrison Ave. Amelia was director of the first community mental health center in western North Carolina.

Sidney F. Becker has been an ophthalmologist for 12 years, and now practices in Sioux Falls, S.D. He served in the Navy 1943-46. He and his wife, Marjorie, live at 1215 S. 5th, and have five children ranging in age from 21 to 3 years old.

W. J. Berger is deceased.



JACK C. BOOREN



JAMES T. BRENNAN

Paul Blake lives at 4640 Caribou Dr., Hopkins, Minn., and is a neurosurgeon. He teaches at the University of Minnesota Medical School, where he received his surgery training from 1946 through 1951. Paul is married to the former Patricia Breher of Wadena, Minn. Their children are David, 14; Barbara, 13; William, 10; Mary, 8; and Joseph, 2.

Benjamin Bofenkamp is an ENT specialist in Minneapolis in association with Graham Smith (Med. '38) and John Glaeser (Med. '45). He began his current practice in 1950, and also teaches at the Medical School. Ben is vice president of the Minneapolis Chamber of Commerce, and comments: "I plan to continue practice in this wonderful city of seasons." His family consists of his wife, Kathleen, and James, 12; Nan, 11; and Joseph, 8. They all enjoy outdoor sports and live at 4404 Sunny-side Rd., Minneapolis 24.

Jack C. Booren practices internal medicine and lives in Denver, Colo. He served in the army 1944-46, and has been in Denver for 12 years. At home at 3093 S. Cook St. are his wife, Helen, and Jeffrey, 19; Libbie, 15; Mark, 13; and John, 11.

Col. James T. Brennan is a career medical officer with the U.S. Army. He is presently director of the Armed Forces Radiobiology Research Institute at Bethesda, Md., and a clinical professor at George Washington University School of Medicine. Following Medical School, Jim was involved in military operations following the invasion of Europe. He fought in the famous Battle of the Bulge in December, 1944 with airborne units. After the war he was engaged in radiation hazard control for the Army during the atomic tests in the Pacific ocean, and later took a three year residency in radiology at Walter Reed Hospital. He is the author of ten papers in the radiologic field. With his wife, Audrey, he lives at 10204 Tyburn Terr., Bethesda, Md. They have a daughter, Martha, 17; and a son, James, Jr., 12.

Wayne Chadbourn is a pathologist at St. Barnabas Hospital, Minneapolis, and lives with his wife, Erma, and Paul, 13; Ned, 11; and Mary Ann, 6, at 4512 W. Woodland Rd., Minneapolis. "All of us are active in church work," he writes, "and we recently moved into a new home." Wayne spent three years in general practice at Litchfield, Minn., before taking a pathology residency at Minneapolis V.A. Hospital. He served with the Navy in the Pacific 1943-47.

William S. Chalgren is a neuropsychiatrist in Mankato, Minn. in association with Dr. J. Benjamin Lund (Med. '42). He is a clinical assistant professor at the Medical School, where he earned a Ph.D. in neuropsychiatry in 1949. He has been in Mankato since 1950. The family home is at 107 Birchwood. His wife is the former Marcia McLaughlin. Their sons are Richard, 17; Robert, 15; and James, 12. "We enjoy attending the curling bonspiels in this part of the country," he writes.

Llewellyn E. Christensen is an ophthalmologist in Minneapolis. His home address is 2629 W. 43rd St.

Ellis N. Cohen is an associate professor of anesthesiology at Stanford University Medical School. He received the M.S. degree from the University of Minnesota in 1948, after serving in the Army in the South Pacific 1944-46. His wife, Sylvia, is from Chicago. They live at 816 Lathrop Dr., Stanford, Calif., with their children, Susan, 15; Karen, 13; and Mark, 7.

John P. Cooper became a urologist in 1958 after practicing general medicine for nine years in Excelsior, Minn. He now practices in Minneapolis, and lives at 18 Circle W., Minneapolis 24. John took his residency at Minneapolis General Hospital. He is married to the former Barbara Compton of Minneapolis. Their children are Stephanie, 20; John, Jr., 15; and Gretchen, 12.

George R. Davis does general practice and obstetrics-gynecology at the Westgate Center, 6404 N. Mesa, El Paso, Tex. He took an OB-GYN residency at Minnesota 1944-45 and a surgery residency at Parkland Hospital, Dallas, Tex. 1951-53. He also served twice in the U.S. Army. His wife, Helen, is a University of Minnesota graduate. Their children are Charles, 17; Beverly, 14; George, 11; and Tom, 7. The Davises have been in El Paso for ten years.

Robert Delmore is deceased.

J. William Devney earned the Bronze Star medal during Navy service in World War II, and is now a general surgeon at the Taylor-Richardson Clinic, Ellensburg, Wash. He settled there

in 1950 following a residency at the Mayo Foundation, and now lives at 209 North Alder with his wife, Catherine, and Peggy, 16; Billy, 12; Anna, 8; Kathleen, 7; and Patrick, 4.


Frank J. Dixon is engaged in fulltime research in immunopathology at the Scripps Clinic and Research Foundation, LaJolla, Calif. He was formerly in research work at Duke University Medical Center, and now lives at 2355 Avenida de La Playa, LaJolla. With him are his wife, Marian (of Canada) and Janet, 15; Frank, 13; and Michael, 10.

William C. Dodds practices ophthalmology and general medicine in Detroit Lakes, Minn.

Lloyd G. Edwards established an EENT practice in St. Paul 15 years ago. He served in the Pacific area during World War II and now lives at 2270 Dodd Rd., St. Paul 18, Minn., with his wife, Audrey. Their children are Jeff, 19; Kent and Keith, 16; Shirley, 15; John, 13; Karen, 7; and Anita, 4.

Mary Louise Eilert left her teaching career to enter private practice in 1951 in Concord, Calif. She's an internist, and also is on the clinical teaching staff at Contra Costa County Hospital. She was an instructor in Medicine at the University of Chicago 1944-47, and an assistant professor there 1948-51. Mary lives at 971 David Avenue, Concord.

Albert J. Ellinger is a pediatrician in private practice with six other physicians in the Willmar Clinic in Willmar, Minn. Before going to Willmar 12 years ago, he practiced in Wauwatosa, Wis., was an instructor in pediatrics at Marquette University in Milwaukee, and had spent four years in military service. He and his wife Lois have four children: John, 17; Nan, 14; Nathan, 13; and Kathryn, 9. The entire family is active in church and civic activities in Willmar. They live at 315 W. 12th St.



ALBERT J. ELLINGER

Tilden C. Everson is a general surgeon in private practice. He teaches at the University of Illinois College of Medicine, and lives at 43 Lakeview Lane, Barrington, Ill.

Clarence R. Ferrell is in general practice in Grand Rapids, Minn.

Arthur J. Felion has been in general practice in St. Paul, Minn. for 15 years and is associated with Dr. John Ryan. He

served in the Army during World War II, and now lives at 2211 St. Clair Ave. with his wife, Marjorie, and Barbara, 16; Michael, 14; Charles, 11; Marcia, 10; Mark, 8; Rebecca, 6; and Tim, 1.

Jack Flasher practices internal medicine in Pacific Palisades, Calif., and lives at 520 Muskingum Ave. in that city with his wife, Tobetha, and Robert, 19; Richard, 17; and Donald, 14. Jack took his internal medicine residency at the Mayo Foundation and was in military service during World War II and in 1953. He has been in California about ten years.

Orley W. Foster is a general surgeon associated with three other doctors in a Minneapolis surgical practice. He served in the Army from 1943-46, and is married to the former Nellie Jobs of Minneapolis. They live at 6609 Southcrest Drive, Minneapolis, with their children: Lucius, 17; and Pamela, 15.

William B. Frey has been a pediatrician in South Bend, Ind. for the last 15 years. He served in the Army 1944-46 and is married to the former Mary Walsh, of Milwaukee. They live at 1714 E. Bader, with their children: Bill, 12; Mimi, 11; John, 8; Susan, 4; and Betsy, 3.

Frank J. Friden took a residency at the University of Minnesota Hospitals 1946-48 and has since practiced pediatrics alone in Great Falls, Mont. "I hope to find a partner soon, and maybe put up a building," he writes. Frank married Doris J. Ryan of New Richmond, Wis. They live at 2409 Third Ave. N. and are parents of Peter, 20; Tom, 19; Kathleen, 16; Betsey, 14; and Ann, 12. Dad's hobbies are fishing, hunting, sailing, painting, and golfing. He served in the Navy 1943-46.

Howard M. Frykman has practiced coloproctology for the last 12 years in Minneapolis, teaches at the Medical School, and is head of proctology at Hennepin County General Hospital. His partner in practice is Dr. Stanley Goldberg (Med. '56). Dr. Frykman lives at 6212 S. Knoll Drive, Minneapolis 24, with his wife, Jane, and two sons, Colin and Ian.

Robert Gallagher is deceased.

Lloyd I. Gillin is a radiologist in San Francisco, Calif.

John M. Gosslee is an orthopedic surgeon at the Highland Clinic, Shreveport, La., and lives at 4818 Crescent Dr. in that city. He teaches at L.S.U. Medical School and is married to the former Eileen Kleinman of Minneapolis. Their children are Mike, 18; Jim, 14; and Robbie, 9.



JOHN S. GILSON, M.D.
BETTY ST. CYR GILSON, M.D.

John S. Gilson married a classmate, **Betty St. Cyr**, and they now live and practice in Great Falls, Mont. Their home is at 3 Prospect Way. John is an internist and cardiologist at the Great Falls Clinic, having trained at Western Reserve 1943-47. "I currently have a new three-year grant from N.I.H. for further studies in continuous electrocardiography," he writes. "I also have discovered skiing is the best family sport!" The children, **Judith**, 19, and **Douglas**, 17, agree.

Bernard E. Godwin settled in general practice 17 years ago in Big Bear Lake, California, and remains there today, with his wife, **Marguerite Lawrence** (Red Wing, Minn.) and five children: **Mary**, 19; **Raymond**, 18; **Henry**, 14; **Martha**, 13; and **Charles**, 8. He writes: "Big Bear Lake is a lot like northern Minnesota resort communities. It's a great place to raise children, which is about all we've done!"

John W. Gridley is in general practice in Arlington, Minn.

John M. Grogan is associated in practice with a radiology group in Denver, Colo. He took his residency training at the University of Colorado, and now teaches in its training program at Denver General Hospital. He and his wife, **Jane**, are at home at 215 Krameria Street. They have a son, **Dennis**, 20, at Dartmouth college who plans to enter Medical School. Another son, **Michael**, 18, is a freshman at Colorado College. They also have two daughters, **Aline**, 10; and **Jane**, 6.

Wilson B. Hall is a neuropsychiatrist at the Veterans Hospital, St. Cloud, Minn. He has been there 16½ years, and served in the Army medical corps 1944-46. He and his wife, **Mary**, live at 19 33rd Ave. N., St. Cloud.

Ellsworth K. Haugseth practices orthopedic surgery at the South Bend, Ind. Clinic, and lives at 820 N. Ironwood Dr. He served in the Army 1945-47, and moved to South Bend 14 years ago. His wife, **Mary**, is from St. Paul.

Blair J. Henningsgaard joined the Fowler Clinic, Astoria, Ore. 15 years ago as an internist and has stayed on. He was president of the Oregon State Medical Society 1961-62, and lives at 1482 Jerome Ave. with his wife, Edith, and Lisa, 12; Blair, Jr., 11; JoLee, 8; and William, 5.

E. G. Hestenes is a Lutheran medical missionary in general practice at the Hlabisa Mission Hospital, Zululand, Republic of South Africa. His wife, Lilah, is with him. They have a son, Mark, and a daughter, Karen. They arrived there in 1948. A colleague from the Class of 1943, (December), Dr. Arthur M. Hall, also practices at the mission hospital.

Philip W. Hursh spent two years in small town private practice, then returned to the University of Minnesota where he has divided his time for the last 14 years as University Hospitals Health Officer and the University Students Health Service medical staff. Phil likes bowling, fishing, and "playing Mr. Fixit." He and his wife, Esther, live at 5352 River View Rd., Minneapolis. Their children are Michael, 15; Susan, 13; and Roger, 11.

Robert A. Huseby is engaged in research and teaching at the University of Colorado School of Medicine. His address is 6401 W. Colfax Ave., Denver, Colo.

Lyle S. Jacobs is an internist in Monrovia, Calif.

Frank E. Johnson, a thoracic and cardiovascular surgeon in Minneapolis, has a son, Frank, Jr., in the freshman class at the Medical School. "Another son, Terence, will take a pre-medical course in college next Fall," he writes. Frank is head of the thoracic surgery service at Hennepin County General Hospital and is a clinical assistant professor at the Medical School. His wife, Beryl (nee Johnson) was a nurse, and hopes their daughters, Therese, 13; and Kathy, 9, may follow in her footsteps. The family lives at 4839 Girard Ave. S., Minneapolis 9.

Georgia L. Johnson is associated in practice with the Long Beach Unified Schools Health Service, Long Beach, Calif. She



FRANK E. JOHNSON



WILSON B. HALL

lives at 4029 Elm Ave. with her husband, Rev. Martin C. Olson, a Lutheran minister. They are parents of Peter, 19; Sandra, 16; and Mark, 14. The Olsons spent five years at a Lutheran mission hospital in Tanganyika. Two of their children were born there. They have been in Long Beach about 10 years.

Joseph Jorgens is a full time associate professor of radiology at the University of Minnesota Medical School, assigned for the last 11 years to the Minneapolis V.A. Hospital. He received the Ph.D. in 1954, and served in the Army during World War II. He lives with his wife, Alice, at 176 Taylor, Fort Snelling, St. Paul, Minn. Their children are Beth, 14; Joe, 12; Jeanne, 9; Jan, 6; Jeffrey, 4; and Jay, 2.

Harold A. Kaplan practices internal medicine in Minneapolis in association with Dr. Earl Hill (Med. '42), and teaches at the Medical School. He served in India during World War II with the Army, and now lives at 3554 France Ave. S. His family consists of his wife, Ruth, and daughters Diane, 16; and Susan, 13.

John D. Kaster sends greetings and best wishes to classmates and word that he has practiced pediatrics for the last 14 years in San Mateo, Calif. He is married to Jean Goldsmith of Portland, Oreg., and lives at 955 Jackling Drive, Hillsborough, Calif. Their children are Kathleen, 16; and Cynthia, 12. In 1960, John was Democratic Party nominee for the U.S. House of Representatives from California. He teaches at Stanford University Medical School and practices alone.

Arthur Kirschbaum is deceased.

George V. H. Kleifgen is a general surgeon. He has practiced in Las Vegas, Nev. since 1957 and lives at 701 Rancho Circle. He spent 1943-47 on a surgery fellowship at the Mayo Foundation, and served later in the Army medical corps. He and his wife, Margaret, are parents of a married daughter, and two



G. V. H. KLEIFGEN



JOHN D. KASTER



SHELDON M. LAGAARD

sons, George, Jr., 18; and Paul, 14. The No. 1 hobby, Dad says, is home and family.

Julian R. B. Knutson is an internist practicing with two other partners in Long Beach, Calif. He has been there 13 years, following completion of a fellowship at the Mayo Foundation in 1950. He teaches at UCLA Medical School, and served in the Army medical corps 1945-47. His wife, Mary, is from Owatonna, Minn. Home is at 261 St. Joseph Ave., Long Beach. Their children are Ann, 17; Marcia, 15; and Rolf, 11.


Sheldon M. Lagaard practices orthopedic surgery in Minneapolis in partnership with Dr. Mally Nydahl (Med. '34) and Dr. David J. Nelson (Med. '45). Shelly teaches at the Medical School, Hennepin County General Hospital, and Gillette State Hospital, and received his own specialty training at Minneapolis V.A. Hospital 1954-57. He is married to the former Marguerite Molm of Minneapolis. They live at 5709 Schaefer Rd., Minneapolis 24, and are parents of Sheldon, Jr., 18; Meredith, 16; Scott, 10; and Steven, 9.

Kenneth R. Larson has been in general practice in St. Paul, Minn. since April, 1946, when he received his discharge from the Medical Corps of the U.S. Navy. He lives at 354 Cherokee Avenue with his wife, Ella, and has a son, Leland, 23. Ken's special interest is in treatment of alcoholics, particularly by the use of hypnotism, for which he was cited in 1960 by the Alcoholics Anonymous organization. Later that year, he was honored for his work by the national "Employ the Physically Handicapped" movement. In 1956, he founded American Geriatric Enterprises, Inc. (A.G.E.), a private industrial shop in St. Paul which employs men whose age is a handicap to obtaining jobs.

Frederick Lengby is deceased.

Gilbert G. Lenz has been a general surgeon in Reno, Nevada since 1951, when he completed a residency at the University of Minnesota. He served in the Army in Europe 1944-46, and is married to the former Elizabeth Youssi of Robbinsdale, Minn. They live at 10550 Dryden Dr., with their children: Annelise, 16; John, 15; Andrea, 13; Mark, 12; Paul, 10; Peter, 8; and Joel, 6.

John H. Linner is president-elect of the Minneapolis Surgical Society and recently became associated in a general surgery practice with Dr. Harrison Farley of Minneapolis. John lives at 4616 Moorland Ave., Minneapolis 24, with his wife, Evodia, and Kristin, 14; Jennifer, 12; Andrea, 10; Victoria, 8; and Elizabeth, 4. John served 32 months during World War II, participating in the invasions of Normandy and Okinawa. He received his sur-



FRANCIS T. LYTLE



LORAN B. MORGAN



KENNETH R. LARSON

gery training at the University of Minnesota, and is now on the clinical teaching staff.

Francis T. Lytle practices internal medicine and gastroenterology in Fargo, N.D., where he has been located since 1947. He served in the Navy from 1945-46 and married Dorothy Whitney of Minneapolis. Their children are Bruce, 18, a student at Stanford U.; and Mary Grace, 15. Their home address is 1306 1st St. N.

Lester MacLean is deceased.

Richard M. Magraw is a fulltime associate professor of psychiatry and internal medicine at the University of Minnesota, and is director of the Medical School's Comprehensive Clinic program. He has been at the Medical School since 1950, but spent 2½ years in general practice at Two Harbors, Minn. prior to his present appointment. He served with the Army in Korea and Japan 1952-53, and now lives at 455 Tarrymore Ave., Minneapolis, with his wife, Shirley. Their children are Wendy, 18; Susan, 16; Richard, 12; and Tom, 5.

James C. Mankey practices internal medicine in Minneapolis in partnership with Dr. Charles Lindemann (Med. '46) and Dr. Robert Breitenbucher (Med. '46). "I have two wonderful partners and we have 21 children depending on us," he comments. "We hope some will enter the University and maybe the Medical School." Jim has been in the field of internal medicine for 15 years, and spent 1945-57 in military service in the Far East. He and his wife, Margaret, have seven children: Merodie, 15; Michael, 14; Molly, 13; Mark, 12; Mary, 10; Martin, 8; and Matthew, 5. They live at 4510 Fremont Ave. S., Minneapolis. Jim is vice president of the Minnesota Medical Alumni Association.

William L. Minkowski practices internal medicine in Palo Alto, Calif.

Allan E. Moe practices alone as an internist and lives at 1724 Short Hills Rd., Sacramento, Calif. He is head of the Department of Medicine at Mercy Hospital, is associated with two other hospitals, and is a medical consultant to the Social Security Administration. He completed a fellowship in medicine at the Mayo Foundation in 1946 and has been in Sacramento about 10 years. His wife is the former Elaine Eide of St. Paul, and their children are Edward, 17; Margery, 16; Barbara, 14; and James, 8.

Loran B. Morgan spent eight years in general practice in Torrington, Wyo., then took a residency at Minneapolis General Hospital, and later returned to Torrington in 1959 to the private practice of ophthalmology. He is married to a nurse from that city, Beth Ashburn, and they are parents of Beth, 19; and Dan, 15. The family home is at 138 Linda Vista. Loran served with the Army in Europe in World War II and is now a consultant to the V.A. Hospital in Hot Springs, S.D.

John B. Moyer was president of the Minnesota Heart Association during 1962 and has practiced internal medicine and cardiology at the Duluth Clinic, Duluth, Minn. for the last 14 years. He served with the Army in Europe during World War II and now lives at 2614 E. 6th St., Duluth. He is married to the former Charlotte Smith of Minneapolis. Their family includes Tom, 17; Mary Beth, 15; Kay, 13; Paul, 11; and Martha, 5, all of whom enjoy the outdoor recreation available in northeastern Minnesota. John is also a trustee of the Minnesota Medical Foundation.

John Neander is deceased.

Bernette Nelson is now married to Mr. Joseph Pellikka and lives at 2961 Pine Ave., Slayton, Minn. She writes: "I did general practice for 12 years in the country and then in Richfield, Minn. Seven years ago I took down my shingle to raise a family, and now have Bobby, 7; and Patty, 6. It's my plan to return to general practice soon." Her husband is a banker.

Bernice A. Nelson was in general practice 12 years but has not practiced since 1956, when her first child, Jimmy, now 7, was born. She and her husband, John R. Haley, also have another son, Paul, 5. They live at 6215 Fifth Ave. S., Minneapolis 23. "I hope to return to part time practice in the near future," she says.

Harold L. Neuenschwander has practiced internal medicine and allergy for nearly 15 years in Knoxville, Tenn. He teaches at the University of Tennessee Memorial Research Center and Hospital, and lives at 7109 Sheffield Dr. His wife, Virginia, is a University of Minnesota graduate (1943), and they are parents of seven: Allen, 17; Roy, 15; Mark, 14; Nancy, 13; Patty, 10; John, 7; and Neal, 5.

Mark E. Nolte recently moved to Helena, Mont. where he is now in general practice at the Veterans Administration Hospital, Ft. Harrison. He served in the Navy in World War II and also the Korean War, and spent 15 years in general practice in Portland, Ore. His wife, Mary, is from Fargo, N.D. They have two daughters, Nancy, 16; and Virginia, 11.

Robert E. Nord is associated in practice with an 11-man radiology group in Minneapolis, a practice he began in 1947 after completion of radiology training at the University of Minnesota. Bob's wife is the former Marion Handlon of Minneapolis. Their children are Mary Ann, 17; Marcia, 15; and John, 13. The family lives at 4824 Maple Rd., Minneapolis 24.


Albert J. Olson is in general practice at the Owatonna, Minn. Clinic, and has a special interest in dermatology. During 17 years in Owatonna, he has been president of the Rotary, Chamber of Commerce, and Zuhrah Shrine Club. He served in the Pacific area during World War II, and is now married to Dorothy Robinson of Los Angeles, Calif. Their children are Susan, 16; Craig, 14; Sally, 12; Carla, 8; and Mark, 3. The family lives at 525 Ridge Road.



C. KENT OLSON



JOHN B. MOYER



A. J. OLSON

C. Kent Olson, Minneapolis, has been a neurological surgeon for 14 years since finishing a residency at the University of Minnesota. After Medical School, he served with the Navy, and fought in the Guam and Iwo Jima invasions. "Today," he writes, "I have a rather ordinary collection of old battle and coronary scars." He and his wife, Patricia, are both fliers. They were expecting the birth of their first child in March, 1964. They live at 1208 Cedar Lake Rd., Minneapolis.

Valentine O'Malley is an internist in private practice in St. Paul, Minn., and is a clinical associate professor at the Medical School. He is also a lieutenant colonel in the Minnesota National

Guard, and specializes in cardiology in his medical practice. Mrs. O'Malley is the former Lorraine E. Anderson. They are parents of Mark, 20; Timothy, 17; and Susan 12. The family home is at 1960 Summit Ave., St. Paul.

Mary Helen Pennington is a medical fellow specialist in child psychiatry at the University of Minnesota Hospitals. She lives at 1955 Kenwood Parkway, Minneapolis, has been in child psychiatry training about two years, and has three children: Virginia, 15; Scott, 13; and Steven, 10.

Carrell A. Peterson practices radiology with a group in Oakland, Calif. that services Children's Hospital and Merritt Hospital. He has been there 15 years, and is also a consultant to the U.S. Naval Hospital in Oakland. He served in the Navy in the South Pacific during World War II, and married Deirdrellen Dickson of San Francisco. They are parents of Karin, 15; Kathleen, 15; John, 9; and Blair, 2½, and live at 6801 Estates Drive, Oakland 11. His hobbies are golf and photography.

Elroy R. Peterson has practiced internal medicine in Ames, Ia. since 1951, and is associated with the 23-man group at the McFarland Clinic. He is married to the former Jean Austin of Preston, Minn., and their children are Mark, 17; Jane, 16; Polly, 14; Betsy, 10; and Martha, 8. He comments: "We enjoy living in a University town and much of our life revolves around school activities. Each summer we go on a long camping trip, usually to a sea coast area." The family home is at 403 N. Franklin.

Floyd R. Peterson established a pediatrics practice alone in Los Angeles, Calif. 15 years ago, and settled down with his wife, Peggy Anderson, a 1942 U. of Minn. graduate. They live at 6313 Riggs Place. They have a son, Christopher, 13, a daughter, Susan, 20, and two grandsons. "I've survived three coronaries," he writes, "and may retire ultimately back in Minnesota. We like golf, cards, studying foreign languages, and hope to visit Europe soon."

Thomas N. Poore is a general surgeon, practicing alone in Redwood City, Calif. He lives in nearby Atherton, Calif., at 97 Isabella Ave., with his wife, the former Barbara Elliott of Duluth. Their children are Thomas, 20; Rodger, 17; Barbara, 14; and Patricia, 7. Tom completed his surgery training at the Mayo Foundation in 1950, and has practiced in California ever since.

Claude H. Potts is in private practice at the Beardstown Clinic, and lives at 316 W. 8th St., Beardstown, Ill. He served in the Army 1944-46, then settled in Beardstown, and is married to the former Barbara MacDonald of Virginia, Minn. They are



JAMES W. REID AND FAMILY

parents of Claude, 20; Howard, 18; Sarah, 16; Lester, 12; and Lora, 11.

James H. Pulford served in the Army for three years following Medical School, then took a residency in urology at Harbor General Hospital in Torrance, Calif., before establishing a urology practice in Salinas, Calif. 14 years ago. He lives at 204 San Juan Drive, and is married to the former Edith Craswell of Minneapolis. They are parents of James, Jr., 19; Jeffrey, 16; John, 15; and Nancy, 12. "I'm working to put the kids through college and enjoy the hobbies of sailing and duck hunting," he writes.

Henry W. Quist, Jr. says "Minneapolis is still a wonderful city in which to live and raise a family." He's been here 16 years in general practice, and lives at 4116 Glencrest Rd. Mrs. Quist is the former Jean Watson of Champaign, Ill. The children are Marcia, 14; and Larry, 12. The family enjoys spending summers at their vacation home on Bay Lake near Deerwood, Minn. Dad served with the Army from 1944-46.

John W. Rebuck is chief of the Division of Laboratory Hematology, Henry Ford Hospital, Detroit, Mich. He trained in hematology at Minnesota under the late Prof. Hal Downey, receiving the Ph.D. in 1947. John is the author of five medical textbooks; likes trout fishing in the Rockies; is an associate

editor of the journal BLOOD: is president of the Michigan Pathological Society and the International Society for the Study of the Reticuloendothelial System. Mrs. Rebeck (Virginia Reed) is from Denver, Colo. They now live at 16955 Beverly Rd., Birmingham, Mich.

James W. Reid has been in general practice 18 years, nine of which have been spent in South St. Paul, Minn. He lives there at 310 Reid Lane, with his wife, Lola, and family (see photo) consisting of Mary Lou, 16; Jimmy, 14; Phillip, 8; Gregory, 2½, and David, (held by Mrs. Reid), who was born in January, 1964. Jim served with the Army medical corps in Europe 1944-46, and is now surgeon general of the national VFW organization.

Roberta G. Rice is a professor of surgery at Yonsei University Medical School, Seoul, Korea, a post she has held since 1956 under the missionary program of the Methodist church. "I hope any travelling alumni will contact me here at Severance Hospital when they come to the Orient," she writes. In February, she directed the first continuation medical education course ever held at Yonsei. Roberta received her own surgery training at the Mayo Foundation, and spent 1950-56 as a surgeon at the Grand Island, Neb. Veterans Hospital. Her present address is c/o Methodist Mission, International P.O. Box 1182, Seoul, Korea.

Gordon S. Riegel has five daughters and one son, ranging in age from 18 to 5 years old, and lives at 935 W. Cheyenne Rd., Colorado Springs, Colo. His wife, Merodie, is from St. Paul. Gordon has practiced internal medicine there with a group for more than 10 years. He took his residency training at Minneapolis General Hospital, and was certified in 1957.

Orville M. Roan is deceased.



JOHN REBUCK



ROBERTA RICE



GORDON S. RIEGEL

Betty St. Cyr Gilson is married to a classmate (Dr. John S. Gilson), has two children, and lives at 3 Prospect Way, Great Falls, Mont. She is director of the Heart Diagnostic Center of the Montana State Board of Health. Like her husband, she took a residency at Western Reserve 1943-47. She writes: "I want to report to the 1939 Admissions Committee that it has been entirely feasible to have a busy medical career and also keep a happy family going. All it requires is judicious choice of husband and exceptional children. Easy!"

Raymond A. Sanford is a pathologist at St. Joseph's Hospital, Mankato, Minn. He has been there ten years, and took his residency at the Mayo Foundation. He served in the Army in the Pacific campaigns late in World War II. Ray is married to Dorothy Peterson of North St. Paul, Minn. They live at 237 Peterson St. and are parents of Ellen, 19; and Richard, 15.

Abe M. Sborov practices general surgery with the Edina Medical and Surgical Group and lives at 4716 Upper Terrace, Minneapolis, Minn. His wife, Ingeborg, was from Norway. Their children are Michael, 20; Steven, 17; Merry, 15; and Mark, 15. Abe served in the Army in Europe during World War II, and during the Korean War, when he was chief of surgery at the U.S. Army Hospital, Ft. McClellan, Alabama.

Edmond A. Schlesselman has been in general practice alone in Fresno, Calif., for the last 14 years. His wife is deceased. Their children are Jane, 20 (married); John, 18; and Martha, 15. They live at 4580 N. Palm Ave., Fresno.

Paul B. Schoeneberger has been in general practice in Perham Minn., since 1946. He served in the Army in Europe during World War II, and is married to the former Jeanne Book of Mankato, Minn. They are parents of Anne, 15; Stephen, 13; Carol, 12; Elizabeth, 10; and Susan, 8.

Walter B. Shelley is a clinical professor of dermatology at the University of Pennsylvania and is in private practice in Philadelphia. He received a Ph.D. from the University of Minnesota in 1941, and took his dermatology residency at Pennsylvania 1946-49, following service with the Army medical corps. Walter is the author of 4 books and about 175 research papers. He lives at 506 Meadowbrook Circle, St. Davids, Pa. His wife is the former Marguerite Weber of Duluth, Minn. Their children are Peter, 19; Anne, 16; and Barbara, 14.

Anton W. Skoog-Smith became associated with the Veterans Hospital, Lincoln, Nebraska, two years ago, and has been a radiologist for 14 years. He teaches at the University of Nebraska Medical School, and served in the Army in Europe 1944-46.

His wife, Marion, is from St. Paul. Their children are Debby, 16; Mari-Chris, 15; and Judd, 14. They live at 839 S. 93rd St., Omaha, Neb.

Clyde L. Smith is a partner in the Missouri Valley Clinic, Bismarck, N.D. where he practices surgery and obstetrics-gynecology. A son, Clyde W., 25, is a senior at the University of Minnesota Medical School. Dr. Smith and his wife, Kathryn, have a total of eight children, the others being, Roger, 23; Kay, 19; Susan, 13; Patricia, 12; Steven, 11; Gregory, 9; and Mary, 6. Mrs. Smith is president of the Women's Auxiliary of the North Dakota State Medical Association, and teaches 5th grade in a Bismarck elementary school. Clyde is president of the Bismarck Sertoma Club, likes golf, and served in the Navy in World War II, seeing action in the invasion of Saipan. The family lives at 622 Raymond in Bismarck.

Paul M. Smith is in general practice in Lake Crystal, Minn. with his brother, Dr. Harry J. Smith (Med. '50). Paul and his wife, Joyce, live on a 22-acre plot on the shores of Crystal lake with their nine children ranging in age from 19 to 8 years old. They are Paul, II, David, Gail, Deborah, Jan, Mark, Joy, Jonathon, and Julie. "There's never a dull moment," he notes. "We especially enjoy water skiing, bowling, fishing, and our horses and sheep." (Editor's Note: Paul Smith has the largest family—9 children—in the Class of March, 1943)

Clifford D. Snyder is in general practice in Kiester, Minn.

Donald C. Sterner has practiced ophthalmology for 13 years in St. Paul. He's on the clinical staff at the Medical School, and lives, at 1068 Lombard Ave., St. Paul. His family includes his wife, Barbara (of Red Wing, Minn.); Karin, 16; Steven, 13; and Kristin, 10.

James D. Stephen is a pathologist and director of laboratories at Regina General Hospital, Saskatchewan. He lives in that city



PAUL M. SMITH



DONALD C. STERNER

at 18 Turnbull Place with his wife, Mary, and three children: Mary, 11; James, 10; and Jean, 6. Jim attended the Medical School during his third and fourth years under a Rockefeller Foundation Studentship, then finished his undergraduate medical education at the University of St. Andrews in Scotland.

Robert Tarail has recently become associated with the Department of Internal Medicine, Veterans Administration Hospital, Martinez, Calif. He lives nearby at 115 Dale Ave., Piedmont, Calif. A tennis enthusiast, he also spends much of his time in research in water and electrolyte metabolism. He is married to the former Marie Guthrie of Minneapolis. Their children are Bob, 14; Mary, 13; and Abbey, 11.

Charlotte Teschan Merrick says she "practiced about a year in Minneapolis after graduation, then followed my husband around while he was in the Army, and raised two boys, Roger, 18; and Michael, 16." She is now health officer of the Village of North Oaks, a suburb of St. Paul, Minn., and lives at 6 Ridge Rd. Her husband is Dr. Robert L. Merrick (Med. '44). She interned at Swedish Hospital, Minneapolis, and now enjoys golfing, hunting, painting and bowling.

David S. Thorsen "enjoys his practice in child psychiatry," and calls it "an emotionally rewarding field." He has been affiliated with the Wilder Clinic, St. Paul, for 13 years, and teaches at the Medical School and at Gillette Hospital, St. Paul. His wife is the former Gretchen Prellwitz of Shakopee, Minn. The children are Sylvia, 20; Tony, 18; Peter, 16; Nina, 6; and Haakon, 5, and the family home is at 79 Otis Avenue. David served on a navy destroyer during World War II.

Laurence G. Thouin practices general medicine and obstetrics-gynecology in Hibbing, Minn.

Elizabeth Troxil is a fellow in Physical Medicine and Rehabilitation at the University of Minnesota Hospitals.

Harold Ulvestad is a clinical assistant professor at the Medical School and is an otolaryngologist in private practice in Minneapolis. He took a residency at the University of Minnesota from 1946-49 and served with the Army in Europe for two years shortly after Medical School. He lives at 6708 Cheyenne Trail, Minneapolis 24, with his wife, Ingeborg, and Harold, Jr., 19; Rolf, 16; Ann, 13; and Laura, 12.

Paul A. Wagner is in general practice at the Lloyd Center in Portland, Ore.

Albert Welte is deceased.

THE MEDICAL BULLETIN

Leslie Zieve is a fulltime professor of internal medicine at the Medical School, and has been assigned since 1949 to the Minneapolis Veterans Administration Hospital. He completed his own residency training there in 1949, was certified in internal medicine in 1951, and received a Ph.D. from the University in 1952. He served in the Army during World War II, and now lives with his wife, Bernice, at the V.A. Hospital, Bldg. 13N. They have a son, Franklin, 19.



Staff Meeting Report

The Gastrointestinal and Anorectal Manifestations of Leukemia*

David L. Siegal, M.D.†
and
William C. Bernstein, M.D.‡

Leukemia, as defined by Dameshek and Gunz, is a "generalized, self-perpetuating abnormal proliferation (slow or rapid) of one of the leukocytic tissues, often associated with abnormal white cell counts, and eventually leading to anemia, thrombocytopenia, and death." Virtually all of the organ systems in the body may be involved by this disease. This report reviews the gastrointestinal manifestations and complications of leukemia with particular emphasis placed on the anorectal aspects of these problems. Because of the possible relationship between leukemia and lymphoma, the proctologic aspects of lymphoma are also discussed.

The leukemias and lymphomas may manifest themselves in all portions of the gastrointestinal tract. In the acute leukemias oral findings may be a prominent sign. There may be bleeding from the gums, gingival hypertrophy with an associated dark red color to the gingivae, and areas of ulceration or necrosis on the mucosal surfaces of the oral cavity. There may be a septic condition of the tonsils and fauces resembling Vincent's angina, and tonsillar hypertrophy and pain in both the acute and the chronic varieties.

Grossly, leukemic lesions of the stomach may be diffuse or localized. In the diffuse type there may be enlargement of the stomach, with great thickening of the mucosal rugae. In the localized variety firm nodules may be seen under the mucosa varying in size from a few millimeters to several centimeters. There may be superficial ulceration or central umbilication.

*Presented at the Staff Meeting of University Hospitals on February 14, 1964, and supported by a grant from the Lewis and Annie F. Paper Foundation, St. Paul, Minn.

†Fellow, Division of Proctology

‡Clinical Professor, Department of Surgery, and Director, Division of Proctology

In the intestines the lesions may be plaque-like or polypoid masses which may become quite large and ulcerate or may even lead to intussusception or perforation. Microscopically most of the gastrointestinal lesions show dense leukemic infiltrates in the mucosa and submucosa. There may be large aggregations of lymphocytes resembling lymph nodes in the mucosa and submucosa, and Peyer's patches may become enlarged and infiltrated by leukemic cells.

Malignant lymphoma of the gastrointestinal tract is a relatively rare disease. The findings in these cases may once again be localized or diffuse. With the sigmoidoscope, a mass may be seen which is covered with pale, freely movable mucosa. Gradually the mucosa is thrown into folds to present a "hill and valley" appearance. Later the lesion is diffuse and the mucosal folds become prominent giving rise to a picture resembling the convolutions of the brain. Malignant lymphoma can also present itself as multiple polyposis affecting long segments of the gastrointestinal tract.

The anorectal complications of the leukemias are characterized by thrombosis, necrosis, ulceration, sloughing, and sometimes abscess formation. These changes may or may not be accompanied by leukemic infiltration of the anorectal area. In addition leukemia can also produce rectal bleeding. These complications have received little notice in the literature.

During the last year, the authors have seen six patients with various forms of leukemia who developed anorectal lesions. These may be briefly summarized as follows:

Case 1. A 70 year old white male with subacute myelogenous leukemia developed perianal pain and induration. Four weeks later this was incised and drained revealing only necrotic tissue. Microscopic examination revealed leukemic infiltrate. He died 24 days after surgery.

Case 2. A 13 year old white female with acute lymphatic leukemia developed rectal pain four weeks prior to death. A perirectal abscess developed which was incised and drained. Some healing occurred but drainage continued. She then developed ulceration and necrosis of the anus, and died 2½ weeks following surgery from a gram negative septicemia.

Case 3. A 60 year old white male with chronic myelogenous leukemia developed anal pain. Examination revealed raw, excoriated external hemorrhoids with a purple discoloration. He subsequently developed painful nodules around the base of the scrotum and the inguinal areas. These became ulcerated and

infected. He expired three months following the onset of the perianal infiltrations.

Case 4. A 59 year old white female was diagnosed as having multiple myeloma. At the time of diagnosis she complained of pain on defecation. Examination revealed a large, necrotic, bleeding, shallow ulcer covering the posterior quadrant of the anus and a smaller, similar ulcer anteriorly. She expired one month following the onset of the anal lesions.

Case 5. A 6 year old white female with subacute lymphatic leukemia (initially diagnosed as malignant lymphoma) developed high fever and anal pain. Examination revealed marked induration and redness of the perianal area, a patulous sphincter and a deep, necrotic posterior anal ulcer. She expired two weeks following the onset of the anorectal lesions.

Case 6. A 12 year old white female with acute lymphocytic leukemia developed a high fever and rectal pain. Examination revealed anterior and posterior anal ulcers which had grayish bases. These were treated conservatively and healed in two to three weeks. Three weeks following the onset of the anal lesions she developed an abscessed tooth and seven weeks following their onset she developed nasal bleeding and an *E. coli* septicemia from which she expired.

The authors have been impressed with the close temporal relationship between the onset of acute anorectal lesions in leukemic patients and their ultimate demise. It is our belief that the onset of these lesions may often be of grave prognostic import, especially in the acute leukemias. Patients with chronic leukemias, however, may develop ordinary anorectal lesions which may be treated by, and will respond to, standard procedures.

The management of acute anorectal lesions in patients with acute leukemia should be conservative. Wound healing is usually poor in these patients and surgical intervention should be limited to incision and drainage of obvious abscesses. Antibiotics should be used cautiously, and never prophylactically; specific antibiotics should be used, however, when indicated.

Staff Meeting Report

Psychological Correlates of Unilateral Temporal Lobectomy in Psychomotor Epileptics*

Manfred J. Meier, Ph.D.†

and

Lyle A. French, M.D., Ph.D.‡

The functional role of the temporal lobe and related limbic system structures in the organization and expression of emotional patterns of behavior has been a subject of intense neuropsychological research since the classic observations in monkeys of profound behavior changes following bilateral temporal neocortical and paleocortical ablations. Personality disturbances in temporal lobe seizure patients have been clinically documented for years, but never accessible to systematic investigation until the introduction of neurosurgical removal of the primary epileptogenic discharging focus as a means of increasing seizure control. The present investigation constitutes an attempt to (1) interrelate some objective response-restricted personality variables as measured by the Minnesota Multiphasic Personality Inventory (MMPI) to preoperative bilateral and unilateral temporal lobe EEG abnormalities, and (2) determine the magnitude of changes in MMPI scale scores and an Index of Psychopathology (Ip) one year or more following unilateral temporal lobectomy in psychomotor epileptics.

The study sample consisted of 53 such patients, poorly controlled on the usual anticonvulsant medication, 40 of which later underwent unilateral temporal lobectomy. Preoperative determination of unilateral or bilateral temporal lobe abnormalities was based on at least two consecutive and interpretively consistent EEGs obtained within six months before operation. An excisable epileptogenic focus in the temporal lobe was confirmed at the time of surgery with extensive cortical and depth electrography. Resection of that portion of the temporal lobe was

*Presented at the staff meeting of University Hospitals on February 21, 1964, and supported by Research Career Development Award NB-K3-18,539 and Research Grant NB-01158 from the National Institute of Neurological Diseases and Blindness, Bethesda, Md.

†Associate Professor, Division of Clinical Psychology

‡Professor and Director, Division of Neurosurgery

performed in an *en bloc* fashion. Hemostasis was obtained with silver clips, and little or no coagulation was done on the part of the brain left *in situ*. Resection was carried perpendicular to the surface of the brain, through the lateral ventricle, and then through the hippocampus to the medial aspect of the lobe with the insula being exposed *in toto*. In most instances the posterior margin of the resection was seven to nine centimeters from the tip of the temporal lobe.

Elevations on the Lie, F, K, Hypochondriasis (Hs), Depression (D), Hysteria (Hy), Psychopathic Deviate (Pd), Masculinity-Femininity (Mf), Paranoia (Pa), Psychasthenia (Pt), Schizophrenia (Sc), Manic (Ma), Social Introversion (Si), Caudality (Ca), and Ip score means were compared and statistically analyzed utilizing the t test for correlated or uncorrelated means depending upon the requirements of each comparison.

Preoperatively, patients with bilateral EEG abnormalities scored significantly higher on the F, D, Pa, Sc, Ca, and Ip score means than those with unilateral abnormalities. Among the bilaterals, the presence of bitemporal independent spike foci was associated with higher elevations on the D, Hy, Pa, Pt, Ca and Ip means. Pre-operatively to post-operatively, significant reductions occurred on the Pa, Ca, and Ip means while K increased. Left temporal lobectomy was associated with a significant decline on Pa, Si, Ca, and Ip while Sc and Ca decreased selectively following right temporal lobectomy. A non-surgically treated control group showed no significant mean changes.

Changes as a function of preoperative EEG classification were observed for the bilateral group with reductions on Ca and Ip and an increase on K. Among the bilaterals, the independent spike foci group showed significant reductions on Pa, Pt, Si, Ca, and Ip.

Results suggest that indications of personality disturbance among psychomotor epileptics are more related to the presence of bilateral EEG abnormalities, and that the presence of bitemporal independent spike foci may provide the major epileptogenic correlate of psychopathology as measured by the MMPI in individuals with temporal lobe lesions. Following unilateral temporal lobectomy, personality disturbances appear to undergo a selective decline on measures inferred to reflect schizoadaptive and depressive behavior patterns, especially among patients with bitemporal independent EEG spike foci preoperatively. This reduction in psychopathology does not appear to be especially profound nor can it be interpreted as a major reorganization of personality structure. Such effects on personality variables might be explained as a combined effect of the removal of an emo-

THE MEDICAL BULLETIN

tionally disruptive epileptogenically discharging focus in the temporal lobe and the improved seizure control subsequently achieved.

The authors wish to thank Dr. Frank Morrell and Dr. Fernando Torres for their careful interpretations of the EEG records.



Staff Meeting Report

Use of Radioisotopic Techniques for the Evaluation of Renal Disease*

Merle K. Loken, Ph.D., M.D.,† Robert E. Stejskal, M.D.,‡
and Kurt Amplatz, M.D.§

Radioactive materials have been used to advantage in studying many aspects of kidney disease. The literature on this subject indicates that emphasis has been placed on the evaluation of various aspects of renal function, although considerable effort has also been given to the differential diagnosis of causes of azotemia and of oliguria, the evaluation of symptomatic ptosis, renal size and contour, and the detection of renal tumors. The majority of our experience in this field has been gained in the last year, during which time we have performed more than 250 isotope renograms. Renal scans and split renal function tests were also performed on selected patients.

Numerous publications in renography have appeared since the pioneer work in this field by Taplin and Winter in 1955. Most investigators report radioisotope renography to be a useful technique in diagnosing renovascular hypertension, pyelonephritis and outflow obstruction. Our experience shows that the renogram is a useful tool in evaluating many aspects of renal disease providing extreme care is exercised in performance of the test. Such things as choice and dose of isotopic material, patient's hydration status, counting geometry, and methods of data recording must be closely controlled.

Through the years several isotopic preparations have been used for renography. The first of these to be used extensively was iodo-pyracet (Diodrast®) which is both filtered and excreted by the kidney. However, this material is also excreted by the liver so that detector placement may be extremely critical. This

*Presented at the Staff Meeting of University Hospitals on February 28, 1964.

†Assistant Professor, Department of Radiology, and Director, Radioisotope Clinic

‡Medical Fellow Specialist, Department of Radiology, and USPHS cardiovascular trainee under USPHS Grant No. 0900-4059-6.

§Associate Professor, Department of Radiology

source of interference was greatly reduced by preceding the renogram with a loading dose of stable Diodrast which blocked the liver clearance for the subsequent administration of the radioactive material.

Diatrizoate sodium (Hypaque®) and glucamine diatrizoate (Renografin®) labeled with radioactive iodine were the next agents to be tested. There is no appreciable liver uptake of these materials but their clearance by the kidney is rather slow. Their use at present is limited to split renal function studies.

More recently iodo-hippurate (Hippuran®) has been used for renography. It is cleared from the blood stream exclusively by the kidneys by rapid glomerular filtration and tubular secretion. This material tagged with I^{131} has been used in the majority of renograms being performed in our clinic. Another preparation receiving attention is a diuretic labeled with radioactive mercury (Hg^{197} -Neohydrin). This latter material remains fixed in kidney tissue for many days and is ideally suited for renal scans.

In order to perform renograms successfully, it is necessary to use a dual radioisotope assaying system each having a detector, spectrometer, rate meter and recorder. Our unit employs 2 by 2 inch scintillation crystal detectors which are collimated by lead cylinders to provide a distance of 8 inches from the crystal surface to the patient's skin. This distance is desirable in order to minimize differences in the kidney to body surface distance among our patients. These spectrometers provide a means for discriminating against background radiation, while the rate meters analyze the rate at which radioactivity is being received and pass this information on to a strip chart recording system.

It has been mentioned that the hydration status of the patient appears to be quite important in isotopic renography using Hippuran. We have found that fully hydrated patients may exhibit a normal appearing renogram but, if they are fasted for eight hours before the test, an abnormal pattern is found.

Except for unusual circumstances, all renograms are performed in our clinic with the patient in a sitting position. This eliminates an occasional bizarre excretory pattern which may result by intermittent external pressure applied to the ureters with the patient lying prone or supine. A test dose of two microcuries of radioactive I^{131} Hippuran is administered intravenously to provide an accurate means for bilateral detector placement over the kidneys. After this has been accomplished, the dual assay systems are readjusted and a test dose of 25 microcuries of Hippuran is administered. The recorder chart is moved at

a rate of 12 in. per hour for the 30 min. period normally used for renogram studies.

There are three characteristic segments to the renogram curve. An initial spike usually lasting less than one minute commences within seconds after administration of the isotope and is conventionally referred to as the "vascular segment." It is realized, however, that the shape of this segment is due in part to renal function since materials such as labeled albumin, which is normally held within the circulation, yields a different shaped curve than is obtained using Hippuran.

Following this initial rapid rise the curve continues to rise at a slower rate to form a second segment which normally reaches a peak within five minutes after the isotope injection. The second or "functional" phase represents the rate of active tubular cell uptake of Hippuran and its secretion into the renal tubules. It is superimposed on the radioactivity in the vascular bed of the kidney area. A third and final component of the renogram is referred to as the "excretory phase" and relates to the removal of the Hippuran from the kidneys. The downward slope of this segment of the curve indicates the patency of the urinary outflow tract.

There are minor variations in the typical pattern of the renogram. However, in all normal patients the three segments referred to above are readily distinguishable and when the renogram is performed under carefully controlled conditions it is possible to quantitate various aspects of the renogram curve. Our decision as to normalcy of a renogram is based on measurements of the height and shape of the vascular phase, the height and timing of the functional peak, and the rate at which excretion occurs.

We have performed 126 renograms on patients being evaluated for hypertension. Seventy-six of these patients had a normal renogram and a normal urea wash-out test. Eight patients within the group of 76 also had aortograms performed, three of which were reported to show renal artery stenosis. One of these stenotic sites was felt to be hemodynamically significant. Only one patient of the entire group exhibited a normal renogram but an abnormal urea wash-out test and aortogram indicative of renal artery stenosis. This renogram was one of our early studies and was performed with the patient fully hydrated rather than partially dehydrated as is presently done.

Renograms on 50 patients in this series were reported as abnormal. The patterns from 28 of these patients were not typical of renal artery stenosis (rather isolated decreased function and/or

delayed excretion) and these patients had normal urea wash-out tests. Renograms of the 22 remaining patients were quite typical of stenosis. Of these, 17 have also had aortograms, all of which confirmed renal artery stenosis. The five remaining patients are presently being scheduled for follow-up aortography despite having had normal urea wash-out tests.

We have also found the renogram to be useful in the evaluation of patients with symptoms suggestive of chronic renal disease and obstructive uropathy. Renograms together with scans and split renal function tests give a good indication of prognosis to be expected in azotemic and anuric patients. In addition, the renogram serves as a sensitive indicator of the postoperative course of patients with renal transplants.





MINNESOTA MEDICAL FOUNDATION NEWS

The 16th annual Scholarship Fund of the Minnesota Medical Foundation was announced recently. It will culminate September 28, 1964 when the Foundation expects to distribute approximately 60 scholarships to deserving medical students at the University of Minnesota. The Scholarship Fund, begun in 1949, is the largest individual program conducted by the Minnesota Medical Foundation in support of the Medical School. Since 1949, the Foundation has issued 384 scholarships worth a total of \$199,925.

Replacement of \$8,000.00 in a now-expired Avalon Foundation grant for scholarships is a major objective of the 1964 Scholarship Fund. The Avalon grant has been administered for the last three years as part of the Minnesota Medical Foundation Scholarship Fund.

Among larger gifts received recently by the Foundation are:

Lewis and Annie F. Paper Foundation: \$3,000.00 in support of travel for scientific purposes by fellows in the Departments of Medicine and Surgery.

Cargill Foundation: \$1,500.00 to support hypertension research by Dr. Louis Tobian, associate professor, Department of Medicine.

Mrs. Charles N. Hensel: \$7,500.00 added to Charles Norton Hensel Memorial Scholarship Endowment Fund.

Dr. Harold G. Scheie: \$1,038.00 to Scholarship Fund.

Margaret and James Kelley: \$1,000.00 to Scholarship Fund.

Friends of Dr. Paul S. Hagen: \$2,322.00 to support lectureship fund in his memory at Minneapolis V.A. Hospital.

Friends of Dr. Percival Ward: \$1,160.00 to hematology research fund in his memory.

Minnesota Society of Internal Medicine: \$500.00 to Scholarship Fund.

Alumni: \$9,754.61 to various purposes through 1963-64 Combined Appeal.

More newly-enrolled members of the Minnesota Medical Foundation are:

Class of 1921
Robert C. Murdy

Class of 1924
Carl E. Johnson

THE MEDICAL BULLETIN

- Class of 1927
Percy W. Harrison
Wilbert W. Yaeger
- Class of 1929
Alvin J. Meyer
- Class of 1930
Frank S. Bacon
Carl W. Laymon
Walter J. Minor
- Class of 1931
Dan R. Goldish
- Class of 1932
Elizabeth L. Conforth
- Class of 1933
Maurice Borkon
- Class of 1934
Warren E. Parker
- Class of 1936
N. J. Sundet
- Class of 1938
J. O. Lasby
- Class of 1939
Leonard L. Cowley
- Class of 1942
Frank D. Mann
- Class of 1943
Harold C. Anderson
Jarvey Gilbert
Lyle S. Jacobs
J. Ordie Shaffer
- Class of 1944
Robert N. Evert
Edward M. LaFond
Charles T. Louisell
Clark M. Marshall
- Class of 1945
Margaret Dowell-Gravatt
Herbert W. Johnson
John H. Reitmann
- Class of 1946
Robert I. Shragg
Sydney C. Sperling
- Class of 1947
Vernon A. Harrington
Matthew J. Weir
Martin L. Zucker
- Class of 1948
Paul J. Hauser
- Class of 1950
Roger M. Berg
- Class of 1951
Virgil E. Erickson
Milo L. Hansen
Thomas S. Johnson
- Class of 1953
Ramon M. Fusaro
Frank S. Preston
- Class of 1955
Richard A. Kunin
Phillip H. Meyers
- Class of 1956
Robert E. Dinsmore
Harlis D. Hanson
Richard B. Lieberman
Emil Schulz
John Edward Smith
George V. Tangen
- Class of 1958
Louis W. Banitt
Duane E. Ness
Robert A. Olson
- Class of 1959
Carl E. Johnson
Elmer W. Ylitalo
John F. Zachman
- Class of 1960
Lawrence W. DeSanto
- Class of 1962
Waldemar G. Johanson, Jr.
Donn S. Leaf
Paul E. Mertens
John N. Mork
Phillip A. Rierson
- Non-Alumni
S. T. Nerenberg
David L. Siegal
Gordon J. Strewler

Medical School News

A local chapter of the national Animal Care Panel is now functioning at the University of Minnesota to assure the continuing proper care and humane treatment of animals used in medical research at this institution.

The Upper Midwest Branch, based at the University, was founded in 1961 as a unit of the national Animal Care Panel which came into existence 11 years ago. Don E. Battles, junior scientist at the Medical School, is president of the chapter, which holds monthly meetings for its membership of 120 persons. June Smith, administrative laboratory technician, is chapter representative to the national Animal Care Panel, and was instrumental in founding of the Upper Midwest Branch.

A second major objective of the organization is to educate the public on the place of animals in medical research. Speakers appear before various civic groups, and interested persons are invited to tour the animal laboratories at the University. Close liaison is maintained with the Minnesota Citizens Committee on Health and Education, which has sought to enlist public support against legislation which would tend to restrict the use of animals in medical research.

The Animal Care Panel strives to maintain standards of uniformity in such matters as the size of cages, provisions for feeding and exercising, and the cleanliness of the animals' surroundings. Laboratory attendants at the University of Minnesota are offered a course in the care of laboratory animals. All individuals who work with animals are urged to attend.

VARIETY CLUB GIFT

University Hospitals received a check for \$65,000.00 from the Variety Club Heart Hospital Association recently. The gift will provide \$10,000.00 to the Heart Hospital's indigent patient care fund, and adds \$55,000.00 toward completion of the Association's pledge of \$500,000.00 for the building of a new wing at the Hospital. The Association's new building fund now stands at \$200,000.00, according to Gerard W. Frawley, association secretary and associate director of University of Minnesota Hospitals.

The Variety Club Heart Hospital association is the fund raising organization of the Variety Club of the Northwest.

THE MEDICAL BULLETIN

Directors of the Minnesota Medical Alumni Association and their wives played host to the Medical Student Council members and guests January 28th at a social occasion held at the new Alumni Club in Minneapolis.

Dr. Neil M. Palm, Association president, was master of ceremonies. Dr. Robert B. Howard, dean, spoke for the Medical School, and Dr. H. Mead Cavert, assistant dean, described progress on the Medical Student Center now under construction at the Medical School. Walter Bailey, president of the Class of 1964, spoke in behalf of the Medical Student Council. Forty-three persons attended.

The Association's annual Senior Class-Alumni luncheon will be held at 12 noon, May 8, 1964 in Coffman Memorial Union, University of Minnesota. The speaker will be announced shortly.

The Association's 27th annual meeting and reunion will take place Friday and Saturday, Oct. 16-17, 1964 in Minneapolis. The Class of 1939 will be honored on its 25th anniversary and tickets to the Minnesota-Illinois homecoming football game will be made available.



MAYO SCHOLARSHIPS—Four medical students from the University of Minnesota were recipients of the first \$500.00 Mayo Association scholarships which were awarded in 1963 under the program of the Minnesota Medical Foundation. They were guests of the Association February 12 during a tour of the Mayo institutions at Rochester, Minn. Visiting with Dr. Charles W. Mayo were (l-r) James A. Brockberg, freshman, Jasper, Minn.; Avie M. Overbach, sophomore, St. Louis Park, Minn.; Gerald C. Peterson, junior, Minneapolis; and at far right, Alvin Shemesh, senior, Minneapolis.

Alumni Deaths

◆ 1900

Dr. Peter J. Weyrens, Oakes, N.D. Died July 1, 1963 at the age of 90 of uremia secondary to renal arteriosclerosis. He had practiced for many years in Hebron, N.D.

◆ 1904

Dr. Tobias L. Birnberg, Los Angeles, Calif. Died February 14, 1964, at the age of 80. Formerly a clinical professor of pediatrics at the University of Minnesota Medical School, Dr. Birnberg had been in pediatrics practice for 60 years. He was a native of Vienna, Austria. He moved to California from St. Paul in 1945.

◆ 1949

Dr. Yale Joel Katz, Los Angeles, Calif. Died December 6, 1963. An established investigator of the American Heart Association and winner of the first Charles MacArthur Memorial Heart Award from the National Kidney Disease Research Foundation, Dr. Katz was also an associate professor of medicine in the University of Southern California School of Medicine.

Memorial Gifts

The Minnesota Medical Foundation acknowledges with gratitude recent contributions made in memory of:

Mr. Sidney Goldish
Minneapolis, Minn.

Mr. Walter Plaut
Great Neck, N. Y.

Mr. John Bellomo
St. Paul, Minn.

Mr. A. B. Lindall
Excelsior, Minn.

Michael Kane
St. Paul, Minn.

Mr. Morton Wilk
Fargo, N. D.

Mr. Charles Bernstein
St. Paul, Minn.

Mr. William M. Colby
Minneapolis, Minn.

Memorial gifts are a thoughtful means of honoring the memory of a relative, friend, or colleague. They serve the living by strengthening medical education and research at the University of Minnesota Medical School. Gifts may be designated for specific purposes. The Minnesota Medical Foundation acknowledges all gifts to both donor and next of kin.

COMING EVENTS

University of Minnesota Medical School

CONTINUATION COURSES FOR PHYSICIANS

1964

University of Minnesota
Center for Continuation Study

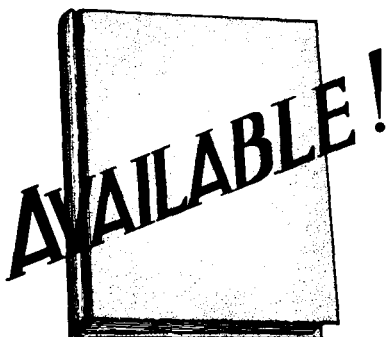- February 10 - 14 Proctology
March 17 - 20 Internal Medicine
April 23 - 25 Gynecology
May 4 - 6 Ophthalmology
May 14 - 16 Surgery
May 28-29 Trauma
June 3 - 5 Anesthesiology

The University of Minnesota reserves the right to change this schedule without notification.

Courses are held at the Center for Continuation Study or the Mayo Memorial Auditorium on the campus of the University of Minnesota. Usual tuition fees are \$45 for a two-day course, \$65 for a three-day course, and \$80 for a one-week course.

Specific announcements are sent out about two months prior to each course to all members of the Minnesota State Medical Association and to any physicians who request information for a specific course. For further information write to:

DIRECTOR
DEPARTMENT OF CONTINUATION MEDICAL EDUCATION
THE MEDICAL CENTER (BOX 193)
UNIVERSITY OF MINNESOTA
MINNEAPOLIS, MINNESOTA 55455



IN LIMITED
NUMBERS

George E. Fahr
Festschrift

A compilation of papers presented by former students and associates of Dr. George E. Fahr at a celebration in honor of his 80th birthday, Jan. 27, 1962.

Principal Authors and Titles

- George N. Aagaard, M.D., Seattle, Wash.:
The Dilemma of the Full-Time Instructor in Medicine
- Reuben Berman, M.D., Minneapolis, Minn.:
Ruptured Mitral Chordae Tendineae in Subacute Bacterial Endocarditis
- Martin S. Buehler, M.D., Dallas, Texas:
Relative Hypoglycemia: A Clinical Review of 350 Cases
- Howard B. Burchell, M.D., Rochester, Minn.:
Clinical Value of Left Axis Deviation in the Electrocardiogram: A Renaissance
- Carl M. Eklund, M.D., Hamilton, Mont.:
Natural History of Colorado Tick Fever Virus
- David L. Fingerman, M.D., Minneapolis, Minn.:
Occult Hypothyroidism with Cardiomegaly
- Robert A. Good, M.D., Minneapolis, Minn.:
The Problem of Immunological Deficiency
- Arthur C. Kerkhof, M.D., Minneapolis, Minn.:
The Changing Approach to Myocardial Infarction, 1927-1962
- Robert R. Kierland, M.D., Rochester, Minn.:
The Correlations of Dermatology and Cardiology
- John S. LaDue, M.D., New York, N. Y.:
Effect of Fibrinolytic Agents on Experimental Myocardial Infarction
- C. Walton Lillehei, M.D., Minneapolis, Minn.:
Present Status in the Treatment of Complete Heart Block with Stokes-Adams Syndrome
- Charles E. Rea, M.D., St. Paul, Minn.:
A Wonderful Year
- Howard B. Sprague, M.D., Brookline, Mass.:
George Fahr and His Era
- Harry E. Ungerleider, M.D., New York, N. Y.:
Cardiac Retrospectroscopy
- Richard L. Varco, M.D., Minneapolis, Minn.:
Hypertension Secondary to Congenital Stenosis of the Renal Artery
- Maurice B. Visscher, M.D., Minneapolis, Minn.:
The Pathophysiology of Lung Edema: A Physical and Physicochemical Problem
- Owen H. Wangensteen, M.D., Minneapolis, Minn.:
Our Teachers
- Cecil J. Watson, M.D., Minneapolis, Minn.:
The Urobilin Problem: A Partial Historical Survey and Some Recent Advances

100 pp., hard cover edition, illustrated. Price \$5.00 postpaid. Order from:
MINNESOTA MEDICAL FOUNDATION, Box 193, University Hospitals, Minneapolis 55455