

The efficacy of imiquimod 5% cream (Aldara®) in the treatment of aural plaque in horses: a pilot open-label clinical trial

Sheila M. F. Torres*, Erin D. Malone[†],
Stephen D. White[‡], Sandra N. Koch* and
Johanna L. Watson[†]

*Veterinary Clinical Sciences Department, College of Veterinary Medicine, University of Minnesota, St Paul, MN, USA

[†]Veterinary Population Medicine Department, College of Veterinary Medicine, University of Minnesota, St Paul, MN, USA

[‡]Department of Medicine and Epidemiology, School of Veterinary Medicine, University of California, Tupper Hall Davis, CA, USA
Correspondence: Sheila M. F. Torres, Department of Veterinary Clinical Sciences, College of Veterinary Medicine, C339 Veterinary Teaching Hospital, 1352 Boyd Ave., St Paul, MN 55108, USA.
E-mail: torre009@umn.edu

Part of this data was published as an abstract in *Veterinary Dermatology* 2009; 3: 216 and presented at the North American Veterinary Dermatology Forum.

Source of Funding

This project was supported by the University of Minnesota Equine Center, College of Veterinary Medicine, University of Minnesota, with funds provided by the Minnesota Racing Commission, Minnesota Agricultural Experimental Station, and contributions from private donors.

Conflict of Interest

Imiquimod was generously donated by 3M Pharmaceutical.

Abstract

Aural plaques affect at least 22% of horses and can be asymptomatic or cause ear sensitivity. Immunohistochemical and electron microscopy studies have shown a strong association between aural plaques and papilloma virus. The purpose of this study was to investigate the efficacy of imiquimod 5% cream, an immune response modifier with potent antiviral activity, in the treatment of equine aural plaques. Twenty-one horses were enrolled and 16 completed the study. Imiquimod 5% cream was applied three times a week, every other week. When both ears were affected only the worst affected ear was treated. Adverse effects in all horses included marked local inflammation, exudation and thick crust formation at the site of treatment and the adjacent skin. Removal of the crust before treatment was painful and required sedation in most horses. Complete resolution of lesions was noted in all horses immediately post-treatment and the long-term resolution rate was 87.5%. Duration of therapy ranged from 1.5 to 8 months (median: 2.9 mean: 3.5). All horses were followed-up for 12–22 months after treatment was discontinued and only two horses had a recurrence of lesions. Clinical signs related to the aural plaques prior to treatment were reported in 11 of 16 (68.8%)

horses and included resistance to touching the ears and bridling. Complete resolution of these signs was reported by the owners in all of the horses followed-up for at least 12 months. In conclusion, the topical application of imiquimod 5% cream is an efficacious treatment for aural plaques in horses.

Accepted 13 November 2009

Introduction

Aural plaques are well-delineated lesions that affect the concave aspect of the horse pinna.^{1,2} The flat surface of the plaque is typically a whitish keratinous crust covering a shiny and erythematous skin surface. Lesions are single or multiple and coalescing and, in some cases, can cover almost the entire surface of one or both pinnae.¹ There is no known sex or breed predilection and horses of any age can be affected although the disease is rarely seen in horses less than 1 year of age.^{1,2} The prevalence of aural plaques is currently unknown; however, it was diagnosed in 48 of 214 (22%) randomly examined horses in one report and in as many as 50–70% of the horses on selected ranches in Oregon.¹ Horses can be asymptomatic or present with moderate head shaking or signs of hypersensitivity around the ears and head.^{1,2} Biting flies, especially black flies, are reported to aggravate the symptoms.^{1–3}

Histopathologically, aural plaques have features consistent with papilloma virus infection, such as papillated epidermal hyperplasia, koilocytosis, and increased number and size of keratohyalin granules.⁴ In 1992, Fairley and Haines performed electron microscopic studies on aural plaque tissues and found arrays of intranuclear crystalline, hexagonal viral particles of approximately 38–42 nm in diameter that were characteristic for papilloma virus.⁴ Moreover, the authors were able to demonstrate the presence of papilloma virus immunohistochemically in aural plaque tissues of all four tested horses using an antibody that recognizes group-specific antigens.⁴ A more recent study also found immunohistologic evidence of a papilloma virus associated with aural plaques but no molecular evidence of equine papillomavirus type 1 (EPV).⁵ These findings indicate that a papilloma virus is associated with aural plaques in horses and suggest that it is the causative agent of this disorder.

Aural plaques are not known to spontaneously regress. Reports of treatment options for aural plaques and their efficacy are few and all anecdotal.^{1,2} Little or no improvement has been reported from topical application of

corticosteroid and antibiotic preparations.¹ The response to topical application of tretinoin (Retin-A® 0.025%, 0.05%, 0.1% cream; 0.01%, 0.025% gel; Ortho Dermatologics; Los Angeles, CA, USA) has been variable.² Imiquimod and eastern blood root in zinc chloride have also been anecdotally reported as treatment modalities for aural plaques but without mention of their efficacy.²

Imiquimod is a synthetic imidazoquinoline amine-based immune response modifier, with potent antiviral and antitumour activity in animal models and humans.^{6,7} The antiviral and antitumour effects are primarily due to activation of Toll-like receptor (TLR) 7 resulting in the transcription of various genes encoding cytokines [e.g. interferon (IFN)- α] and other effector molecules of the innate and adaptive immune responses.⁸ Imiquimod has been used with good efficacy in the treatment of human external genital/perianal warts and equine sarcoids, diseases also caused by or associated with a papilloma virus.^{6,9,10} In addition, studies performed in humans have shown that imiquimod 5% cream is beneficial for the treatment of other cutaneous viral infections such as molluscum contagiosum and for skin tumours such as basal cell carcinoma, actinic keratosis and squamous cell carcinoma *in situ*.^{11–14} The antiviral effects of imiquimod and its very good efficacy in the treatment of virus-associated skin diseases in humans and horses justifies further investigation of this drug as a treatment modality for horses with aural plaques. The objective of this study was to evaluate the efficacy of topical imiquimod 5% cream (Aldara™; 3M Pharmaceuticals, Minnetonka, MN, USA) in the treatment of equine aural plaque.

Materials and methods

Inclusion criteria

The study population consisted of otherwise clinically healthy horses of any age, sex, or breed with aural plaques that had not been previously treated, or had been treated but the lesions had not resolved or had recurred. Diagnosis of aural plaques was based on the clinical appearance of the lesions and characteristic histopathological findings such as papillated epidermal hyperplasia, hypomelanosis, koilocytosis, and/or increased number and size of keratohyalin granules.⁴ Owners were required to provide written informed consent and were advised of their right to withdraw from the trial at any time.

Horses were excluded from the study if they had received any previous treatment with imiquimod, interferon, retinoids, glucocorticoids, cytotoxic drugs, and/or surgical therapy within 4 weeks prior to entering the study. Owners were not allowed to include their horses in the study if they expressed concerns of being able to follow the study protocol for any reason. The study was approved by the University of Minnesota and University of Davis Institutional Animal Care and Use Committees.

Study design

The study was conducted as a pilot open-label clinical trial.

Study protocol

Horses were evaluated by the investigators at the first visit at which a thorough history, complete physical examination, detailed description of lesions, and skin biopsy were obtained. Horses were then reevaluated every four to 6 weeks for the duration of the study.

Owners were instructed to apply a thin layer (enough to cover the lesion) of imiquimod 5% cream to the aural plaques three times a week (on nonconsecutive days) every other week (i.e. six treatments per month). Horses with bilateral aural plaques had the

most extensively affected ear selected for treatment. Most owners used one packet (0.25 g) per ear during each treatment. Immediately before each application of imiquimod, owners were advised to use a gauze sponge soaked in water to remove the tightly adhered crust formed as a result of the inflammatory reaction induced by the drug. No attempt was made to remove the cream or crusts between treatment times. If owners were unable to remove the crusts and/or apply the medication using physical restraint (e.g. neck or nose twitch), a sedative was prescribed to be administered by the owner before each treatment. Initially, a mild sedation protocol of acepromazine (Boehringer Ingelheim; Vet Medica Inc., St. Joseph, MO, USA) at 0.04 mg/kg intramuscularly (i.m.) and xylazine (Lloyd Laboratories, Shenandoah, IA, USA) at 0.5–0.7 mg/kg i.m. was prescribed. Owners that could treat intravenously (i.v.) or that had veterinary assistance gave lower doses i.v. At the following reevaluation visit, if the owner complained that the sedation did not work well, the sedative protocol was altered to detomidine (Pfizer Animal Health, New York, NY, USA) at 0.01–0.02 mg/kg and/or butorphanol (Fort Dodge Animal Health, Overland Park, KS, USA) at 0.01–0.02 mg/kg.

Investigator assessment of treatment efficacy

At each visit, the horses were sedated (0.3–0.6 mg/kg xylazine or 0.01 mg/kg detomidine i.v., usually combined with 0.01 mg/kg butorphanol i.v.) and the treated ear was carefully evaluated by the same investigator for response to treatment. After removal of the tightly adhered crust, the treated area was described in detail and digital pictures were taken. Treatment was considered successful if the lesions resolved completely. Treatment was considered failed if lack of further response was determined in two consecutive visits (i.e. no significant reduction in lesion size and number after 12 applications of imiquimod in a period of two consecutive months). In many cases, the investigator had to interrupt treatment and reevaluate the horse in 4–6 weeks to assure that the lesions had resolved because the severe inflammation induced by the drug impeded accurate assessment of treatment response.

Owners' perception of treatment efficacy

At the end of the study, the owners rated their perception of treatment efficacy as 'none', 'poor', 'good' or 'excellent'. Owners were also asked if they considered imiquimod cream a good treatment option for aural plaque and if they would re-treat their horses in case of recurrence.

Owner compliance and assessment of drug side effects

Owner compliance with treatment protocol was evaluated by comparing the number of imiquimod packets dispensed with the number returned by the owner at each visit. Compliance was considered satisfactory if at least 90% of the treatments were administered. Severity of skin reactions (e.g. erythema, depigmentation, oedema, erosion, ulceration, scaling, exudation, crusting) at the treated and/or adjacent site was recorded by the same investigator at each visit and by the owner on days of treatment. If the severity of local skin reactions warranted treatment interruption due to substantial discomfort, a rest period of 2 weeks (i.e. 1 week of treatment discontinuation) or reduction in frequency of drug application (i.e. twice instead of three times a week) was allowed. At the end of the study, owners were asked to report the main concerns associated with treatment.

Withdrawal criteria

Criteria that justified immediate withdrawal of horses from the trial included development of unacceptable adverse drug effects that did not subside after discontinuing treatment for one treatment cycle (i.e. two consecutive weeks without treatment), owner desire to withdraw their horses, lack of owner compliance with treatment protocol or evaluation visits, and development of concurrent diseases that could interfere with treatment application or evaluation.

Follow-up

Horses that had complete resolution of the aural plaques were evaluated by the investigators at least 1 year post-treatment discontinuation to determine recurrence of lesions and any lasting side effect associated with treatment.

Results

Characteristic of the horses included in the study

Twenty-one horses diagnosed with aural plaques between June of 2006 and October of 2007, were included in the study. Of these, 17 were client-owned horses recruited at the Veterinary Medical Center of the University of Minnesota and four were teaching horses housed at the School of Veterinary Medicine at the University of Davis. There were 13 mares, seven geldings and one stallion represented by 18 purebred and three mixed breed horses. The mean age of the horses at the time of enrolment was 13.9 years (range: 3–28 years) and the duration of aural plaques as reported by the owners ranged from 1 month to more than 10 years. Fifteen horses had both ears affected, four had only the right ear and two horses had only the left ear affected. Owners reported ear sensitivity in 16 of the affected horses and this included reluctance to bridling and touching the head/ear. Fourteen horses received no treatment for aural plaques prior to enrolment and seven horses were treated topically with one or more of the following: bloodroot extract (Bloodroot Extract; Herb Pharm, Williams, OR, USA), tea tree oil, hydrocortisone cream, petroleum jelly (Vaseline®; Unilever, Greenwich, CT, USA), an antifungal, antibiotic, glucocorticoid cream (Otomax®; Schering-Plough Animal Health, Whitehouse Station, NJ, USA), or lesion scraping. Table 1 shows the demographic information of each horse enrolled in the study.

Treatment outcome

Five of the 21 horses were withdrawn from the study for the following reasons: one horse was lost to follow-up; three horses could not be treated by the owner and one horse due to study protocol deviation. Complete resolution of aural plaques was noted in all 16 horses that completed the study (Figure 1). Treatment duration ranged from 1.5 to 8 months (median: 2.9 months; mean: 3.5 months). Ten horses (63%) needed sedation before each treatment and six horses (including the four teaching horses) only required physical restraint. After resolution, owners reported a decrease in ear sensitivity in all horses, including easier bridling and less sensitivity to touching of the head or ears.

Owners' perception of treatment efficacy

All owners rated treatment efficacy as excellent. Ten of 12 owners (all four teaching horses were excluded to avoid bias) felt that imiquimod cream was a good treatment option for aural plaques and two owners were unsure because of the discomfort experienced by the horses and the difficulty in treating the ears. The same 10 owners would re-treat the horses' ears if lesions recurred and the same two would not.

Owner compliance and assessment of drug adverse effects

Owner compliance was considered satisfactory in all cases. As expected, all horses developed adverse effects during treatment applications at both treated and adjacent skin sites. Adverse effects included erythema, oedema, erosion to ulceration, exudation and crusting (Figure 2). Adverse effects noted after discontinuation of therapy were alopecia, depigmentation and scaling. None of the

Table 1. Demographic information of the 22 horses with aural plaque included in the study

Case	Breed	Age (years)	Disease duration	Sex	Ear(s) affected	Reason for treatment	Previous treatment	Response to treatment
1	Quarter horse	7	1 month	Mare	Right	Cosmetic	No	NA
2	Arabian	16	>10 years	Mare	Right	Ear sensitivity	Scraped ear	No
3	Tennessee walking	7	>7.5 years	Gelding	Both	Ear sensitivity	No	NA
4	Thoroughbred	18	>7 years	Gelding	Right	Ear sensitivity	No	NA
5	Spanial Mustang	13	>7 years	Gelding	Both	Ear sensitivity	X-Terra, scraped, Limisol spray	No
6	Tennessee walking	17	>10 years	Mare	Both	Ear sensitivity	Antifungal, laser, antibiotic	No
7	Tennessee walking	13	3 years	Mare	Both	Ear sensitivity	Iodine	No
8	Fjord	10	>6 years	Mare	Both	Ear sensitivity	No	NA
9	American saddle bred	13	>1 year	Mare	Both	Ear sensitivity	No	NA
10	Thoroughbred	23	>10 years	Gelding	Both	Ear sensitivity	Scraped ear	No
11	Arabian	24	1 year	Mare	Both	Ear sensitivity	No	NA
12	Mixed	4	1.5 years	Mare	Both	Ear sensitivity	No	No
13	Missouri fox trotter	12	>8 years	Gelding	Both	Ear sensitivity	No	No
14	Mixed	18	8 years	Mare	Both	Ear sensitivity	Vaseline; tea tree oil, hydrocortisone cream	No
15	Mixed	6	3 years	Gelding	Both	Ear sensitivity	None	NA
16	American paint horse	3	1 month	Stallion	Both	Ear sensitivity	Otomax®	No
17	American paint horse	7	1 year	Mare	Both	Ear sensitivity	No	NA
18	Quarter horse	11	Unknown	Mare	Left	Cosmetic	No	NA
19	Standardbred	20	Unknown	Mare	Left	Cosmetic	No	NA
20	Thoroughbred	23	Unknown	Gelding	Both	Cosmetic	No	NA
21	Appaloosa	28	Unknown	Mare	Right	Cosmetic	No	NA

NA, not applicable.

horses in the study became head shy after treatment. Owners' main concerns associated with imiquimod therapy were difficulty with treatment, requiring sedation and/or physical restraint, and the discomfort experienced by the horse during treatment.

Follow-up

All 16 horses were evaluated by the investigators 12–22 months after remission. Two horses had recurrence of aural plaques and the owners decided not to re-treat the lesions. One owner did not treat due to personal issues and the other because the lesion was asymptomatic and the difficulties and discomfort associated with treatment outweighed the benefits of treating. After treatment was discontinued, all horses regrew hair to fully cover the concave aspect of the pinna. Only four horses had small focal areas of post-inflammatory depigmentation.

Discussion

The study results showed that imiquimod 5% cream is very effective in the treatment of equine aural plaques, with all 16 horses that completed the trial having apparent complete resolution of lesions with cosmetic results. In addition, this study provides evidence that aural plaques do cause ear sensitivity in horses as horses improved in ease of bridling and sensitivity to touch after resolution of the plaques, despite the inflammation associated with treatment.

The treatment protocol adopted in this study allowed for 7 days without drug application. In a study using imiquimod to treat equine sarcoids, treatment was administered every week.⁹ For this study, the three treatments per week on a week on week off basis was considered necessary to reduce the inflammation and discomfort associated with treatment and to facilitate the application of the cream by the owners, particularly due to the ear sensitivity often reported with aural plaques.

The range of imiquimod treatment duration before lesion resolution was broad, with one case being treated for only one and half months (i.e. nine treatments) and another 8 months (i.e. about 48 treatments). The investigators observed that duration of therapy was not directly related with the extent of lesions but to owners' dedication in applying the cream. Lesions resolved faster when owners thoroughly removed the crusts before each application and applied the cream to all affected areas. Slower response was noted when owners reported more difficulty with cleaning and treatment.

Systemic absorption of imiquimod in humans has been reported to be negligible.^{15,16} Treatment had no effect on the aural plaques (if present) on the nontreated ear and no systemic signs were noted in the horses. Horses did not seem to be affected by treatment except during the cleaning process.

As a result of the severe inflammatory reaction induced by imiquimod, the administration of the cream was not an easy task and most horses required sedation before each

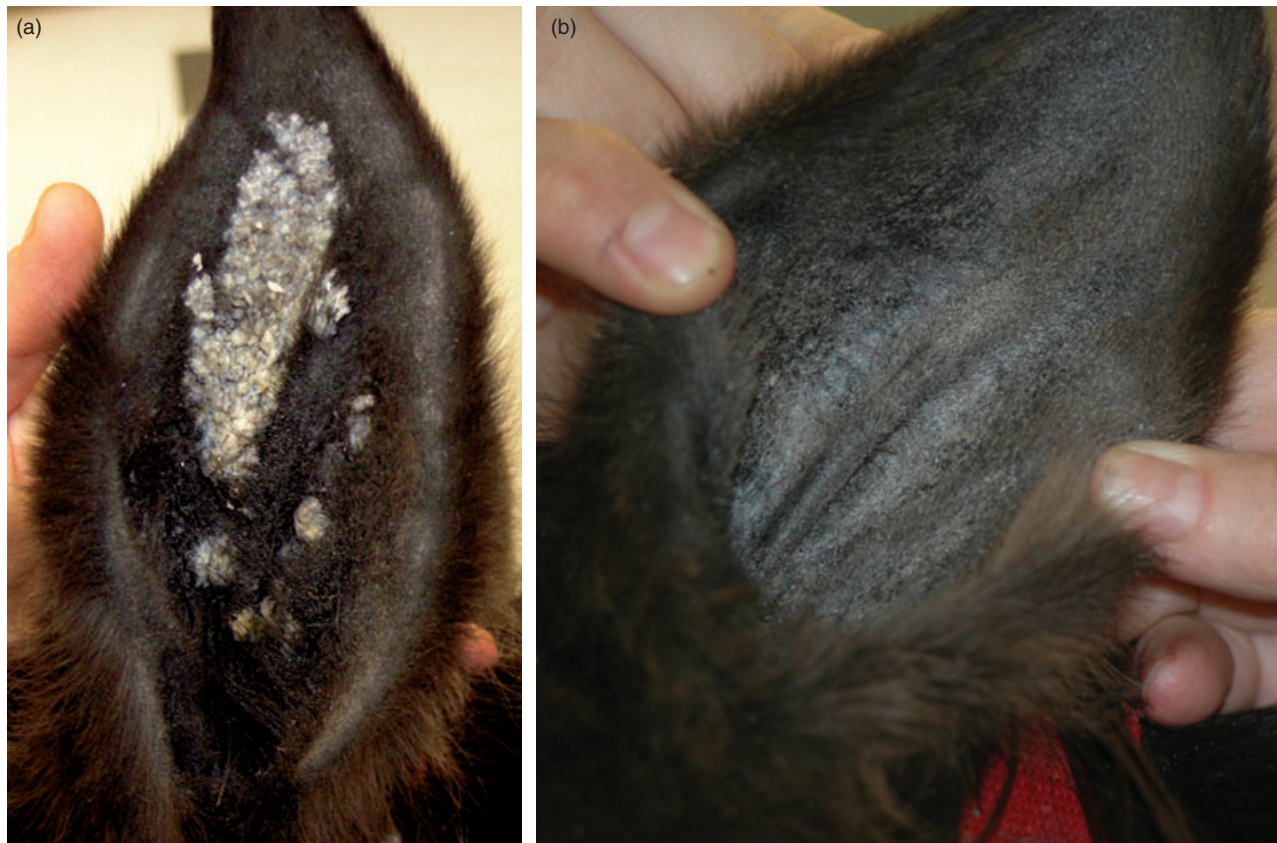

Figure 1. (a) Coalescing plaques covered with a whitish keratinous crust occupying most of the concave aspect of the horse's pinna; (b) complete resolution of plaques after treatment with imiquimod 5% cream.

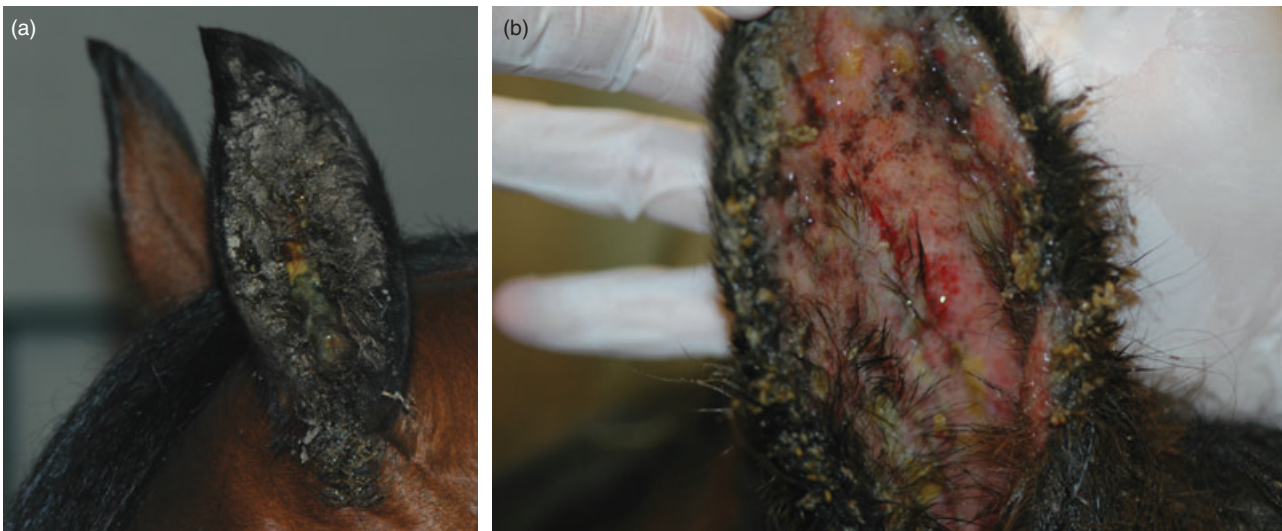


Figure 2. Side effects associated with application of imiquimod 5% cream to aural plaque lesions in horses. (a) Thick and tightly adhered crust formed after application of imiquimod 5% cream; (b) The skin underneath the crust is oedematous and eroded to ulcerated.

treatment. The difficulty in treating ears and having to sedate the horses frequently were the primary concerns reported by the owners. This caveat should be carefully discussed with owners before offering imiquimod as a treatment option for aural plaques in horses. The investigators do not recommend treatment unless the horses are demonstrating ear sensitivity. Despite the severe inflammatory reaction, the only noticeable change was focal areas of post-inflammatory depigmentation in four horses.

Lesions recurred in two (12.5%) horses. In one horse, lesions were noted 13.5 months and in the other horse 17 months after remission, indicating that long-term follow up is important before declaring the condition cured. However, it is possible that the lesions recurred earlier and were not noted by owners due to hair coverage. It is also possible that the lesions never fully resolved in these two horses. At follow-up visits four to 6 weeks after discontinuing therapy, minute depigmented macules were noted in both horses and were attributed to post-inflammatory depigmentation, but could have been early or persistent plaques.

The owners of seven of the 11 horses with bilateral aural plaques that completed the study elected to treat the opposite ear. The treatment protocol was adjusted to twice weekly, every other week in all of these horses with complete resolution achieved in all cases despite the less frequent treatment.

In summary, imiquimod 5% cream was an efficacious treatment for equine aural plaques with minimal to no permanent adverse effects. Application of the cream was difficult because of the location of the lesions and the severe inflammatory reaction induced by imiquimod. Owners' dedication to treat the lesions influenced duration of therapy and outcome and veterinarian involvement was essential in most cases. Our current recommendation is to treat twice weekly every other week and only if ear sensitivity due to the aural plaques is interfering with usage of the horse (difficulty in bridling, etc.). Frequent and long-term follow-up evaluations are important to

determine whether or not lesions have fully resolved and/or recurred.

References

1. Binninger CE, Piper RC. Hyperplastic dermatitis of equine ear. *Journal of the American Animal Medical Association* 1968; 153: 69–75.
2. Scott DW, Miller WR. Neoplastic and non-neoplastic tumors. *Equine Dermatology*. Philadelphia, W.B. Saunders, 2003: 700–7.
3. Williams MA. Papillomatosis: warts and aural plaques. In: Robinson ME, ed. *Current Therapy in Equine Medicine IV*. Philadelphia, W.B. Saunders, 1997: 389.
4. Fairley RA, Haines DM. The electron microscopic and immunohistochemical demonstration of a papillomavirus in equine aural plaques. *Veterinary Pathology* 1992; 29: 70–81.
5. Postey RC, Appleyard GD, Kidney BA. Evaluation of equine papillomas, aural plaques, and sarcoids for the presence of equine papillomavirus DNA and papillomavirus antigen. *Canadian Journal of Veterinary Research* 2007; 71: 28–33.
6. Gollnick H, Barasso R, Jappe U *et al.* Safety and efficacy of 5% imiquimod cream in the treatment of penile genital warts in uncircumcised men when applied three times weekly or once per day. *International Journal of STD & AIDS* 2001; 12: 22–8.
7. Beutner KR, Tying SK, Trofatter JR *et al.* Imiquimod, a patient-applied immune-response modifier for treatment of external genital warts. *Antimicrobial Agents and Chemotherapy* 1998; 42: 789–94.
8. Stary G, Bangert C, Tauber M *et al.* Tumoricidal activity of TLR7/8-activated inflammatory dendritic cells. *Journal of Experimental Medicine* 2007; 204: 1441–51.
9. Nogueira SAF, Torres SMF, Malone ED *et al.* Efficacy of imiquimod 5% cream in the treatment of equine sarcoids: a pilot study. *Veterinary Dermatology* 2006; 17: 259–65.
10. Carr EA, Theon AP, Madewell BR *et al.* Bovine papillomavirus DNA in neoplastic and nonneoplastic tissues obtained from horses with and without sarcoids in the western United States. *American Journal of Veterinary Research* 2001; 62: 741–4.
11. Berman B, Hengge U, Barton S. Successful management of viral infections and other dermatoses with imiquimod 5% cream. *Acta Dermatologica-Venereologica* 2003; Suppl. 214: 12–7.

12. Nouri K, O'Connell C, Rivas MP. Imiquimod for the treatment of Bowen's disease and invasive squamous cell carcinoma. *Journal of Drugs in Dermatology* 2003; 2: 669–73.
13. Orengo I, Rosen T, Guill CK. Treatment of squamous cell carcinoma in situ of the penis with 5% imiquimod cream: a case report. *Journal of the American Academy of Dermatology* 2002; 47: S225–8.
14. Schroeder TL, Sengelman RD. Squamous cell carcinoma in situ of the penis successfully treated with imiquimod 5% cream. *Journal of the American Academy of Dermatology* 2002; 46: 545–8.
15. Myhre PE, Levy ML, Eichenfield LF *et al.* Pharmacokinetics and safety of imiquimod 5% cream in the treatment of molluscum contagiosum in children. *Pediatric Dermatology* 2008; 1: 88–95.
16. Harrison LI, Skinner SL, Marbury TC *et al.* Pharmacokinetics and safety of imiquimod 5% cream in the treatment of actinic keratosis of the face, scalp, or hands and arms. *Archives of Dermatological Research* 2004; 296: 6–11.

Résumé Les plaques auriculaires affectent au moins 22% des chevaux et peuvent être asymptomatiques ou créer une sensibilité de l'oreille. Les études immunohistochimiques et de microscopie électronique ont montré une forte association entre plaques auriculaires et papilloma virus. L'objectif de cette étude était d'évaluer l'efficacité de l'imiquimod crème 5%, immunomodulateur avec activité antivirale potentielle, dans le traitement des plaques auriculaires équine. Vingt et un chevaux ont été inclus et seize ont finalisés l'étude. L'imiquimod crème 5% était appliquée trois fois par semaine, une semaine sur deux. Lorsque les deux oreilles étaient atteintes, seule la plus affectée était traitée. Les effets secondaires chez tous les chevaux regroupaient une inflammation locale marquée, de l'exsudat et la formation d'une croûte épaisse sur les zones traitées et la peau adjacente. Le retrait de la croûte avant traitement était douloureux et a justifié une sédation de la plupart des chevaux. Une amélioration complète des lésions a été notée chez tous les chevaux immédiatement après le traitement et l'amélioration à long-terme était de 87,5%. La durée du traitement variait de 1,5 à 8 mois (médiane : 2,9; moyenne : 3,5). Tous les chevaux ont été suivis 12 à 22 mois après l'arrêt du traitement et seuls deux d'entre eux ont montré une récurrence des lésions. Les signes cliniques liés aux plaques auriculaires avant traitement ont été rapportés dans 11 sur 16 cas (68,8%) et regroupaient une sensibilité des oreilles au toucher et aux brides. Une complète résolution de ces signes a été rapportée par les propriétaires de tous les chevaux suivis au moins 12 mois. En conclusion, l'application topique de l'imiquimod crème 5% est un traitement efficace des plaques auriculaires équine.

Resumen Las placas aurales afectan las menos a un 22% de caballos y pueden ser asintomáticas o causar sensibilidad de la oreja. Estudios de inmunohistoquímica y de microscopía electrónica han demostrado una asociación importante entre la presencia de placas aurales y el virus papiloma. El propósito de este estudio fue investigar la eficacia de crema de 5% de imiquimod, un modificador de la respuesta inmune con potente actividad antivírica, en el tratamiento de las placas aurales en equinos. Se incluyeron 21 caballos y 16 completaron el estudio. Se aplicó crema al 5% de imiquimod tres veces en semana en semanas alternas. Cuando ambas orejas estaban afectadas sólo se trató la de mayor severidad. Efectos adversos detectados en todos los caballos incluyeron inflamación local severa, exudado y formación de costras gruesas en la zona de tratamiento y piel adyacente. La retirada de la costra antes del tratamiento fue dolorosa y requería sedación de la mayoría de los caballos. La resolución completa de las lesiones fue observada en todos los caballos tras el tratamiento y el índice de curación a largo plazo fue del 87,5%. La duración del tratamiento vario entre 1,5 y 8 meses (mediana 2,9; media 3,5). Todos los caballos fueron observados durante 12-22 meses tras la interrupción del tratamiento y sólo dos caballos presentaron lesiones recurrentes. Signos clínicos asociados con las placas aurales antes del tratamiento fueron observados en 11 de 16 caballos (68,8%) e incluyeron resistencia a la palpación y a poner el arnés. Se observó resolución de estos signos clínicos reportada por los propietarios en todos los caballos a los que se hizo un seguimiento durante al menos 12 meses. Se concluye que la aplicación tópica de una crema de 5% de imiquimod es un tratamiento eficaz para las placas de las orejas en caballos.

Zusammenfassung Aurale Plaques kommen bei 22% der Pferde vor und können asymptomatisch sein oder eine Sensibilität der Ohren bedingen. Immunhistochemische und elektronenmikroskopische Studien haben einen starken Zusammenhang zwischen auralen Plaques und Papillomavirus gezeigt. Das Ziel dieser Studie war es, die Wirksamkeit von Imiquimod 5% Creme, einem Modifizierer der Immunantwort mit potenter antiviraler Aktivität, bei der Behandlung der auralen Plaques von Pferden zu untersuchen. Einundzwanzig Pferde wurden in die Studie aufgenommen, 16 beendeten die Studie. Imiquimod 5% Creme wurde jede zweite Woche dreimal pro Woche aufgetragen. Wenn beide Ohren betroffen waren, wurde nur das schlimmere behandelt. Bei allen Pferden traten Nebenwirkungen auf, die aus deutlicher lokaler Entzündung, Exsudation und dicker Krustenbildung an der behandelten Stelle und an der angrenzenden Haut bestanden. Die Entfernung der Kruste vor der Behandlung war schmerzhaft und machte eine Sedierung der Pferde nötig. Eine gänzliche Abheilung der Läsionen wurde bei allen Pferden sofort nach der Behandlung festgestellt und die langfristige Abheilungsrate lag bei 87,5%. Die Dauer der Therapie lag zwischen 1,5 und 8 Monaten (Medianwert: 2,9, Durchschnittswert: 3,5). Nach beendeter Behandlung wurden alle Pferde für 12 bis 22 Monate weiterverfolgt, wobei nur zwei Pferde ein Wiederauftreten der Läsionen zeigten. Kli-

nische Zeichen, die mit den auralen Plaques in Zusammenhang standen, wurden bei 11 der 16 (68,8%) Pferde beschrieben und bestanden aus einem Widerstand gegenüber der Berührung der Ohren und dem Aufzäumen. Ein vollständiges Verschwinden dieser Anzeichen wurde von allen BesitzerInnen der Pferde beschrieben, die für mindestens 12 Monate weiterverfolgt wurden. Zusammenfassend kann man sagen, dass die topische Applikation von Imiquimod 5% Creme eine wirksame Behandlung für aurale Plaques bei Pferden darstellt.