

Title: Screening for Colorectal Cancer: Colonoscopy vs. Sigmoidoscopy plus Fecal Blood Tests

Author: William Allen, MS4

Date: 7/15/2009


Key words: Colorectal Cancer, Cancer Screening, Colonoscopy, Sigmoidoscopy, Fecal Occult Blood Tests

Abstract: Colorectal cancer screening has many different modalities. Two of the most effective modalities are sigmoidoscopy combined with fecal occult blood tests and colonoscopy. This article will explain these tests and their benefits.

This document was created by a medical student enrolled in the Primary Care Clerkship at the University of Minnesota Medical School as part of the course project. The aim of the project is to present information on a medical topic in the format of a patient education handout. It does not necessarily reflect the views of the University of Minnesota Medical School physicians and faculty. These materials are provided for informational purposes only and are in no way intended to take the place of the advice and recommendations of your personal health care provider. The information provided may no longer be up to date since it has not been reviewed since the date of creation. The information provided should not be used to diagnose a health problem or disease, or as a means of determining treatment. In the event of a medical emergency, immediately contact a doctor or call 911.

Testing for Colorectal Cancer

A Patient's Guide to Colonoscopy and Sigmoidoscopy

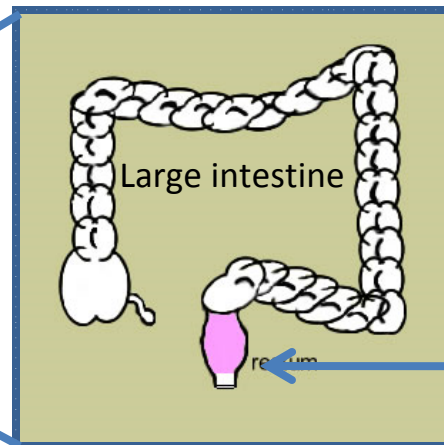
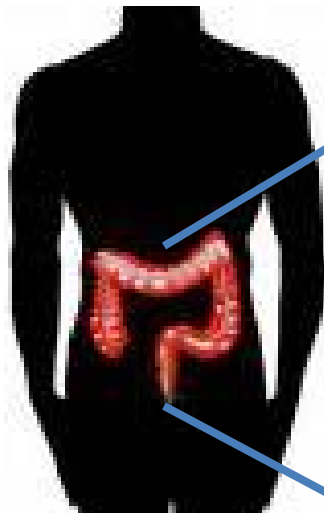


➤ Definition of Colorectal cancer.

The colon is also known as the large intestine.

The rectum is the last 3-4 inches of the digestive tract before stool leaves the body.

Colorectal cancer occurs when cells on the inside of the colon or the rectum begin to multiply and grow. These cells then begin to form a mass called a "tumor."



➤ Why Screen for Colorectal Cancer?

1 in 19 men will be diagnosed with colorectal cancer in their lifetime.

Similarly, 1 in 19 women will be diagnosed with colorectal cancer during their lifetime.

If colorectal cancer is found early, it can be removed and prevent serious disease.

➤ How do you test for Colorectal Cancer?

There are many different tests that look for colorectal cancer. Some tests are good at finding cancer, while others are bad at finding cancer. Two of the better tests are considered below.

Sigmoidoscopy combined with Fecal Occult Blood Tests

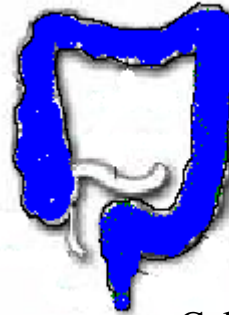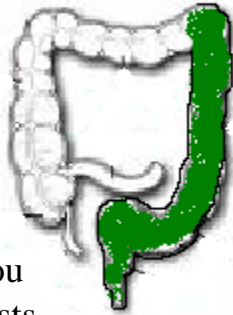
Colonoscopy

Sigmoidoscopy is a test where the doctor put a small camera in the rectum to look at the inside of the rectum and the colon. This exam can only see the last third of the colon.

Fecal occult blood tests can find blood in your poop even though you may not be able to see it. These tests require you to give a small sample of feces to the doctor for testing.

These two tests, in combination, are fairly good at finding colorectal cancer. If you have colorectal cancer, your doctor will have a 76% chance of finding it using these two tests.

The risk of punching a hole in your colon during this procedure is 1 out of 10,000.



Colonoscopy is an exam where the doctor gives the patient some medicine for sedation. The doctor then puts a camera into the rectum to look at the inside of the rectum and the entire colon for bulges that may suggest a cancer is growing.

Colonoscopy is a good exam to rule out colorectal cancer. If a patient has a colonoscopy and the doctor does not see bulges, the patient has very little chance of having cancer.

The risk of punching a hole in your colon during this procedure is 1 out of 500 to 1000.

Recommendations

The United States Preventative Services Task Force recommends that patients who are older than 50 receive either fecal occult blood tests yearly, sigmoidoscopy every 5 years, or a colonoscopy every 10 years to look for colorectal cancer. Ask your doctor about which options are best for you.

References: www.cancer.gov; Pignone et al. Screening for Colorectal Cancer in Adults at Average Risk: A Summary of the Evidence for the U.S. Preventative Services Task Force. *Annals of Internal Medicine*, 2002; Vol 137, Iss 2; 132-141

Images: media.lvrj.com; coloncancer.about.com