

THE UNIVERSITY OF MINNESOTA

GRADUATE SCHOOL

Report

of
Committee on Examination

This is to certify that we the undersigned, as a committee of the Graduate School, have given James Martin Hayes final oral examination for the degree of Master of Science in ^{Surgery} We recommend that the degree of Master of Science be conferred upon the candidate.

Minneapolis, Minnesota

May 23 1911

A. P. Shadower
Chairman

W. F. Boasch

R. D. Mosey

J. A. Hunt

W. S. Henderson

REPORT
of
Committee on Thesis

The undersigned, acting as a Committee of the Graduate School, have read the accompanying thesis submitted by James Martin Hayes for the degree of Master of Science in Surgery. They approve it as a thesis meeting the requirements of the Graduate School of the University of Minnesota, and recommend that it be accepted in partial fulfillment of the requirements for the degree of Master of Science in Surgery.

Charles Horace Mayo
Chairman

Arthur H. Hagan

A. T. Broders

18 583 | ..

THESIS

The Lymph Glandular Involvement in Carcinoma
of the Large Intestine.

James Martin Hayes.

Submitted to the Graduate Faculty of
the University of Minnesota in partial
fulfillment of the requirements for the
Degree of Master of Science in Surgery.

April 1921.

MOM
GH3RR
8

Table of Contents.

Chapter I Introduction.
Anatomy of the Large Intestine-----page 1.
Carcinoma of the Large Intestine-----page 8.

Chapter II Materials and Methods-----page 13.

Chapter III Results-----page 15.
Group I- Cases without Glandular Involvement--page 17.
Group II-Cases with Glandular Involvement-----page 51.
Group III-A-Cases with Colloid Carcinoma without
Glandular Involvement-----page 72.
Group III-B-Cases with Colloid Carcinoma with
Glandular Involvement-----page 74.

Chapter IV Summary and Conclusions-----page 97.
Bibliography-----page 101.

OCT 6 '28 134 1.35.

290307

THE LYMPH GLANDULAR INVOLVEMENT IN
CARCINOMA OF THE LARGE INTESTINE.

The work of MacCarty and Blackford on the Involvement of Regional Lymphatic Glands in Carcinoma of the Stomach, and of McVay on The Lymph Glandular Involvement in Carcinoma of the Rectum, suggested the study of The Lymph Glandular Involvement in Carcinoma of the Large Intestine, as next to the above mentioned the large intestine is the most common site of carcinoma along the alimentary tract.

This same study of the caecum is being taken up by Powell at the present time so that all discussion of this part of the large intestine is purposely omitted in this paper.

ANATOMY OF THE LARGE INTESTINE

A brief review of the anatomy, especially of the blood and lymph supply will help us to better understand the glandular distribution and consequently the reason for early or delayed metastasis in carcinoma of the large intestine.

Embriologically the alimentary tract, an endodermal canal from the stomach to the anus, is a simple tube with only the yolk sac and allantois diverticulum attached to its ventral side up to the time the embryo reaches a length of 12mm. At this stage a small diverticulum appears which marks the anlage of the caecum. The canal on the caudal side of this increases in diameter and length, and forms the large intestine. From this point a loop forms which

extends anteriorly. At about the eleventh week of foetal life, the large intestine begins to rotate to the right so as to cross the body in front of the small intestine, bringing the caecum in front of the small intestine and toward the hepatic flexure. This rotation is usually not entirely complete until after birth. It may be arrested at any stage in the process of this rotation, thus accounting for the anomalous position of the caecum frequently found in the adult. During this rotation the mesentery remains attached along the median dorsal line and elongates to accommodate the position of the intestine.

In its final location we have the mesentery on the inner border containing the blood vessels, lymphatics and sympathetic ganglia, while the outer leaf is merely a peritoneal attachment to the posterior abdominal wall and carries no important structures. Mayo calls attention to one exception to this last mentioned condition. He states that at the splenic flexure, the outer leaf carries a vessel derived from the omentum, which should be reckoned with in surgery of this part of the intestine. The pelvic colon retains its primitive mesentery and consequently remains freely movable.

As the stomach rotates into its adult position the lower part of the gastric mesentery folds on itself, making a double mesentery which hangs down as a sac. As this sac passes down over the transverse colon its posterior leaf fuses with the anterior leaf of the meso-colon thus forming the gastro colic omentum. This continues down over the colon and becomes the great omentum. The large intestine, then, in its usual adult position, begins in the right iliac fossa and is subdivided into the caecum, a blind pouch and the colon, which is ascending in the right flank, transverse across the middle of the abdomen, and descending on the left. This is followed at the crest of the ileum by the sigmoid flexure, a free fold attached to the left of the pelvis,

usually recorded as a part of the colon, which after crossing the left sacroiliac joint, descends into the hollow of the sacrum to become the rectum at the middle of the third sacral vertebra.

It is usually distinguished from the small intestine, not so much by its larger size as by being sacculated, excepting perhaps the sigmoid flexure.

The length of the large intestine, from the root of the appendix to the beginning of the rectum is according to Treves about 1.4 meters in man and 5 cms. less in woman. The extremes were 2 meters and one m. Excluding the dilated part of the rectum, the capacity decreases from above downward. Owing both to variation and to occasional cases of extreme contraction, as well as distention, the diameter is very uncertain. It may vary from 3.5 cms. to 7 cm without the more extreme figures implying a pathological condition.

The transverse colon is suspended between its beginning, the hepatic flexure, and its end the splenic flexure, like a festoon, forward and downward, for the ends are near the back of the abdominal cavity. The splenic flexure, in front of the lower part of the spleen, is both higher and more posterior than the hepatic one. Thus the intermediate part of the transverse colon may take a horizontal position or the center may hang down even to rest in the pelvis. The sigmoid flexure varies in length from 25 cm to 56 cm but is occasionally much longer. It does not always become free at the crest of the ileum but may descend bound down closely to the iliac fossa for some distance, but this point is taken as the beginning of the sigmoid rather than the more uncertain one at which the gut really has a mesentery. The simplest form of the sigmoid is a loop but it may present the most diverse forms, so that a definite shape can hardly be assumed. With increased lengths, the M-form is the most common. It has been found, disposed in three parallel vertical folds, occupying

all of the left iliac fossa and over-hanging the true pelvis. As the sigmoid flexure descends along the sacrum, it usually curves to the right.

The three bands of the colon or taenia coli, formed by accumulations of longitudinal fibres, are each about one cm. broad. Their disposition in the walls of the gut are not constant but the following arrangement is the most usual. In the ascending colon, one is in front and two behind, one of the latter being near the outer and the other near the inner aspect. On reaching the transverse colon the anterior becomes the inferior while the external becomes the superior receiving the attachment of the transverse meso-colon. The internal also is on the upper surface, but behind the preceding. On the descending they tend to resume their original position but tend to grow indistinct. They are still more so in the sigmoid flexure, and before the rectum is reached, there are but two bands, an anterior and a posterior, of which the latter is the stronger.

The mucous coat of the large intestine consists of a stroma resembling adenoid tissue, covered by a single layer of columnar epithelium, exhibiting a cuticular border. It differs from that of the small intestine, chiefly in not having villi, in consequence of which the velvety appearance imparted by the latter, is not seen in the large intestine. Stohr found villi present in the first half of the large intestine, corresponding with those of the small intestine, up to the fifth month of foetal life. This would seem to be in accord with the fact that the proximal part of the large intestine as far as the splenic flexure, has an absorptive function similar to that of the small intestine, in contrast to the distal part whose function is principally storage. Valvulae conniventes are also wanting although there are projections into the large intestine involving all or a part of the coats internal to the serous

tunic. The muscularis mucosa is less regular in its development and as a whole, feebly represented in comparison to that of the other parts of the intestine. The glands of Lieberkuhn, in general, resemble those of the small intestine, but are larger, and form a more regular and less interrupted layer of parallel tubules. The lining of the glands is conspicuous on account of the great number of goblet cells, which in the middle and upper parts of the tubules, often exist in such profusion that the ordinary cells are almost entirely replaced. Toward the deepest part, or fundus of the glands they are comparatively infrequent. The presence of goblet cells in such numbers accounts for the considerable amount of mucous normally found in the large intestine.

The lymph tissue in definite collections, occurs as solitary nodules only. The lymph nodules occupy a portion of the submucous layer as well as the mucosa. They are situated at the bottom of the pit-like depressions on the mucous surface, into which the nodules project.

The submucous coat closely corresponds with the similar areolar tissue of the small intestine, allowing of fairly free play of the mucosa. In addition to the blood vessels, lymphatics and nerve plexus of Meissner, it contains the deeper and more expanded parts of the solitary nodules.

The muscular coat consists of a thicker layer of internal circular fibres and of an external longitudinal one, the fibres of which are in most places, collected into three bands or the taenia coli.

The serous coat which surrounded the gut in certain places disappears during development, and in others its arrangement becomes modified by new relations with other peritoneal layers. The appendicis Epiploicae are little fringes or bags of peritoneum containing fat, hanging from the large intestine. They are frequently of great importance in fat people but in thin ones may be over-looked. They are found particularly on the inner aspects of

the ascending and descending colon and on the lower one of the transverse colon. They are also found on the sigmoid flexure.

The arteries of the large intestine are derived from the **superior** and inferior mesenteric arteries. The former supplies the caecum ascending and the transverse colon, and a varying amount of the descending colon. The chief supply of the latter is derived from the inferior mesenteric, which is also distributed to the sigmoid flexure.

The part of the large intestine supplied by the superior mesenteric is generally considered to be the absorptive area while that supplied by the inferior mesenteric is the non-absorptive area.

The general plan includes a series of anastomosis between neighboring branches, by which long arterial arches run near the border of the gut, to which they give off irregular twigs. There is no system of straight vessels as in the greater part of the small intestine. In the sigmoid flexure, there is a recurrence of the superimposed arches, which may be three in number. The superior hemorrhoidal branch of the inferior mesenteric artery, runs in the last part of the mesentery of the sigmoid, and often divides it into two branches, which run side by side on the back of the gut toward the rectum. The veins are disposed much the same as the arteries but with a system of straight vessels from the intestine.

The large intestine has the least lymphatics of any part of the intestinal tract. Throughout the entire length of the intestine, the lymphatic net works are arranged in two sets, one of which is situated in the mucosa and the other in the muscular coat. The two net works are more or less independent, though communicating branches occur and both open into a sub-serous net work, from which collecting stems arise. The collecting stems from the

sub-serous net work of the ascending colon pass primarily to some inconstant mesocolic nodes situated along the line of attachment of the colon to the abdominal wall and thence are continued along the lines followed by the right colic vessels to the superior mesenteric nodes.

The stems from the transverse colon have a more varied course in accordance with the arrangement of the blood vessels. They pass primarily to a series of mesocolic nodes, situated between the layers of the transverse meso colon, close to the intestine. These are of larger size and more numerous than the nodes associated with either the ascending or descending colon and are especially well developed toward either angle of the colon. Their efferents pass principally to some four or five nodes situated along the course of the middle colic vessels and thence to the third group of mesenteric nodes but those from the vicinity of the splenic flexure follow the course of the branches of the left colic vessels and so pass to the nodes of the median lumbar group situated in the neighborhood of the inferior mesenteric artery.

The lymphatics of the transverse colon communicate somewhat extensively with those of the great omentum as a result of the attachment of the latter to the colon and are thus placed in connection with the inferior gastric and splenic nodes.

The collecting stems from the descending colon and sigmoid flexure pass primarily to mesocolic nodes situated close to the attached surface of the intestine and thence follow the course of the left colic and sigmoid vessels to the median lumbar nodes, situated in the vicinity of the origin of the inferior mesenteric artery. The mesocolic nodes associated with the descending colon are less numerous and smaller than those of the sigmoid flexure and resemble in appearance and arrangement those of the ascending colon.

The nerves of the large intestine come from the superior

and inferior plexuses, which are derived chiefly from the solar and aortic plexuses respectively. Keith maintains that there are certain nodes along the intestinal tract in which the sympathetic nerve fibres of Auerbach's plexus appear to become continuous with the non-striated muscle fibres or that both have become changed to form a new or intermediate tissue. This intermediate tissue, he calls "Auerbach's tissue". This tissue he says is similar to that in the sino-auricular node, which originates the heart beat. This he maintains is the most excitable tissue in the walls of the intestine and he believes it to be endowed with constructive impulses and muscular movement. He argues that the rhythmic motion of the bowel is controlled from these nodes. He contends that "intestinal stasis" is not due to atony of the musculature of the bowel but to a hypertonicity of those parts which are normally in a state of tonic contraction or that in all cases of intestinal stasis there is some disorder of the neuromuscular mechanism.

CARCINOMA OF THE LARGE INTESTINE.

With the exception of the stomach and possibly the rectum, carcinoma occurs more frequently in the large intestine than in any other part of the alimentary tract. DeBovis states that carcinoma of the large intestine occurs on an average of one in every three hundred deaths. He gives the following percentages for carcinoma of the intestine: small intestine, 6.3%; large intestine:44.5 %, rectum 49.2%.

Statistics collected by Brill show that out of 3563 cases of carcinoma, only 89 or 2.5% were of the small intestine. Nothnagel found in the Wiener Allegemeine Krankenhaus, that out of 2125 autopsies on patients who had died of carcinomata 243 were of the intestine. He also records that out of 343 autopsies on carcinomas of the intestine from the Pathological Institute of the

General Hospital in Vienna, 17 or less than 5% were of the small intestine, the remainder of the large intestine. Hemmeter reports that out of 5792 cases of carcinomata collected by different observers, 1296 were carcinoma of the intestine. Mayo states that out of 1264 cases of carcinoma of the gastro-intestinal tract operated on at St. Mary's Hospital, between October 1st, 1897 and November 1, 1911, 863 involved the stomach, 14 the small intestine and 219 the large intestine, and 168 the rectum.

Nothnagel states that carcinoma of the large intestine is most common between the ages of 40 and 60. Most observers are agreed as to this and also state that it may occur at any age and is quite common between the ages of 20 and 30. In 66 cases collected by DeBovis the average age was 42 years. The average age in most series seems to be considerably higher than this. Zuppinger cites a case of carcinoma in the sigmoid of a girl 12 years old. Gerard reported a colloid carcinoma in the sigmoid flexure of a boy 12 years old. Clar described a medulary carcinoma in the colon of a boy 3 years old.

The disease seems to be slightly more prevalent in males than females. Clogg reports 55 cases, with 29 male and 26 female. DeBovis found in his series, 53.9 % males and 64.1% females. Custom and Vander Veer give 63.83% males and 36.17% females. Nothnagel believes, from his own experience that there is little difference in the relative frequency with which it occurs in the two sexes but from the statistics he has collected from other observers, it would seem that it is somewhat more common in males.

Statistics vary considerably as to the relative frequency of carcinoma in the different parts of the large intestine but most are agreed that the sigmoid flexure of the large intestine proper is the most common site. Madyl reported 46 cases of carcinoma of the large intestine from the Vienna General Hospital. Of these, there were thirteen in the sigmoid flexure, six

in the ascending colon, 1 in the appendix and 17 in the remainder of the colon. From the same place Nothnagel reports 118; 11 in the appendix, 14 in the caecum, 63 in the colon in general, and 40 in the sigmoid flexure. Bryant reports 104 cases; 7 in the caecum, 78 in the sigmoid, and 19 in the remainder of the colon. Leichtenstern reports 109 cases; 42 in the sigmoid, 11 in the descending colon, 30 in transverse colon, 6 in the ascending colon and 20 in the caecum.

Carcinoma of the large intestine begins in the crypts or glands of Lieberhuhn. Nothnagel says the degeneration of glandular epithelium, characteristic of carcinoma always begins at the fundus of the glands. The epithelium of the degenerated mucous glands then perforate the muscularis mucosa and the deeper tissues of the intestinal wall. According to Cole, when the carcinoma cells reach the inter muscular network of lymphatics they tend to progress around the bowel in the direction of these vessels, thus accounting for the frequency of the annular or ring carcinoma in the large intestine. The involvement of the lymph glands may take place as soon as the process reaches the lymphatic network of the submucosa or it may take place through the intermuscular lymphatic network.

The ordinary form of adenocarcinoma is perhaps found in every carcinoma that originates in the large intestine but there is no doubt but what colloid carcinoma has a distinct entity and is present in a great many cases of carcinoma of the large intestine. There is as yet considerable controversy as to the histogenesis of colloid carcinoma. Hauser states that colloid carcinoma starts from mucous membrane but does not say whether it is a product of local secretion or one of degeneration. He states that colloid carcinoma of the large intestine very rarely produces metastasis in the other organs, but chiefly involves the serosa.

Metastasis as a rule, occurs very slowly in carcinoma of the large intestine. Mickulicz says carcinoma may exist for years in the colon without producing alarming symptoms or seriously affecting the health. Mild malignancy and late metastasis favor surgical cure. Maydl says that secondary

metastatic infection of the lymph glands is comparatively so rare as to make the radical cure of carcinoma of the large intestine favorable. Clogg states that carcinoma of the colon in many cases is a local disease. In 41 cases he traced to autopsy, in only six or 15% were there any visceral deposits and these were in cases of comparatively short symptoms rather than with long symptoms. The symptoms were from two to six months, and the liver was involved in all cases of glandular involvement. In Symmers study of metastasis of tumors in a series of autopsies at Bellevue Hospital, he points out the striking contrast between the low degree of malignancy, displayed by the tumors of the lower intestinal tract, and the high degree of malignancy displayed by tumors of the stomach and upper intestinal tract. In 46 cases of carcinoma of the stomach, 82% showed metastasis; 3 of the duodenum, all showed metastasis; 28 of the lower bowel, showed metastasis in only 15 or 46.5%.

Welch states that carcinoma of the large intestine spreads by direct extension of the cancer process and by dissemination of the cancer cells. Jameson and Dobson have shown that the lymphatic drainage of the large intestine follows a certain orderly plan, and Clogg states that the dissemination of cancer of the colon proceeds on the same anatomical lines. Sherill says metastasis from carcinoma of the bowel seems to occur most often through the blood and the liver suffers most frequently from secondary deposits. McArthur calls attention to the fact that the portal circulation alone of all the venous systems, seems to transport the infectious elements of cancer, and it is through this means that carcinoma so frequently reaches the liver from the large intestine. Mayo calls attention to traumatic dissemination of malignant disease, especially during surgical operations. He says the infected thrombi in the derivatives of the portal vein are loosened and carried to the liver. Nothnagel calls attention to the fact that metastasis may be present with comparatively small growths and

be absent with immense growths. MacCollum cites a case in which the primary mass in the colon was only 3 cm in diameter yet a metastatic nodule in the liver reached the size of a man's head.

Chapter II.

Materials and Methods.

One hundred preserved specimens, which had been removed operatively in the Mayo Clinic were the basis of this study. The specimens were first studied in the gross. The size, location, form, extent, and character of the growth as well as the surrounding normal tissues were first studied. Photographs were then made of the specimens, one showing the growth viewed from the mucosal side and the other showing a cross section cut through the center of the growth in the longitudinal axis of the bowel. The character and extent of the invasion of the growth into the submucosa, muscular coats, and glands were then studied. Sketches of the specimens were next made showing the relative location and size of the growth, leaving space on this sketch in which to place the glands, to be dissected out as nearly as possible in their relative positions.

The lymph glands were then very carefully dissected out. In order to obtain the smallest glands visible to the naked eye, all the gland bearing tissue was teased out into layers, through which the light could be transmitted. With a light back of this, very small glands could then be detected. As each gland was removed, its location in the longitudinal and radial directions, was recorded upon the sketch as nearly as possible. In each case the drawing represented the size of the gland as nearly as it was possible to estimate. A section of the original growth was taken in each case. This section in each case was number I, and each gland was numbered in its place at the time it was put on the sketch. The section of the original specimen and each gland was placed in a small phial, correspondingly numbered and preserved in ten percent formalin. These were then all sectioned, stained, and mounted for microscopic study. The sections of the glands were studied for metastasis under the microscope and the

results were recorded on the sketches above described. Any unusual or especially striking features were also recorded on the sketch.

Printed diagrams were then obtained of the different parts of the intestine studied. These were the ascending colon, hepatic flexure, transverse colon, splenic flexure, descending colon, and sigmoid flexure. A diagram representing a cross section of the bowel was also obtained for each specimen. The growth was sketched both as to its longitudinal position and its position on the circumference of the bowel. The glands were then placed on the diagram as nearly as possible, in the relative position in which they were found. There was no attempt to show the relative size of the glands on these diagrams as was done on the original sketches but a few drawings were made of typical specimens, in which both the size and location of the glands were represented as nearly as possible. These will be discussed further on. On the diagrams, glands which showed no carcinomatous involvement were represented as circles, while those which showed carcinomatous involvement were represented in solid black. On the diagram of the cross section the growth was represented as encircling or on one or more walls of the intestine.

Chapter III.

R E S U L T S

The distribution by decades of cases studied is shown in Table I (page 16). Forty-two percent were in the sixth decade. The average age was 52.31 years. The youngest was twenty-one and the oldest seventy-six years of age. There were fifty one males and forty-nine females.

Fourteen hundred and six glands were obtained from the one hundred specimens or 14.06 glands per specimen. Sixty-three per cent showed no carcinomatous metastasis while thirty-seven percent showed one or more glands involved. There were very few specimens which showed more than two or three glands involved so it was not considered necessary to make a third group corresponding to that in the series of MacCarty and Blackford in their study of the glands of the stomach or that of McVay in his study of the glands of the rectum. All were first put into two groups. Group I. Cases of carcinoma of the large intestine with no metastatic involvement of regional lymph glands. Group II. Cases of carcinoma of the large intestine with metastatic involvement of one or more regional lymph glands.

After some study of these two groups, a third group suggested itself. Group III. Cases of colloid carcinoma of the large intestine. This group was further divided into two sub-groups. Group III.-A. Cases of colloid carcinoma with no metastatic involvement of the regional lymph glands. Group III. B. Cases of colloid carcinoma of the large intestine with metastatic involvement of the regional lymph glands.

TABLE I.

Showing the distribution in decades of the 100 cases of carcinoma of the large intestine.

1-10-----	-----	0
11-20-----	-----	0
21-30-----	21,26,29,29,29-----	5
31-40-----	-----	8
41-50-----	-----	21
51-60-----	-----	42
61-70-----	-----	21
71-80-----	72, 75, 76-----	3

Total 100

GROUP I. Cases of carcinoma of the large intestine with no metastatic involvement of the regional lymph glands.

In this group there were sixty-three cases, or sixty-three percent. There were thirty-one females and thirty-two males. The average age was 52.1 years. The average number of glands per specimen was 15.4. It is noticeable that while there are several specimens in which very few or no glands could be found, in the majority of cases a great number of very large glands were present. Table II (pages, 18, 19) shows the sex age, duration of symptoms and the number of glands found in each case of this group. Diagrams of the glands and growths are shown in Plates I to VII inclusive (pages 20-26 incl.). In plates VIII to XXII inclusive (pages 27-47 incl.) are representative photographs of the specimens of this group and the photographs of the cross sections of the growth. Plates XXIII to XXV inclusive (pages 48-50 incl.) show x-ray photographs taken previous to operation showing typical filling defects in these three cases.

McVay, in his study of the rectum pointed out the fact that the size of the growth bears no relation to the glandular involvement. It can be seen from these photographs that the same holds true in this case. Nothnagel states that carcinoma usually encircles the lumen of the large bowel and produces an obstruction in this way. In this group of sixty-three cases the encircling form of carcinoma was present in twelve cases. Plate VIII (page shows a marked protuberant growth from one wall of the intestine. This is quite characteristic of this group. Extension seems to be into the lumen of the bowel, rather than into the bowel wall. Extension into the muscle and fatty layers is not common.

Table II.

GROUP I.

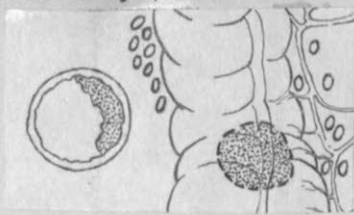Cases of Carcinoma of the Large Intestine with no metastatic involvement of the lymph nodes.

<u>Case No.</u>	<u>Sex</u>	<u>Age</u>	<u>Duration of Symptoms in months</u>	<u>Total no. of glands.</u>
209714	F	50	4	15
139635	M	63	6	16
284697	F	55	12	13
243782	F	38	11	31
286874	M	67	12	17
243328	F	50	8	0
256207	F	42	3	12
256600	M	56	14	26
270880	M	58	2	18
117846	F	32	12	33
311830	F	75	6	12
339496	M	64	6	0
321076	F	50	12	21
321874	M	21	4	0
335692	M	64	9	28
312376	M	46	10	28
296635	M	57	12	18
213599	M	37	12	28
203854	F	56	6	0
215203	M	76	36	0
261360	F	50	12	5
73058	M	40	12	11
324824	F	58	18	15
243755	M	49	2	21
245802	M	40	2	28
245378	F	56	5	11
248127	F	49	7	28
263828	F	50	1	8
182292	M	58	7	7
314249	F	62	14	14
265558	M	46	8	17
212357	M	65	12	37
268852	M	62	6	20
289153	M	64	?	7
237533	M	51	11	9
209460	M	39	12	5
278586	F	52	8	18
219689	M	60	14	23
100279	M	29	3	25
84262	M	52	6	12
214608	F	55	7	5
219038	M	55	6	28

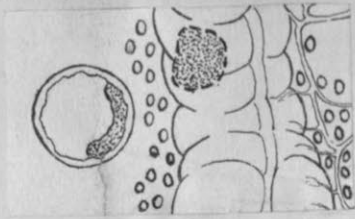
Group I (continued)

<u>Case No.</u>	<u>Sex</u>	<u>Age</u>	<u>Duration of Symptoms in months</u>	<u>Total no. of glands.</u>
296853	M	66	8	8
184460	F	39	18	27
223299	F	57	11	16
240539	F	64	10	4
246503	F	29	6	15
250035	F	49	2	11
251195	F	57	10	14
257681	F	48	1	22
289835	M	72	1	8
68010	M	58	12	12
212902	F	45	9	9
268339	M	52	6	12
261807	F	26	4	17
230039	F	63	0	8
205274	M	47	24	10
219381	F	50	6	16
188149	M	45	4	19
197535	M	44	6	37
191500	F	65	8	15
172055	F	63	12	11
284368	F	47	3	11
	<hr/>	<hr/>	<hr/>	<hr/>
	F--31	52.1 average	8.7 average	972 total
	M--32			15.20 average.

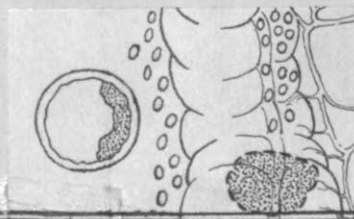
Case 324824. Lower ascending colon.
Inner wall. 6 by 7 cm.



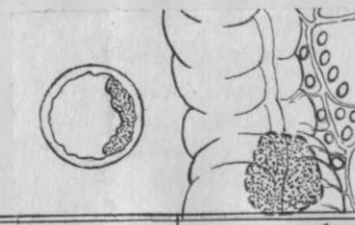
Case 248127. Lower ascending colon.
Inner wall. 7 cm. in diameter.



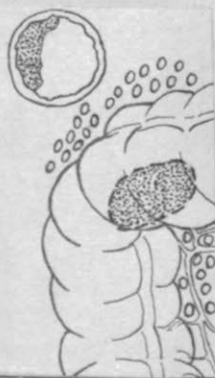Case 184460. Middle ascending colon.
Inner wall. $3\frac{1}{2}$ cm. in diameter.



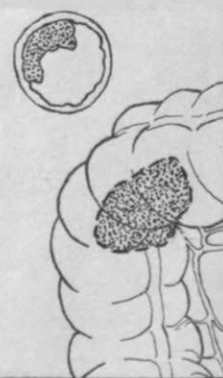Case 68010. Lower ascending colon.
Inner wall. 4 by 7 cm.



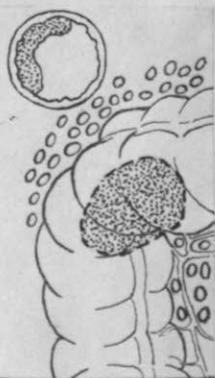Case. 312367. Hepatic flexure. Posterior wall. 10 by 11 cm.



Case 203854. Hepatic flexure. Posterior wall. No glands found. 4 by 5 cm.



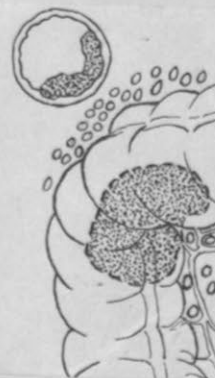Case 117846. Hepatic flexure. Posterior wall. 10 cm. in diameter.



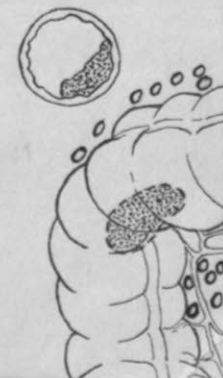Case. 296853. Hepatic flexure. Outer wall. 8 glands in one bunch. Posteriorly, all negative. 4 by 5 cm.



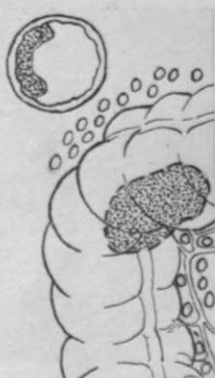Case 256600. Hepatic flexure. Anterior wall. 7 by 7 cm.



Case. 84262. Hepatic flexure. Inner wall. 6 by 8 cm.



Case 256207. Hepatic flexure. Posterior wall. 4 by 8 cm.



Case 205274. Hepatic flexure. Posterior wall. 6 by 6 cm.

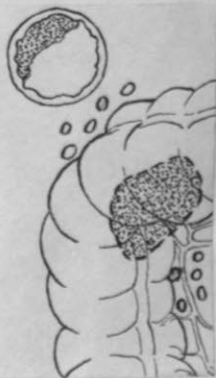

Plate I. Group I. Diagrams showing relative position of glands and growths. Glands not involved in clear circles. Glands involved in solid black.

Mr. J. Hayes

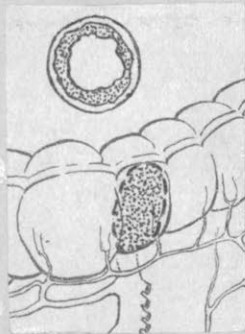Therapist

Mar. 20, 1921

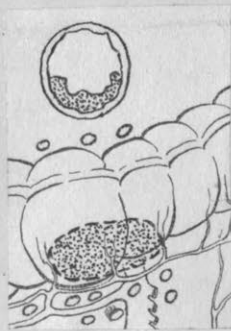
No. 3480

PHOTOGRAPHED

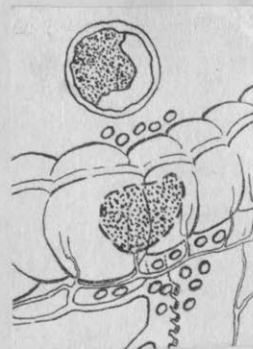
Case 321874. Left transverse colon. Encircling. No glands found. 4 cm. in diameter.



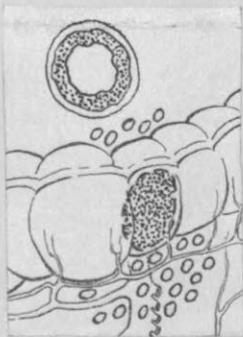Case. 73058. Middle transverse colon. Lower wall. 6 by 9 cm.



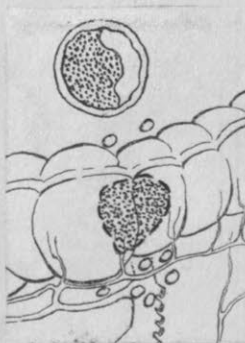Case 265558. Middle transverse colon. Posterior wall. 4 by 7 cm.



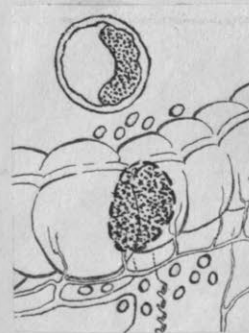Case 243755. Middle transverse colon. Encircling. 5 by 8 cm.



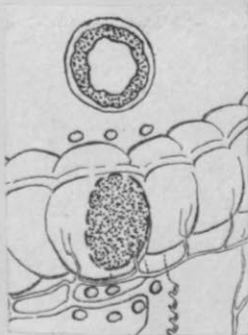Case 263828. Middle transverse colon. Posterior wall. 10 cm. in diameter.



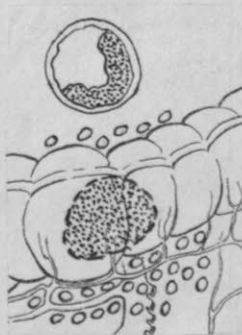Case 209714. Middle transverse colon. Anterior wall. 10 cm. in diameter.



Case 172055. Middle transverse colon. Encircling. 4 by 8 cm.



Case 335692. Middle transverse colon. Posterior wall. 9 by 14 cm.



Case 321076. Left transverse colon. Anterior wall. 5 cm. in diameter.

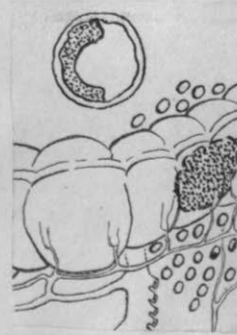


Plate II. Group I. (Legend Plate I).

Mr. J. Hayes.

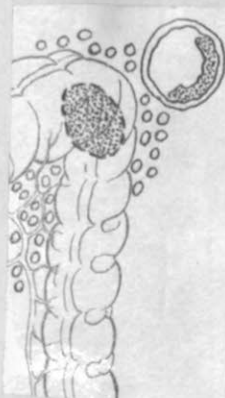
Thesis

Mar 20, 1921

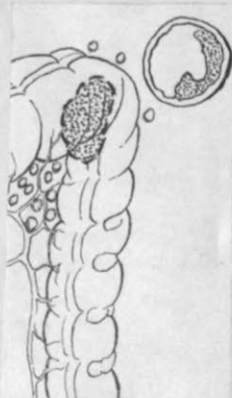No. 3481

PHOTOGRAPHED


Case 243782. Splenic flexure. Anterior wall. 7 by 13 cm.



Case 284697. Splenic flexure. Posterior wall. 9 cm. in diameter.



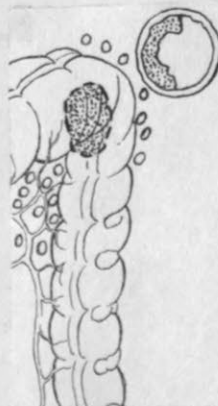Case 245378. Splenic flexure. Anterior wall. 3 by 13 cm.



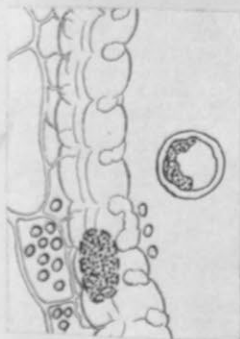
Case 188149. Splenic flexure. Posterior wall. 4 cm. in diameter.



Case 296635. Splenic flexure. Anterior wall. 3 by 6 cm.



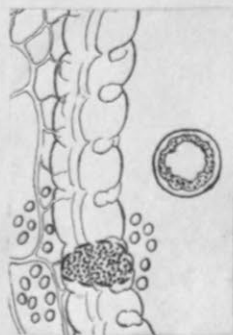Case 139635. Lower descending colon. Inner wall. 8 by 10 cm.



Case 191500. Upper descending colon. Encircling. 8 cm. in diameter.



Case 257681. Lower descending colon. Encircling. 5 by 5 cm.



Case 245802. Middle descending colon. Inner wall. 6 by 12 cm.

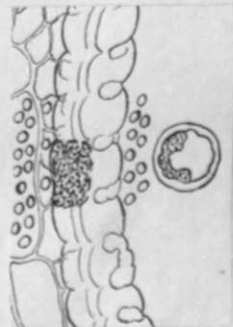


Plate III. Group I. (Legend Plate I).

W. J. Hayes

Thesis

Mar 20, 1921

NO#3482

PHOTOGRAPHED

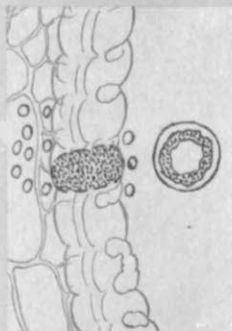

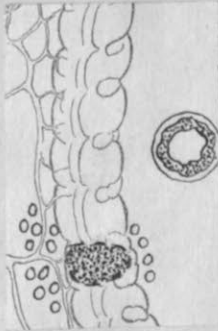
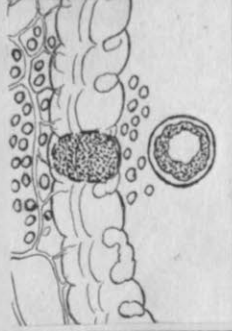




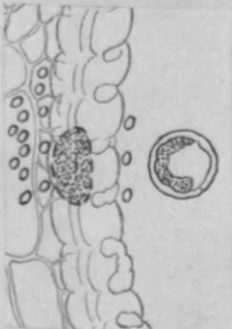


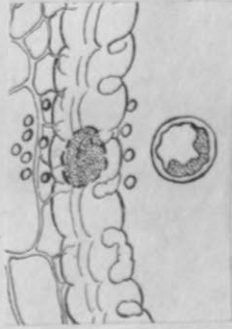
<p>Case 268339. Middle descending colon. Encircling. 4 cm. in diameter.</p> 	<p>Case 270880. Lower descending colon. Inner wall. 5 by 6 cm.</p> 	<p>Case 219381. Lower descending colon. Encircling. 8 cm. in diameter.</p> 	<p>Case 197535. Middle descending colon. Encircling. 6 cm. in diameter.</p> 
<p>Case 219689. Lower descending colon. Inner wall. 10 cm. in diameter.</p> 	<p>Case 2209460. Lower descending colon. Posterior wall. 9 cm. in diameter.</p> 	<p>Case 182292. Middle descending colon. Posterior wall. 14 cm. in diameter.</p> 	<p>Case 286874. Lower descending colon. Posterior wall. 7 cm. in diameter.</p> 
<p>Case 261807. Middle descending colon. Inner wall. 3 by 4 cm.</p> 	<p>Case 289835. Lower descending colon. Encircling. 4 by 9 cm.</p> 	<p>Case 339496. Upper descending colon. Posterior wall. No glands found. 6 by 9 cm.</p> 	<p>Case 311830. Middle descending colon. Posterior wall. 2 by 4 cm.</p> 

Plate IV. Group I. (Legend Plate I).

Wm. J. Hayes

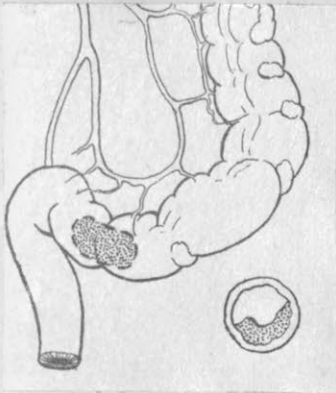Thesis

Mar. 20 1921

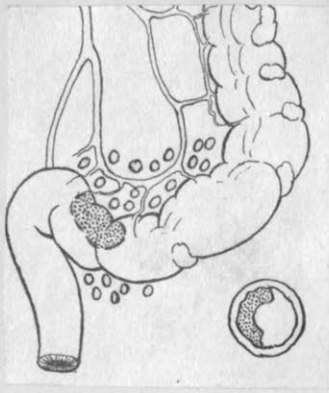
no 3483

PHOTOGRAPHED

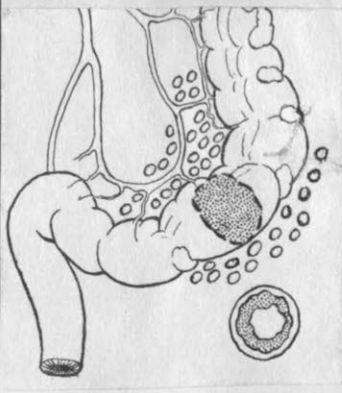
Case 243328. Lower sigmoid.
Posterior wall.
6 by 8 cm. No glands.



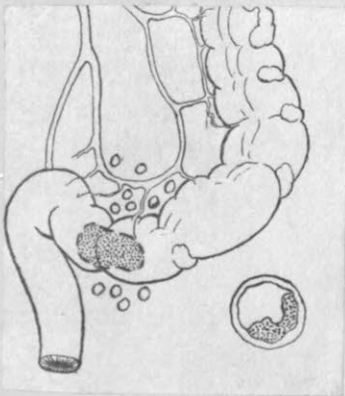Case 268852. Lower sigmoid.
Inner wall.
7 by 7 cm.



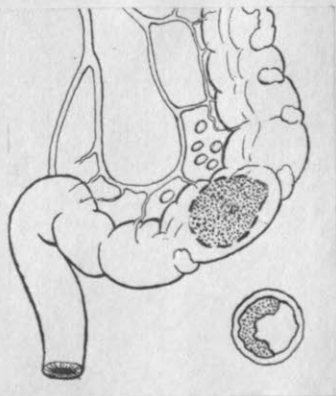
Case 212357. Upper sigmoid.
Encircling.
4 by 8 cm.



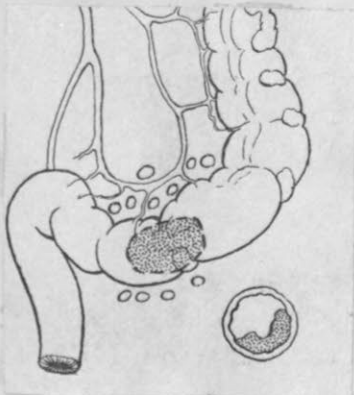
Case 284368. Lower sigmoid.
Posterior wall. 3 by 6 cm.



Case 261360. Upper sigmoid.
Anterior wall. 8 by 10 cm.



Case 250035. Middle sigmoid.
Posterior wall. 7 by 8 cm.



Case 278586. Lower sigmoid.
Inner wall. 5 by 8 cm.

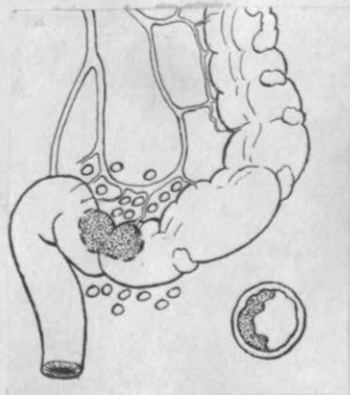


Plate V. Group I. (Legend Plate I).

H. J. Hayes

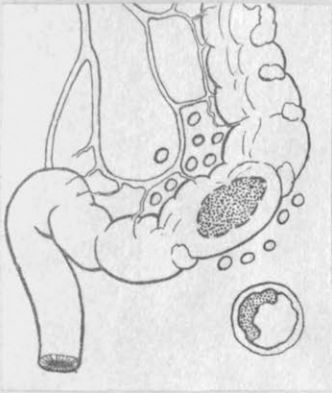Illinois

Mar. 20, 1921

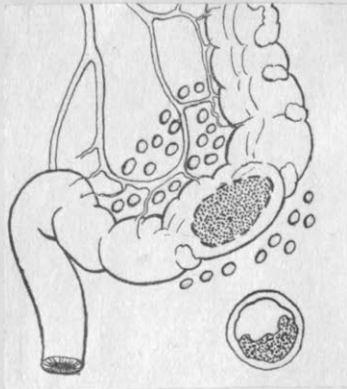
No. 3485

PHOTOGRAPHED

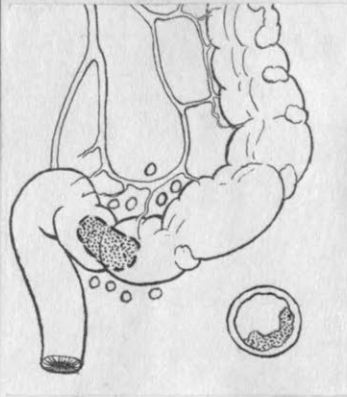
Case 246503. Upper sigmoid.
Anterior wall.
1 by $1\frac{1}{2}$ by 1 cm.



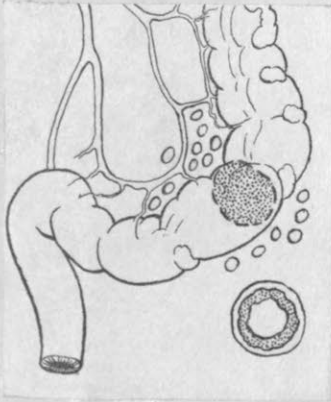Case 213599. Upper sigmoid.
Posterior wall.
10 cm. in diameter.



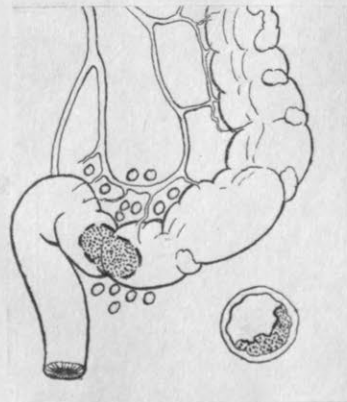
Case 237533. Lower sigmoid.
Posterior wall.
5 by 7 cm.



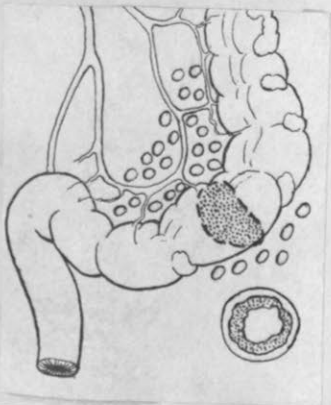Case 223299. Upper sigmoid.
Encircling. 4 cm. in diameter.



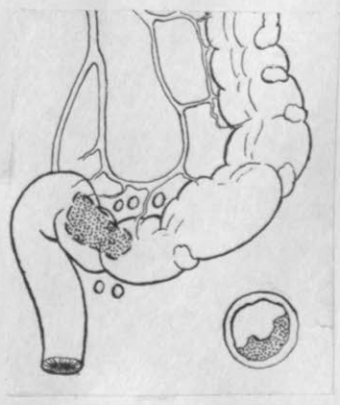
Case 314249. Lower sigmoid.
Posterior wall. 5 by 5 cm.



Case 100279. Upper sigmoid.
Encircling. 4 by 6 cm.



Case 214608. Lower sigmoid.
Posterior wall. 8 by 10 cm.



Dr. J. Haynes

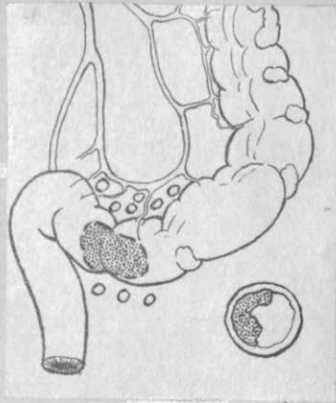Thesis

Mar. 20, 1921.

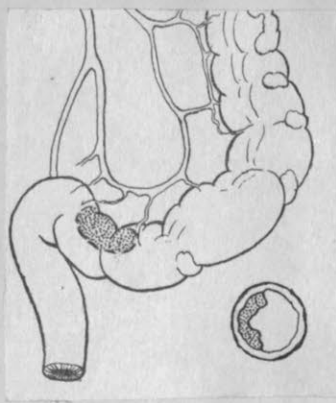
No # 3484

PHOTOGRAPHED

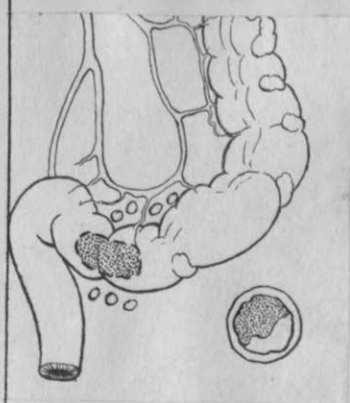Case 212902. Lower sigmoid.
Anterior wall.
6 by 8 cm.



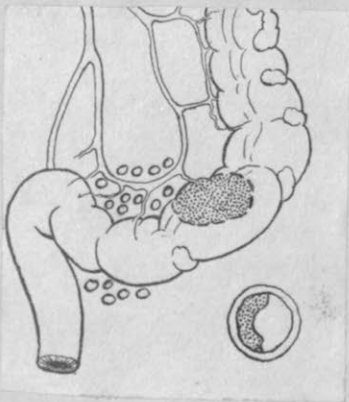
Case 215203. Lower sigmoid.
Inner wall.
6 by 8 cm. No glands.



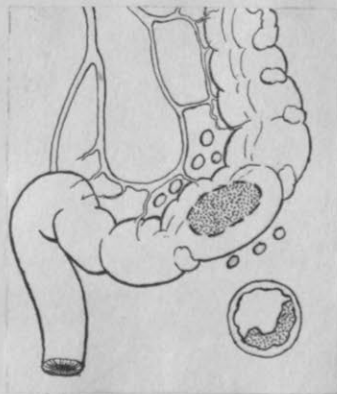Case 289153. Lower sigmoid.
Posterior wall.
5 cm. in diameter.



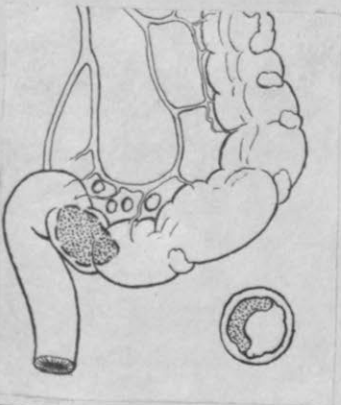Case 251195. Upper sigmoid.
Inner wall. 5 cm. in diameter.



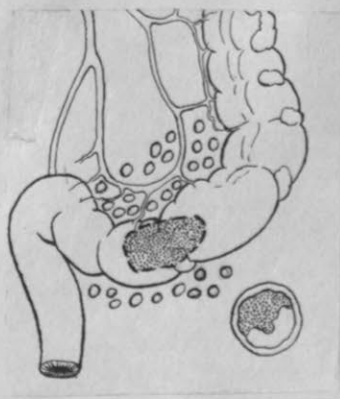Case 230093. Upper sigmoid.
Posterior wall. 4 by 8 cm.



Case 240539. Lower sigmoid.
Anterior wall. 4 by 10 cm.



Case 219038. Middle sigmoid.
Encircling. 4 cm. in diameter.



Mr. J. Hayes

Thesis

Mar. 20, 1921

No. 3486

PHOTOGRAPHED

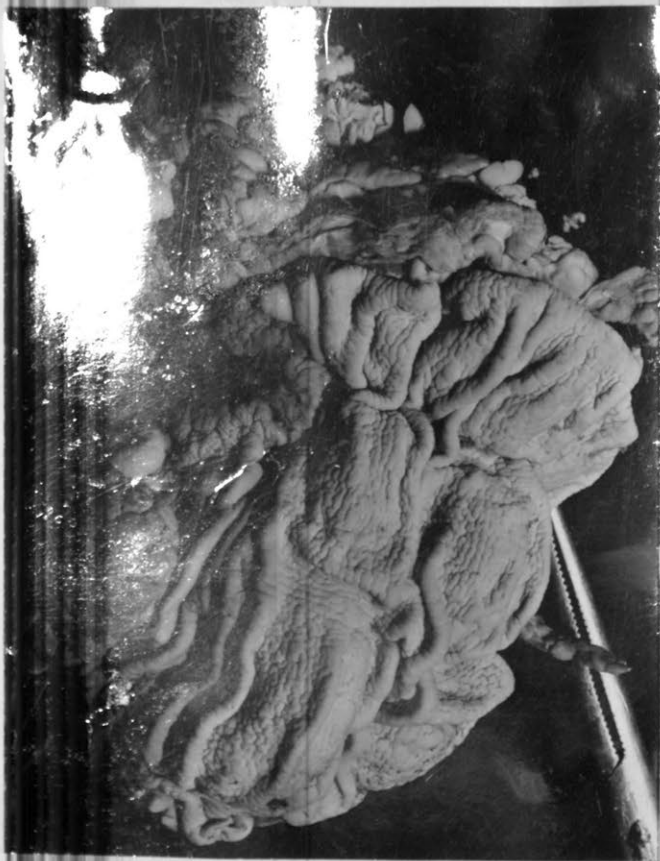

Plate VIII. Group I. Case 184460



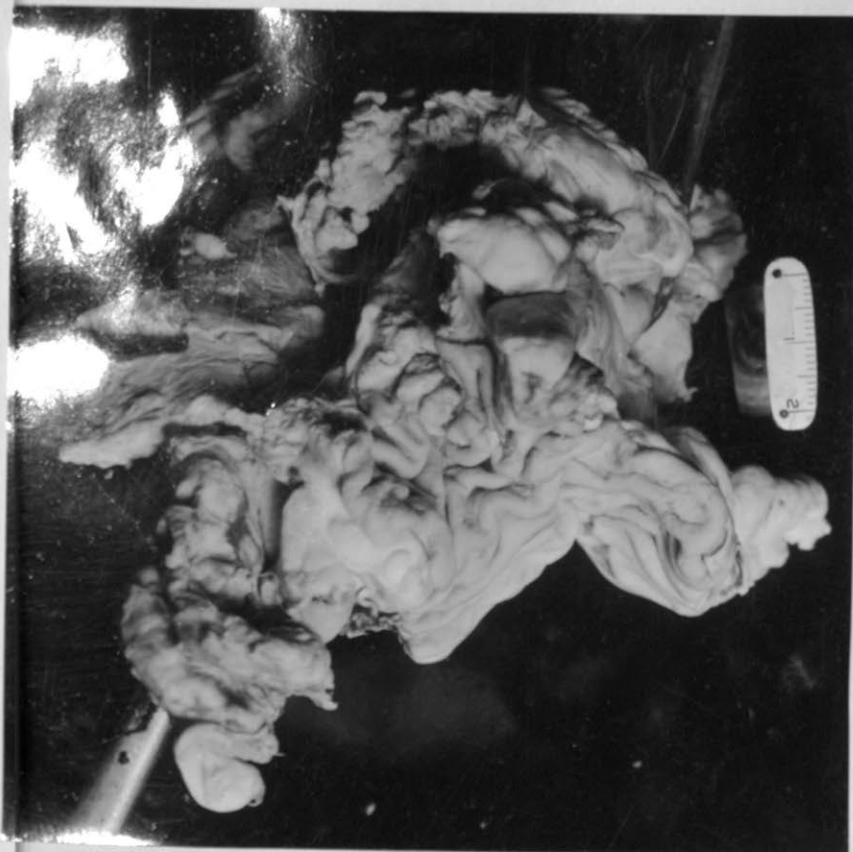

Plate IX. Group I.
Case 278586.



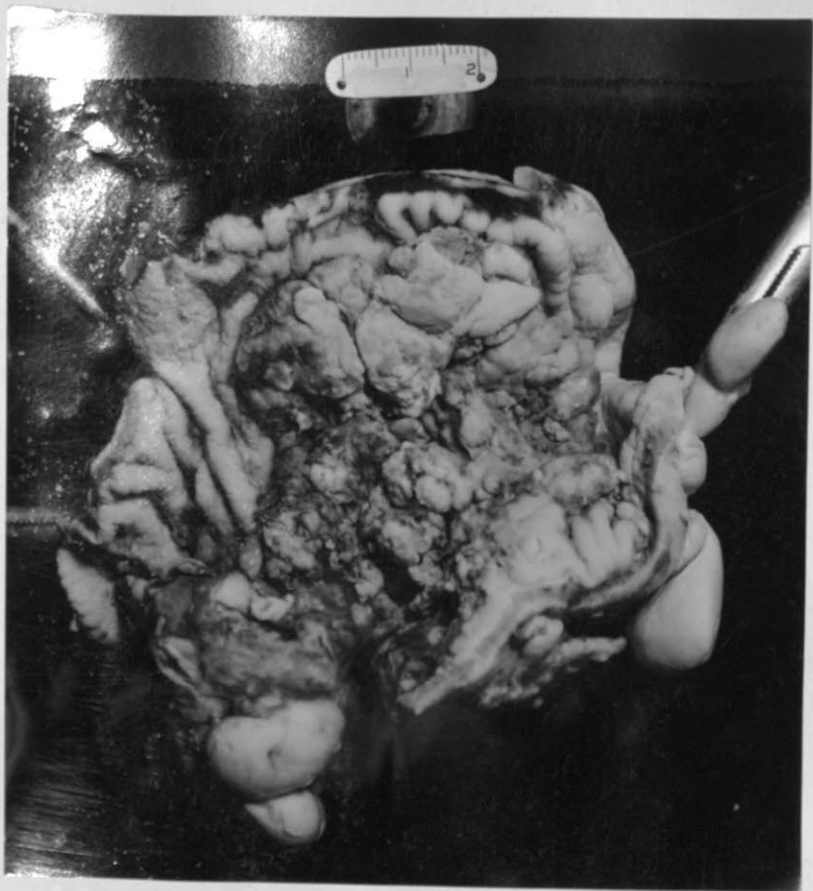
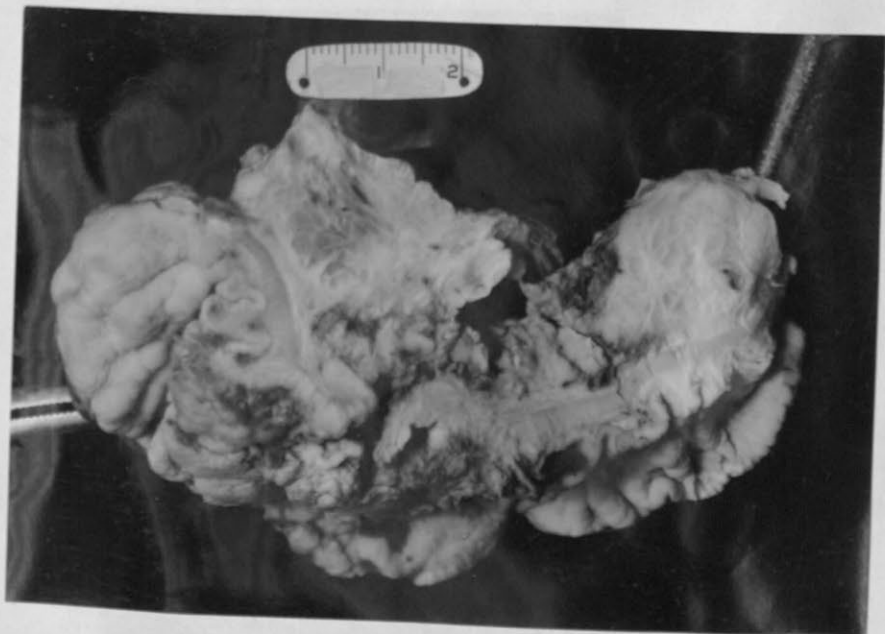
Plate X. Group I.
Case 250035.



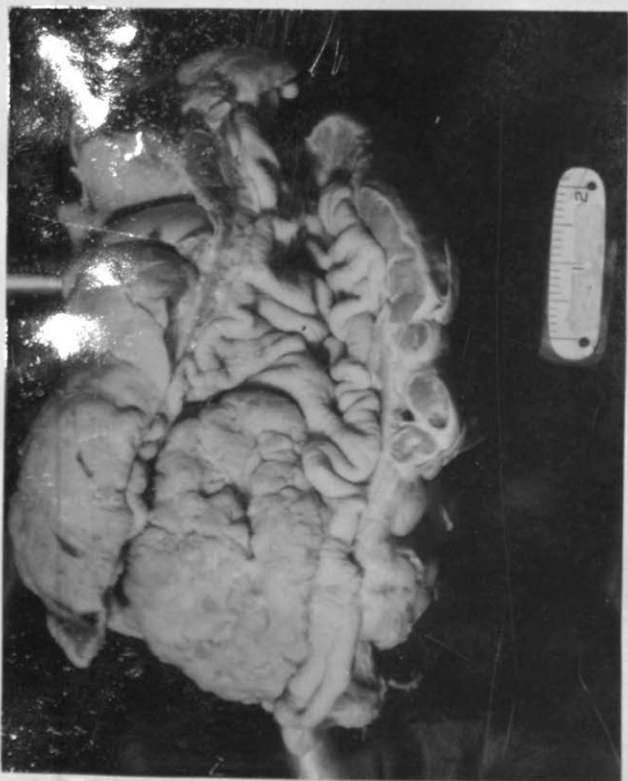


Plate XI. Group I. Case 240539.

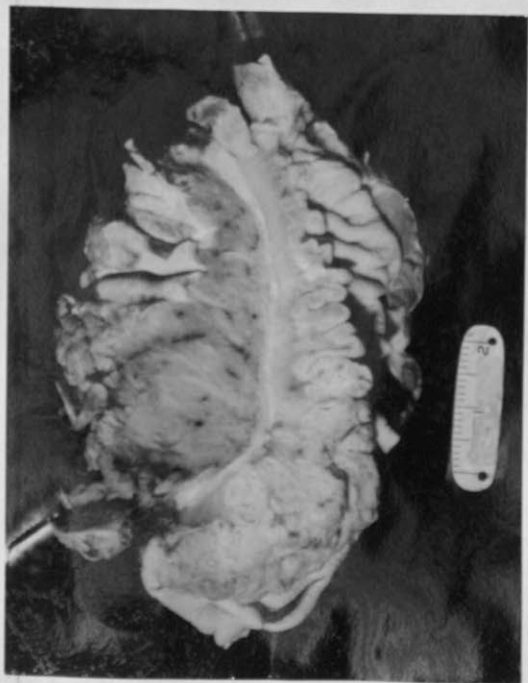
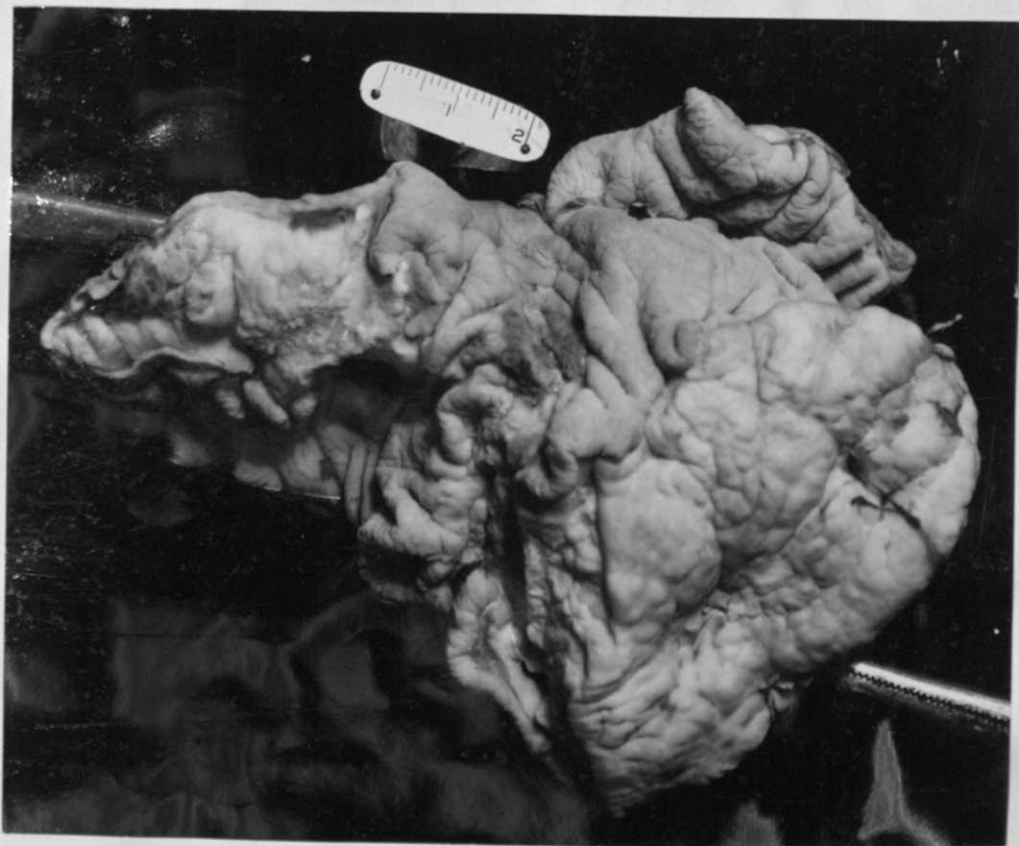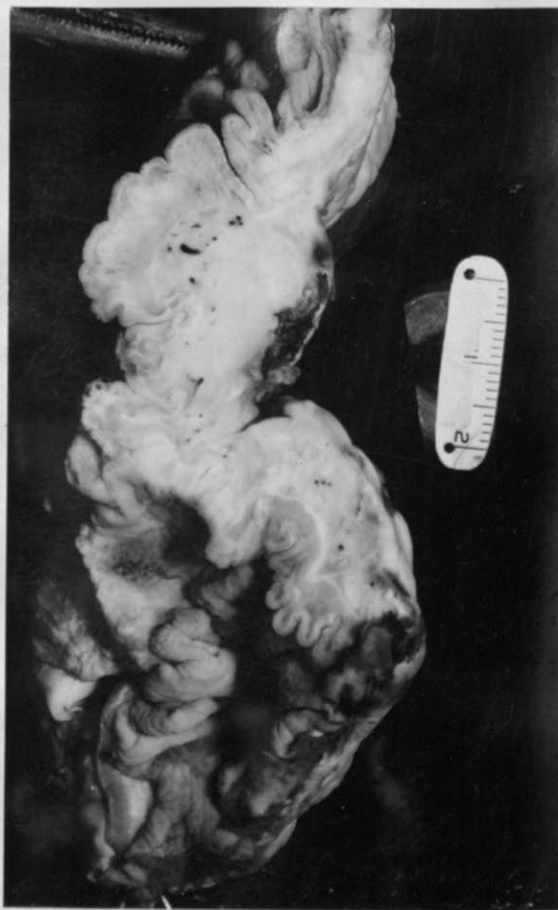




Plate XII. Group I. Case 289335.



b. Plate XII. Group I. Case 289335

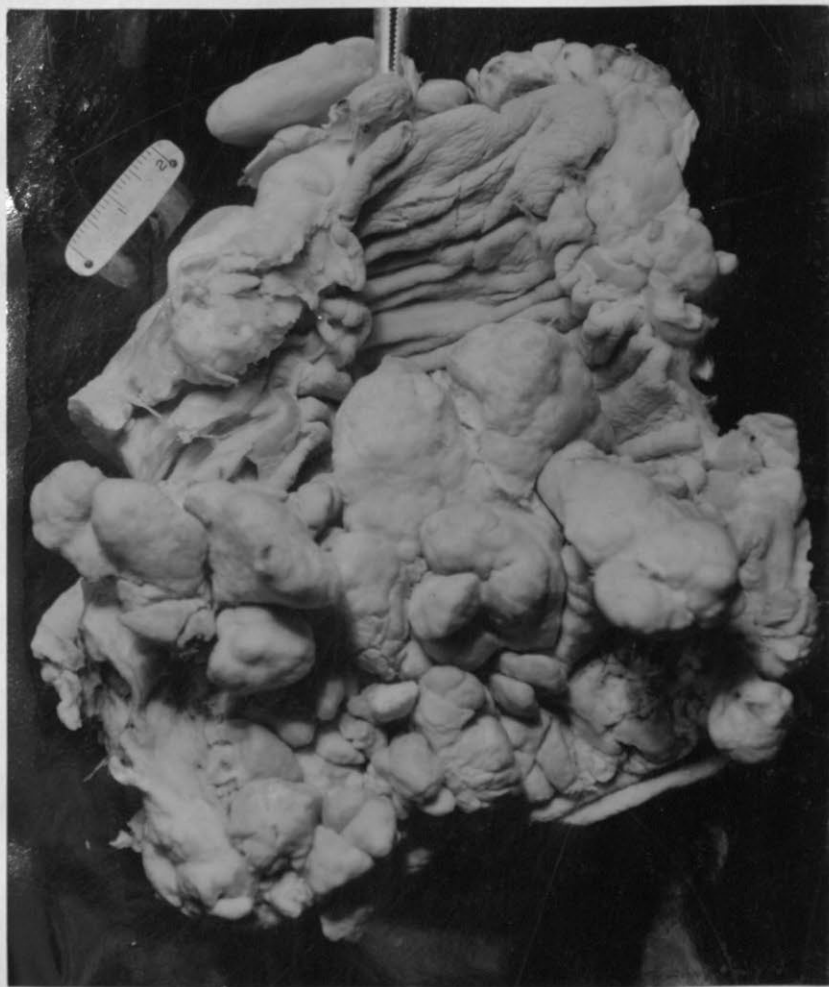


Plate XIII. Group I. Case 261360



b. Plate XIII. Group I. Case 261360

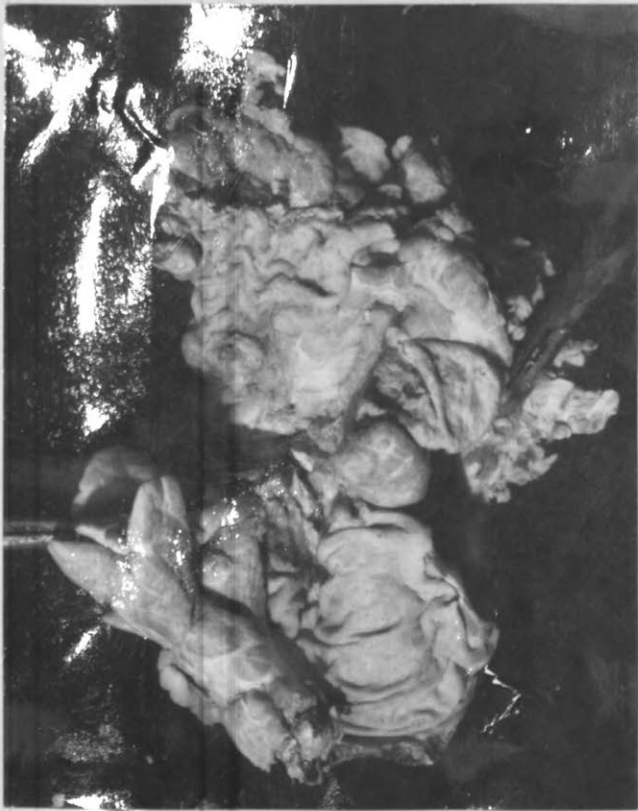

Plate XIV. Group I. Case 251195

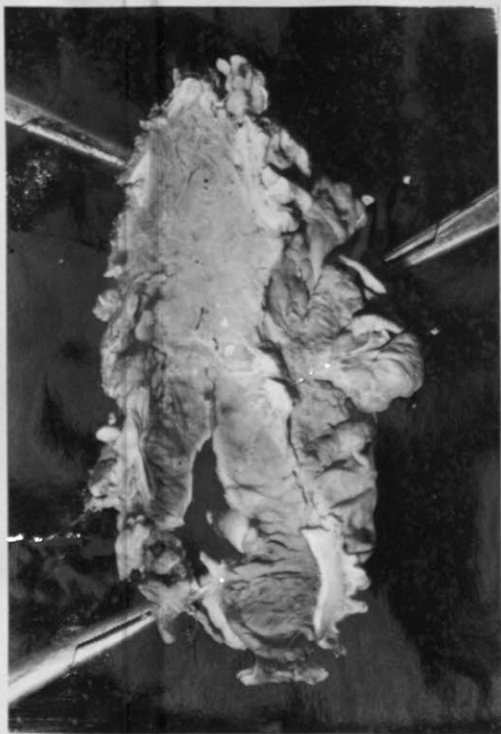
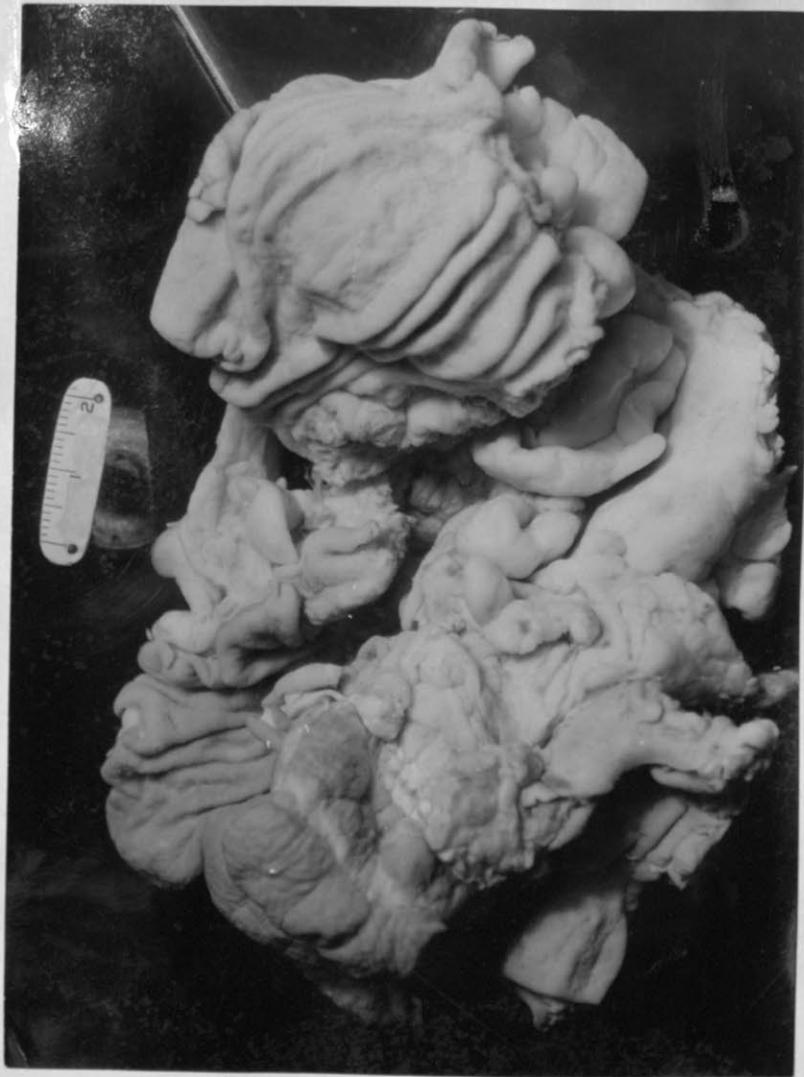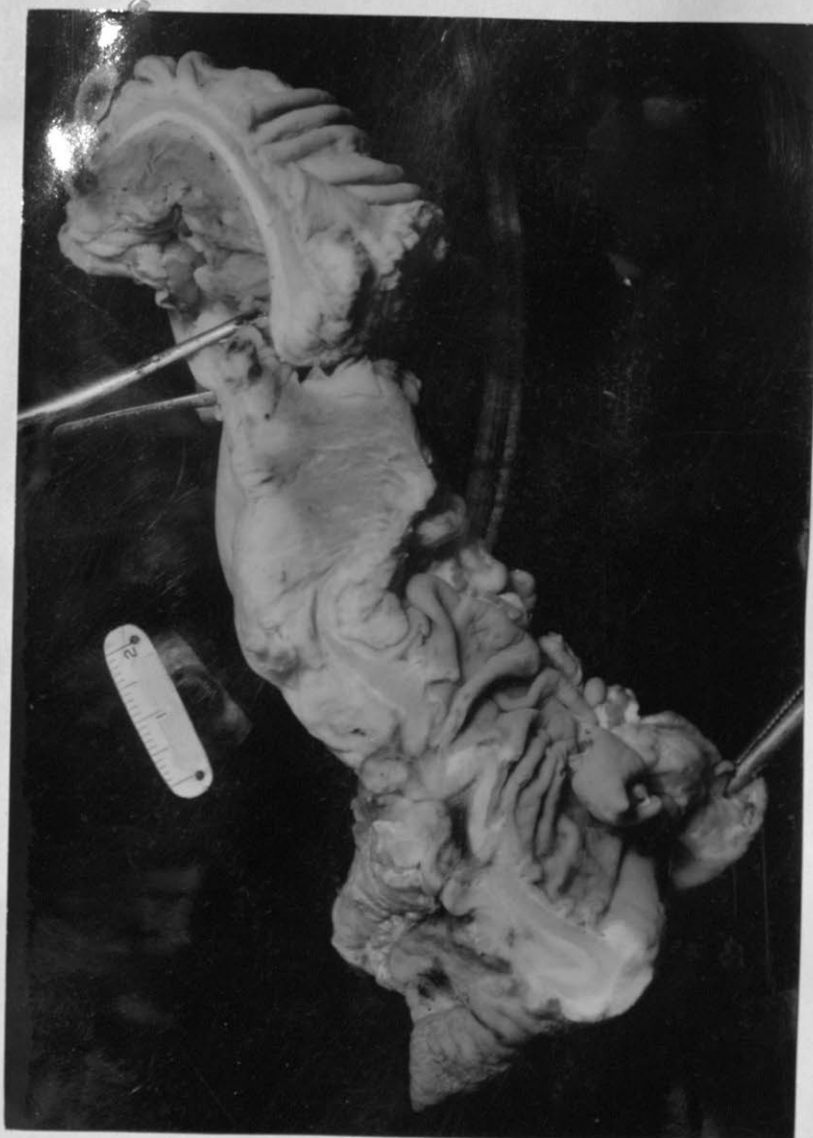




Plate XV. Group I. Case 257681.



b. Plate XV. Group I. Case 257681.

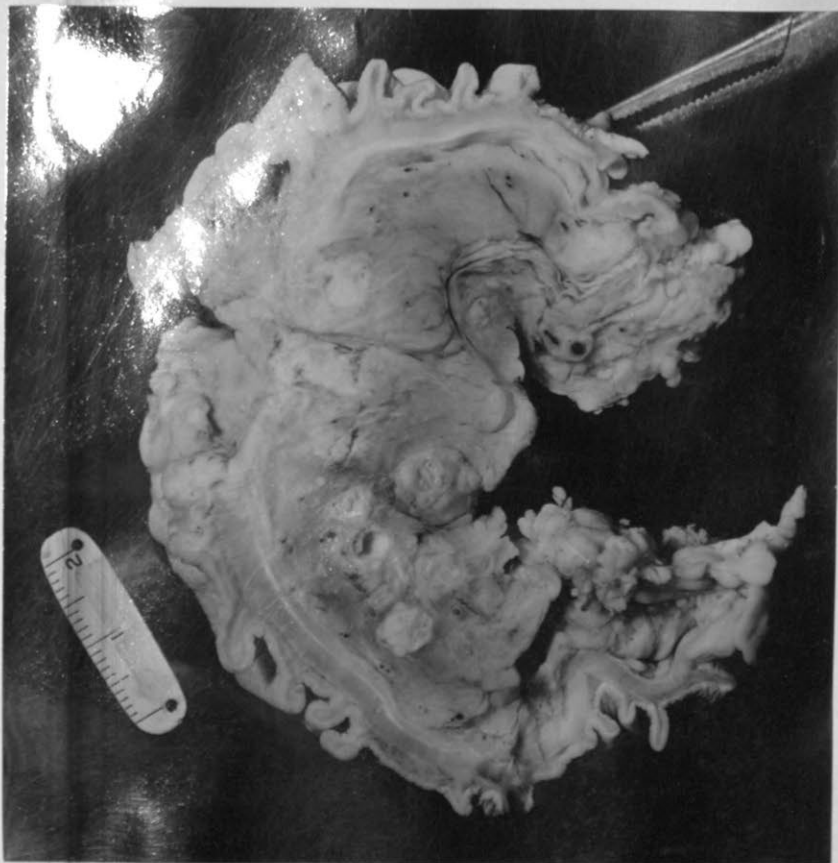
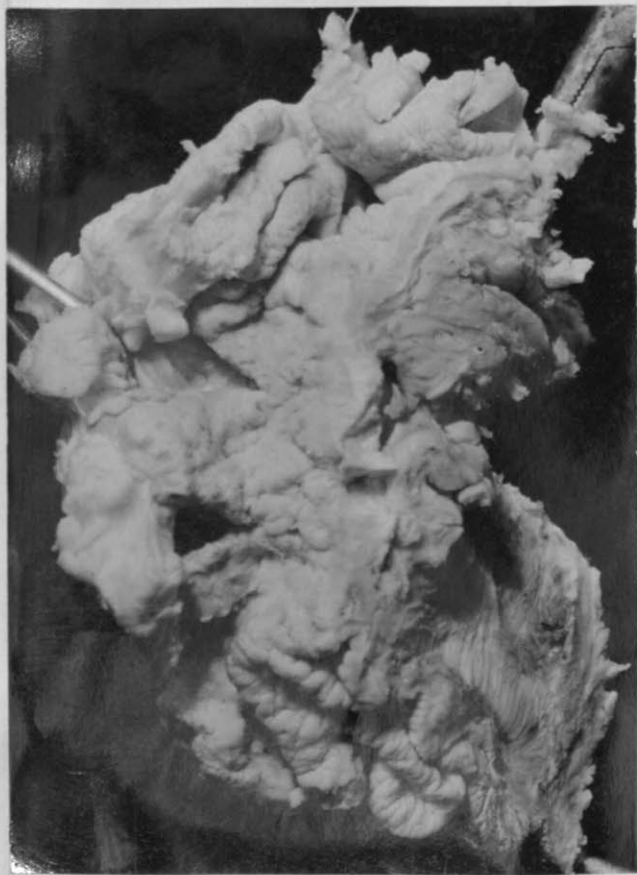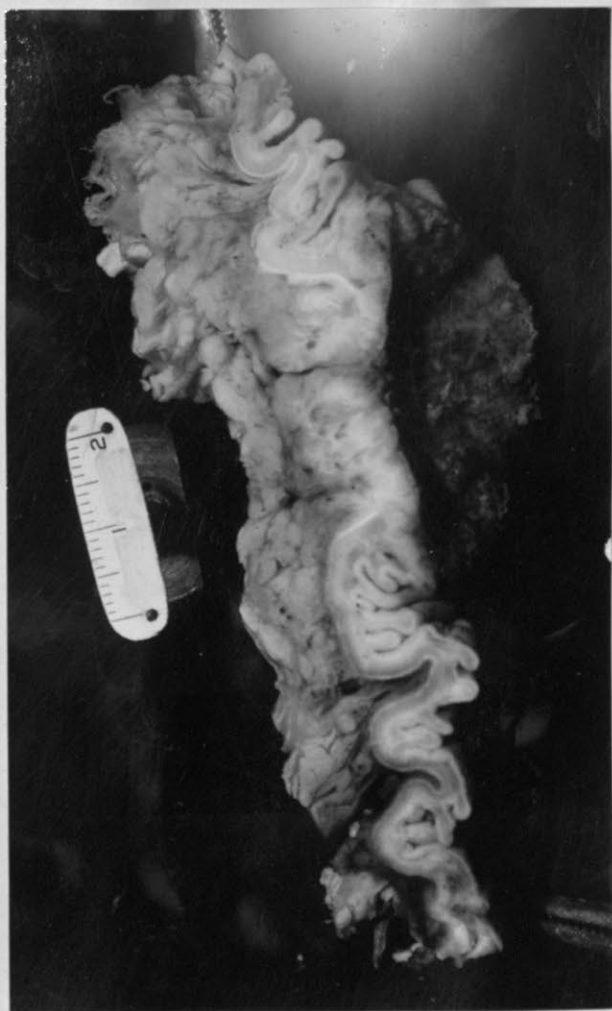


Plate XVI. Group I.
Case 223299.



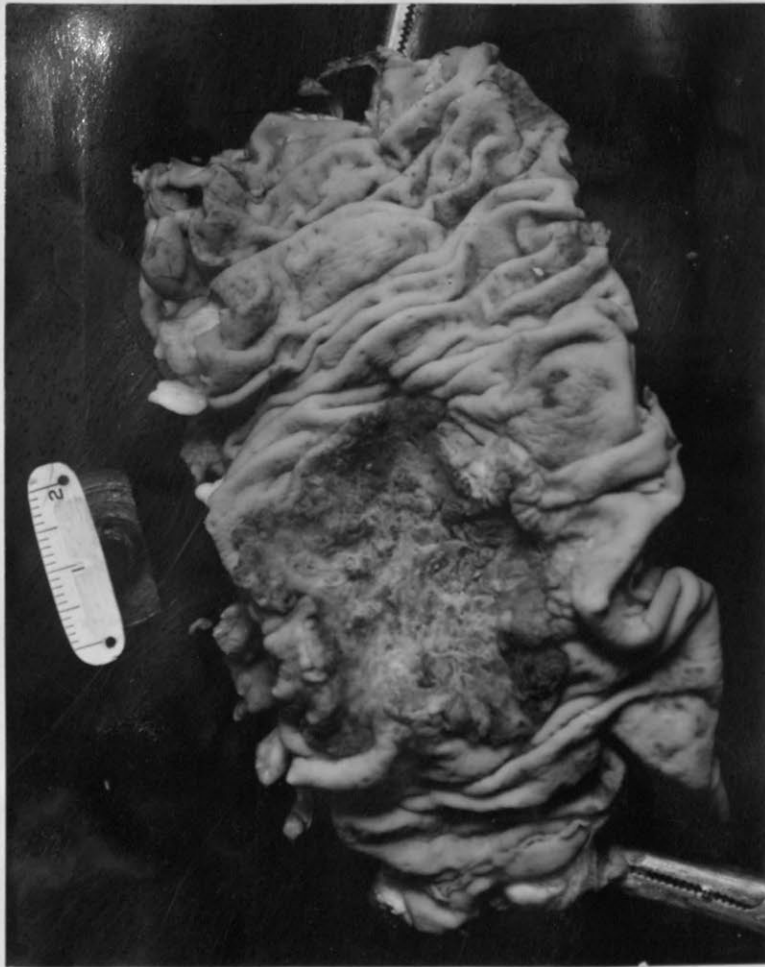

Plate XVII. Group I. Case 268339.



b. Plate XVII. Group I. Case 268339.

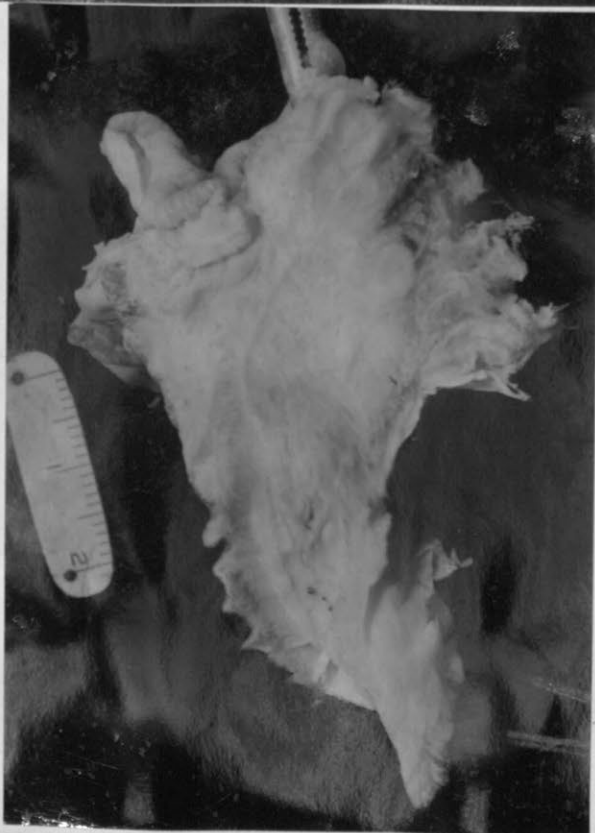
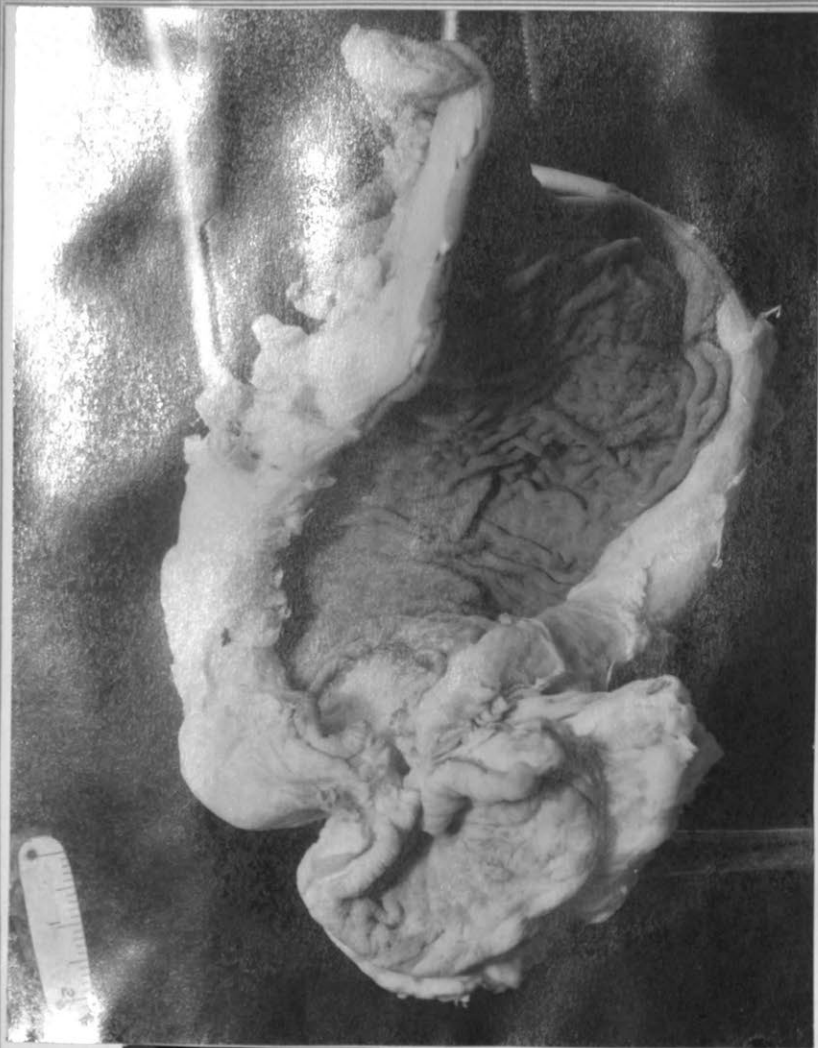
Plate XVIII. Group I.
Case 261807.

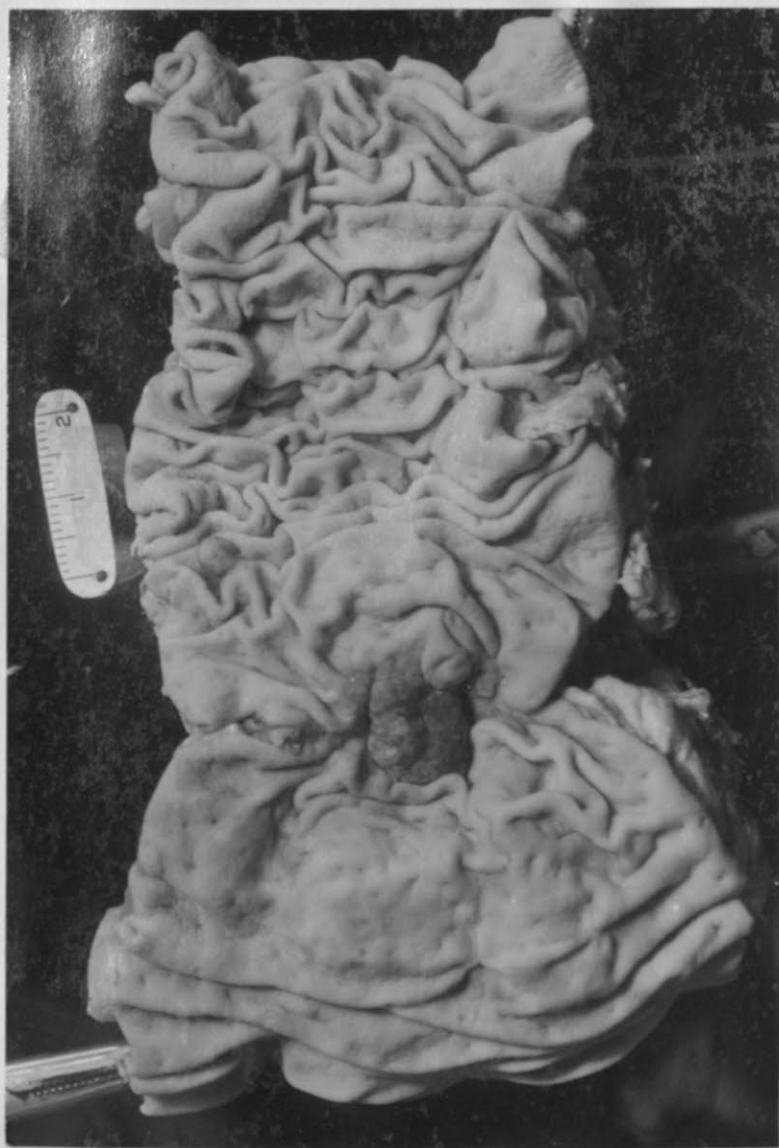
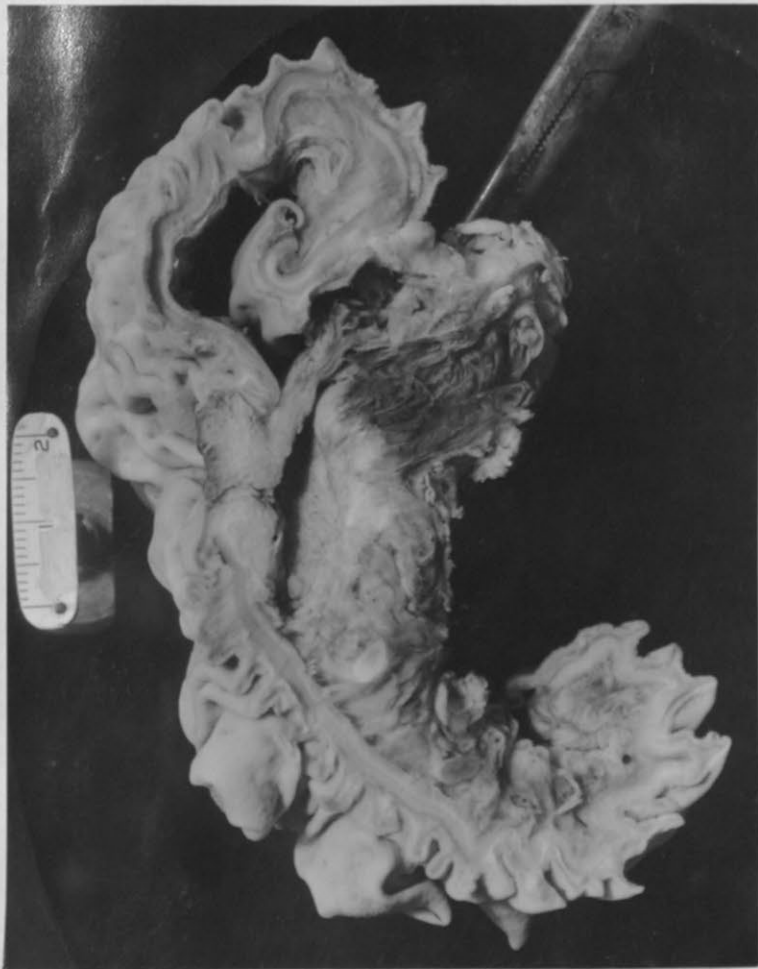
Plate XIX. Group I. Case 246503.



b. Plate XIX. Group I. Case 246503

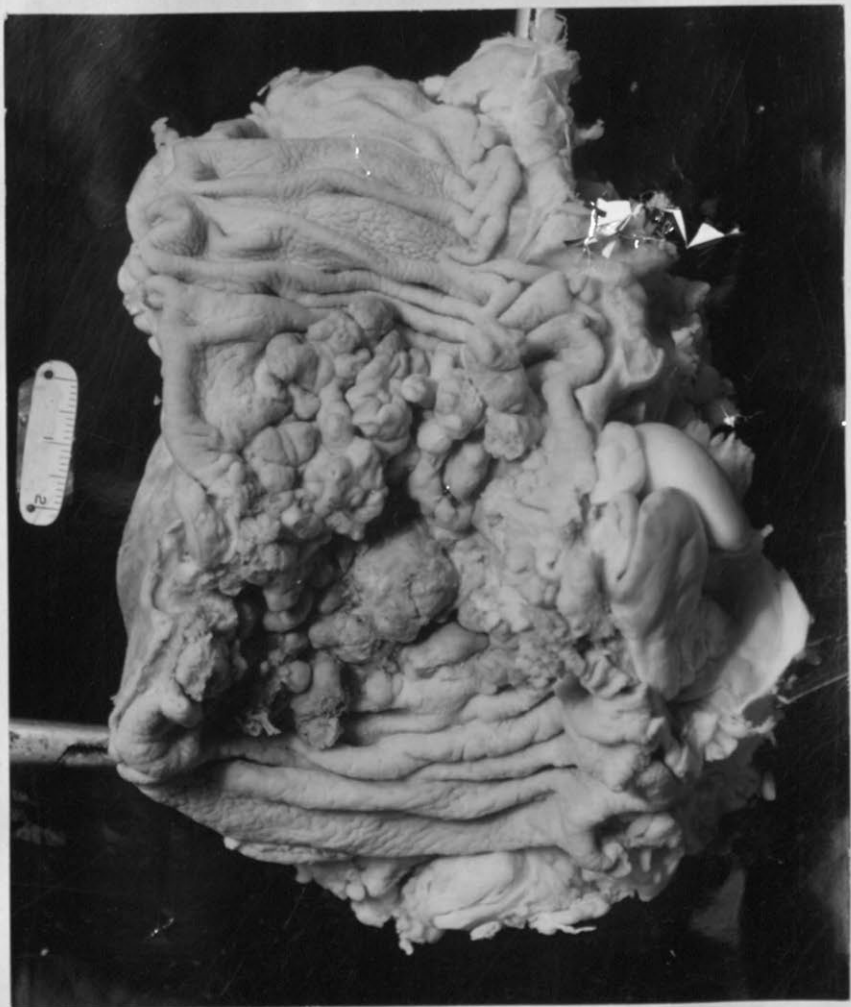
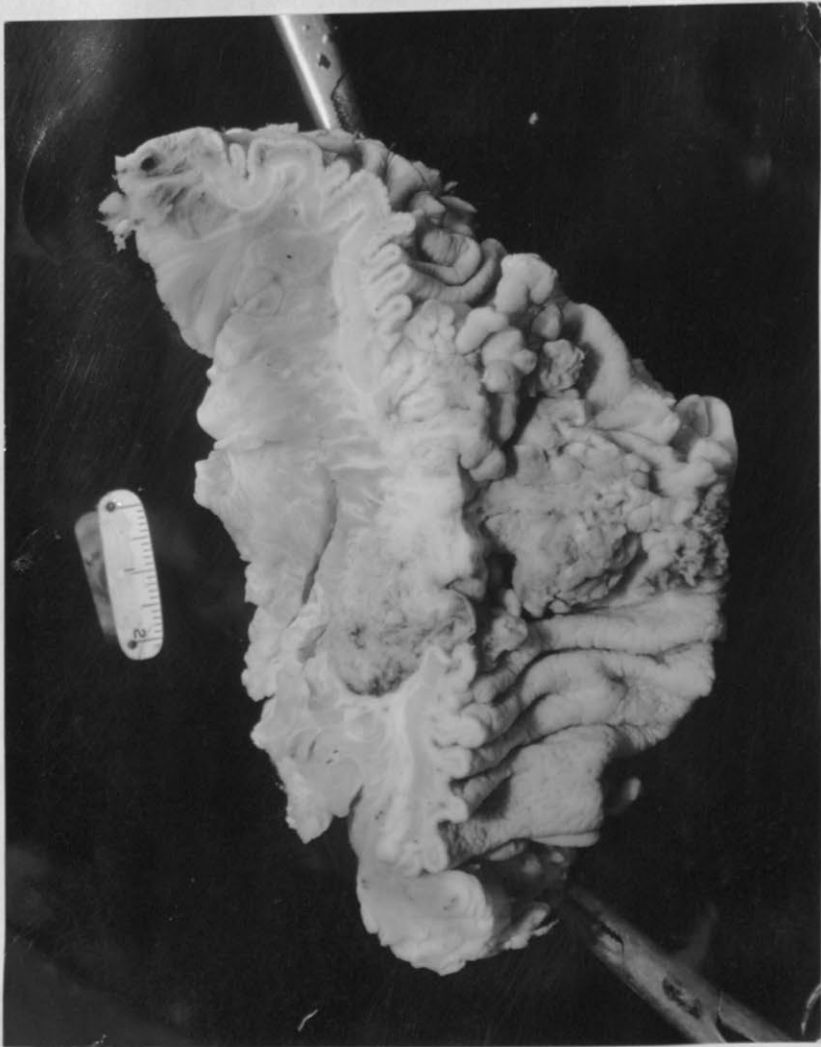


Plate XX. Group I. Case 268852



b. Plate XX. Group I. Case 268852.

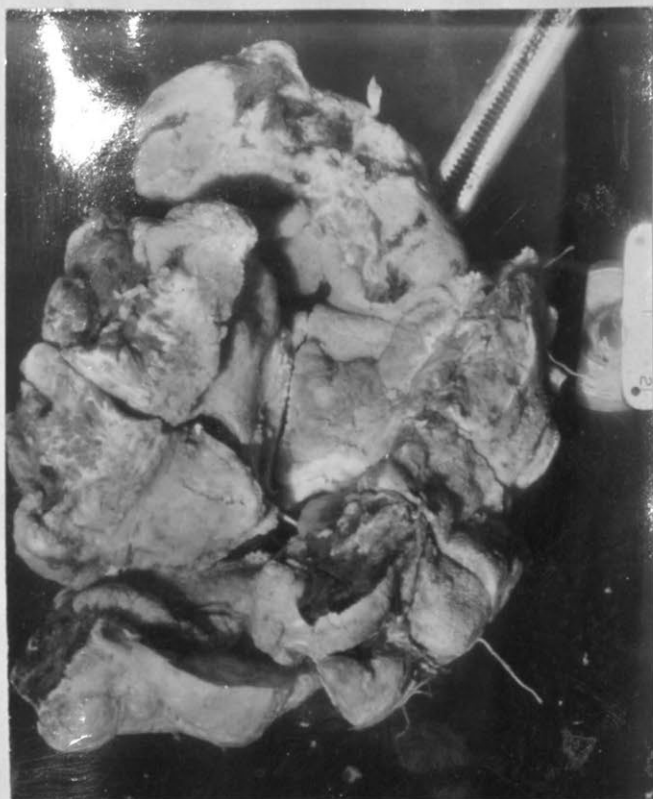
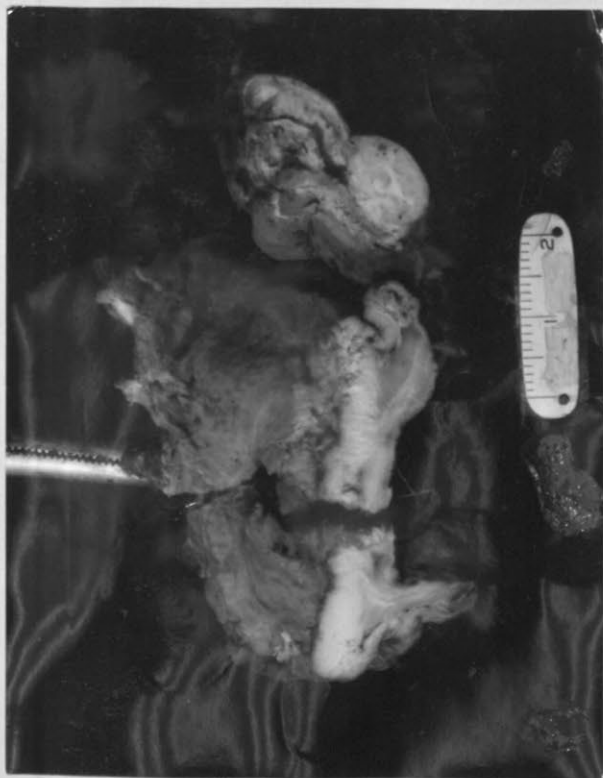
Plate XXI. Group I. Case 230093



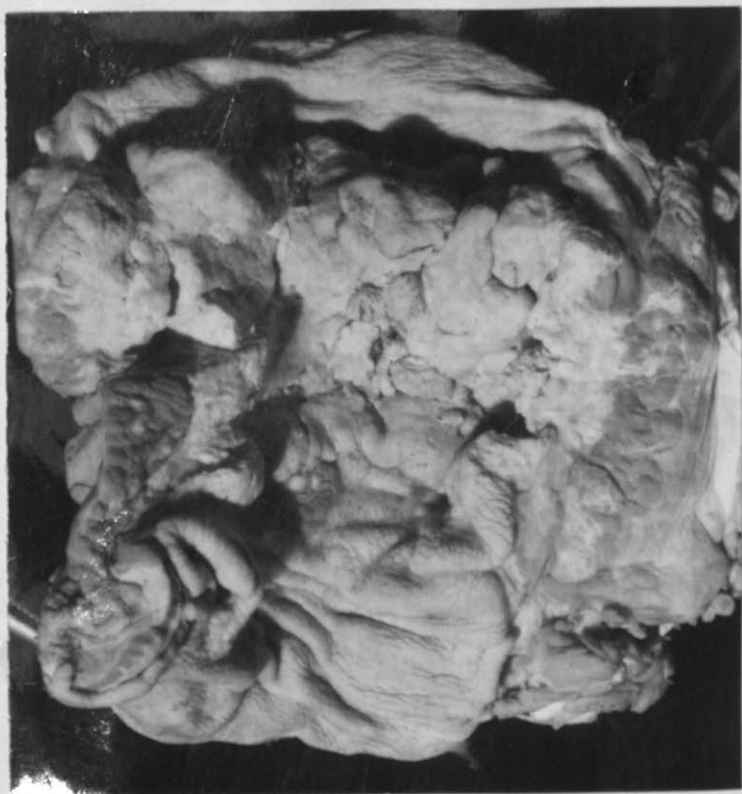

Plate XXII. Group I.
Case 237535.



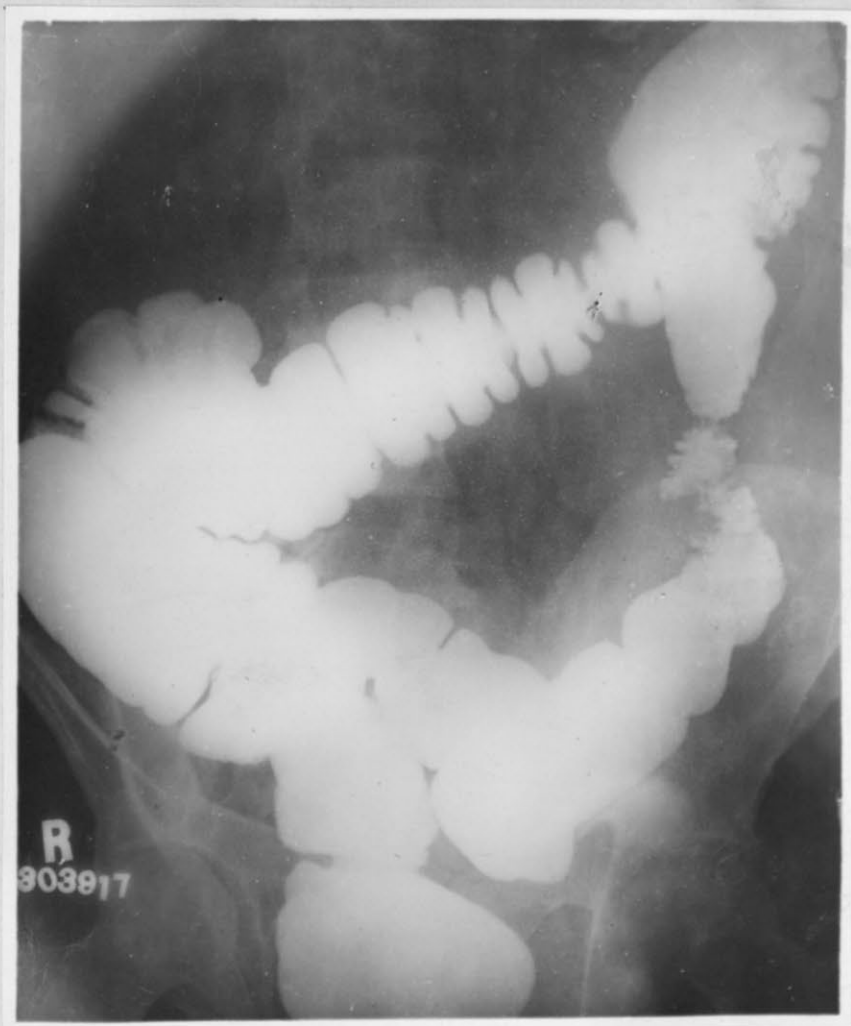


Plate XXIII. Group I. Case 303917.

Filling defect in Carcinoma of Descending Colon.

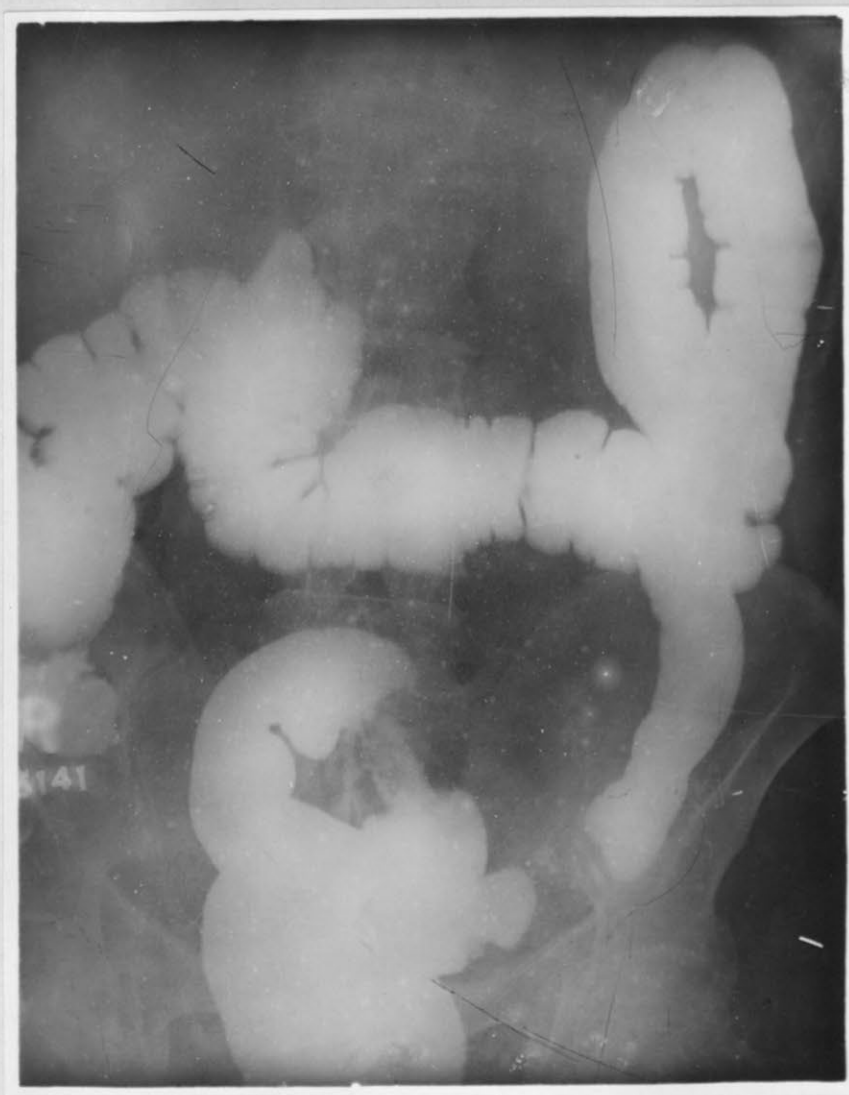

Plate XXIV. Group I. Case 245141.

Filling defect in Carcinoma of the
Sigmoid Flexure.

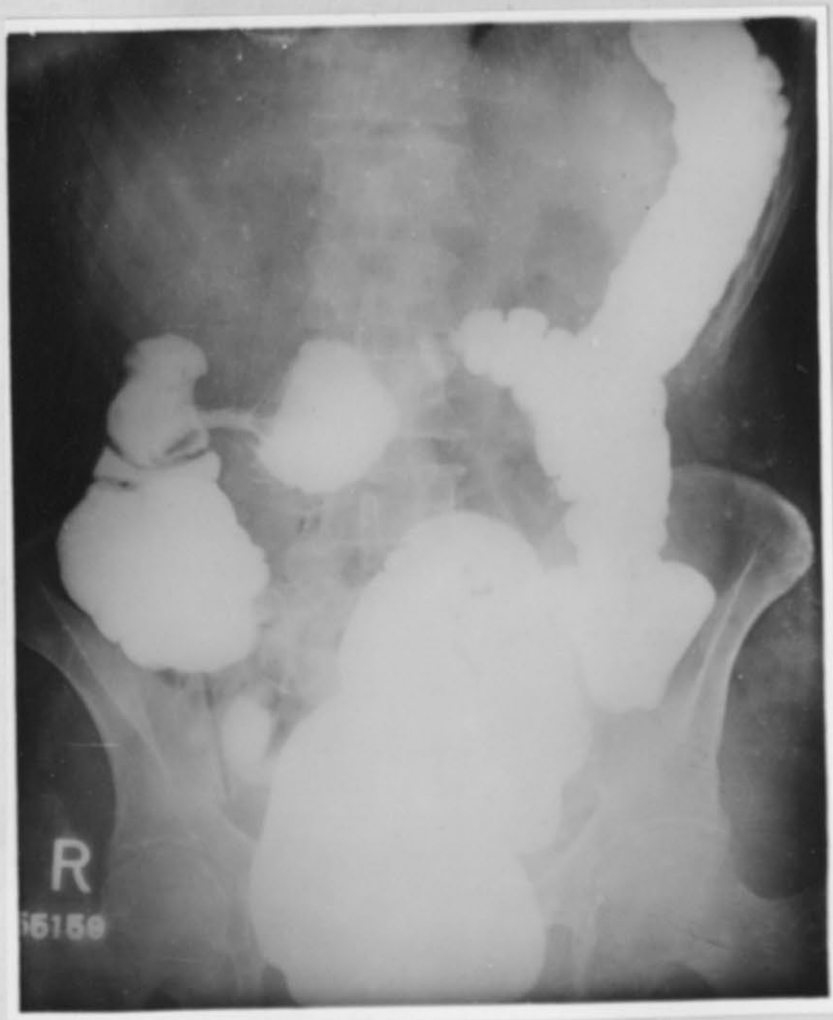

Plate XXV. Group I. Case 255159.

Filling defect in Carcinoma of
the Transverse Colon.

Group II. Cases of carcinoma of the large intestine with metastatic involvement of one or more of the regional lymph glands.

There were thirty-seven cases, or thirty-seven percent in this group. Nineteen were males and eighteen females. The average age was 52.12 years, and the average duration of symptoms was 10.6 months. The average number of glands per specimen was 16.75. The sex, age, duration of symptoms, number of glands found and the number of glands involved in each specimen is shown in Table III. (page 52). The diagrams of the glands and growths are shown in plates XXVI-XXIX inclusive (pp. 53-57). Plates XXX to XXXIX inclusive (pages 57-69) show photographs of typical specimens of the group. Plates XL to XLII inclusive (pages 69-71) show x-ray photographs of some of the typical filling defects, before operation, in three cases of this group.

As in Group I it may be seen from the photographs and diagrams, that the size of the growth bears little or no relation to the amount of glandular involvement. Here it is evident that the ulcerative type of growth is more prevalent than the protuberant type which appeared more frequently in Group I. In this group of forty-seven cases the napkin ring or annular form of carcinoma appeared nine times. Many other cases gave the appearance of the annular form, because of a constricting ring, following marked degeneration and resulting scar tissue on one or two sides of the bowel. In the cross section it is seen that there is a marked tendency for the growth to extend into the muscle and fatty tissue surrounding the bowel wall. In this way the carcinoma frequently extended to and involved other organs such as the bladder, ovary, and uterus.

The diagrams show also that the gland or glands usually involved, are those nearest the point of greatest direct extension of the growth. Occasionally a large gland at this point, which, macroscopically, one would be quite certain was carcinomatous, on microscopic examination proved to be inflammatory, while one a little more distant proved to be carcinomatous. This is more clearly shown in plates LXI-LXIX inclusive (pages 88-96) which will be discussed later.

TABLE III.

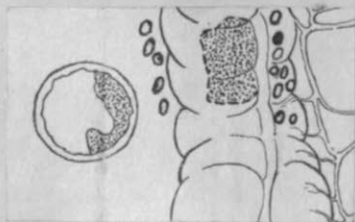
Group II.

Case No.	Sex.	Age	Duration of symptoms in months.	Total No. Glands.	No. neg.	No. pos.
225884	M	35	2	13	12	1
290052	M.	67	3	15	14	1
262214	M	52	17	7	10	7
293388	M	50	12	3	1	2
68010	M	56	12	13	10	3
289884	F	42	12	7	6	1
232689	M	49	?	11	10	1
187449	M	54	6	36	33	3
187304	F	49	?	10	8	2
299184	M	50	24	12	11	1
209414	M	54	12	15	2	13
212612	M	46	18	15	10	5
248261	F	54	8	12	10	2
228847	F	50	6	15	14	1
212591	M	60	12	16	15	1
212495	F	29	2	7	6	1
294795	F	56	2 $\frac{1}{2}$	20	19	1
245141	M	67	6	8	7	1
321367	M	56	3	13	11	2
295180	F	51	8	24	21	3
79425	F	54	6	10	8	2
143179	M	62	6	14	4	10
146908	M	57	4	42	39	3
208521	M	57	9	12	9	3
168215	F	65	12	18	17	1
315878	F	31	?	18	14	1
297128	F	48	30	14	13	1
315119	F	45	11	25	23	2
187084	F	51	?	18	11	7
90799	F	58	30	15	13	2
129246	F	57	6	32	27	5
329174	F	52	?	7	6	1
298031	F	60	3	10	9	1
215439	M	51	11	12	10	2
216233	M	46	12	25	24	1
213582	M	60	30	31	30	1
279654	F	55	6	17	10	7

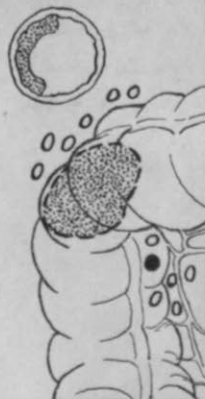Female 18 Av. age 52.1
Male 19

Av. no. 16.75 524 95

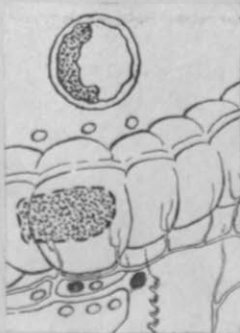
Case 290052. Upper sigmoid. Inner wall. 5 by 5 cm.



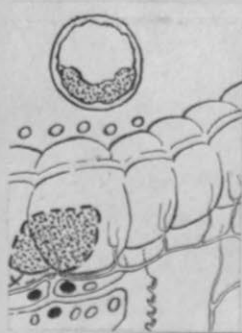
Case 299184. Hepatic flexure. Outer wall. 4 by 5 cm.



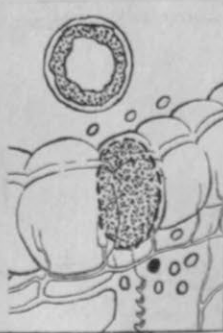Case 187304. Right transverse colon. Anterior wall. 4 by 6 cm.



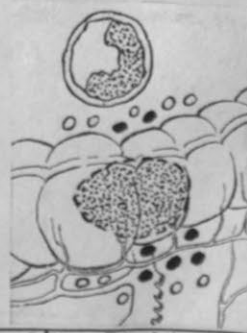Case 68010. Right transverse colon. Lower wall. 4 by 7 cm.



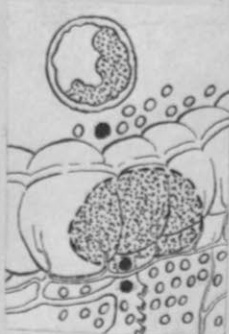Case 298031. Middle transverse. Encircling. 3 cm. in diameter.



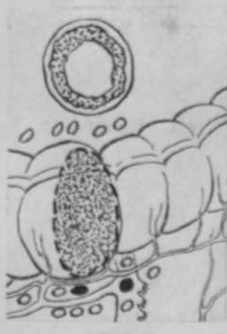Case 187084. Middle transverse colon. Posterior wall. 9 by 9 cm.



Case 187449. Middle transverse. Anterior wall. 12 cm. in diameter.



Case 90799. Right transverse colon. Encircling. 7 by 8 cm.



Case 143179. Right transverse colon. Upper wall. 4 by 7 cm.



Plate XXVI. Group II. Diagrams showing position of glands and growths. Glands not involved in clear circles. Glands involved in solid black.

Dr. J. Hayes.

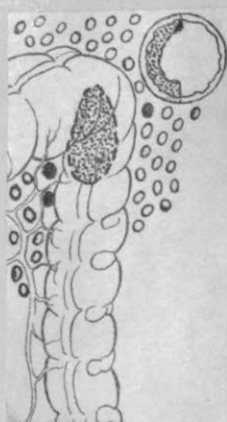Thesis.

Mar 20, 1921

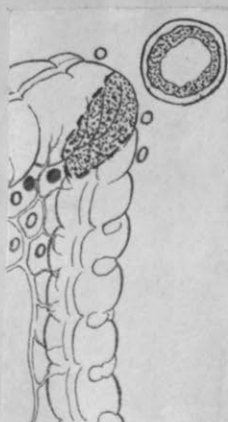
no 3487

PHOTOGRAPHED

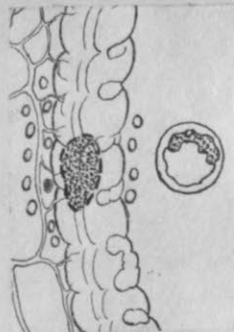
Case 146908. Splenic flexure. Anterior wall. 6 by 8 cm.



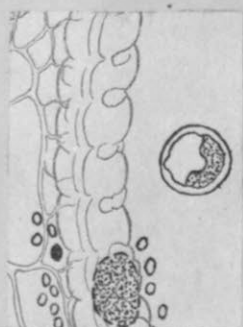
Case 79425. Splenic flexure. Encircling. 4 by 6 cm.



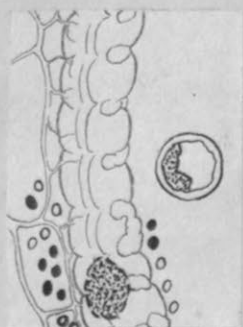
Case 315878. Middle descending colon. Anterior wall. 6 by 2 cm.



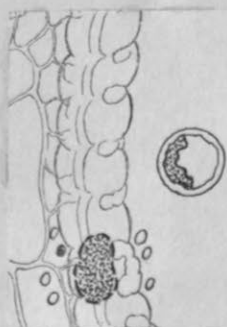
Case 293388. Lower descending colon. Outer wall. 6 by 10 cm.



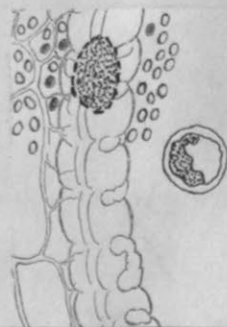
Case 279654. Lower descending colon. Anterior wall. 5 by 8 cm.



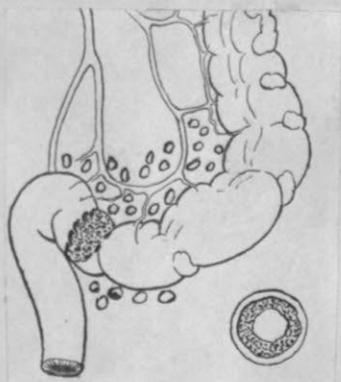
Case 329174. Lower descending colon. Anterior wall. 3 cm. in diameter.



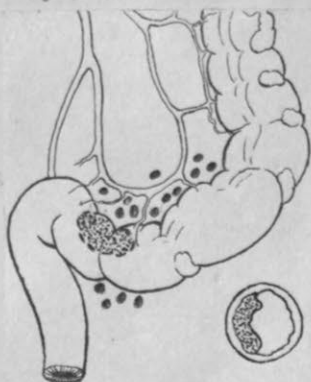
Case 129246. Upper descending colon. Anterior wall. 10 cm. in diameter.



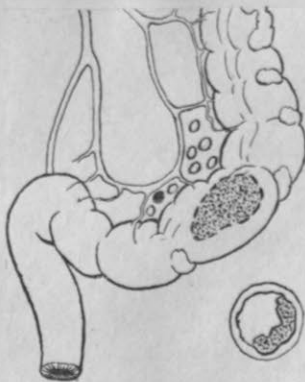Case 315119. Lower sigmoid. Encircling. 5 cm. in diameter.



Case 209414. Lower sigmoid. Inner wall. 6 by 9 cm.



Case 245141. Upper sigmoid. Posterior wall. 5 cm. in diameter.



Dr. J. Hayes

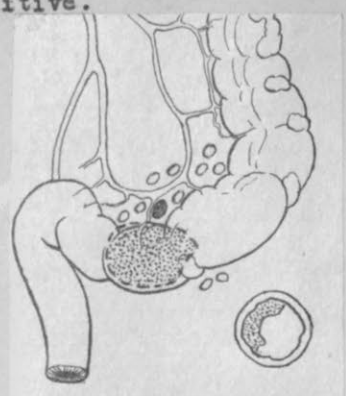
Thesis.

Mar. 20, 1921

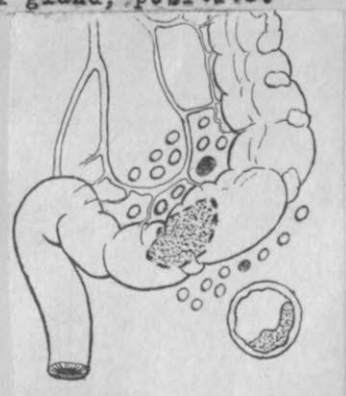no. 3488

PHOTOGRAPHED

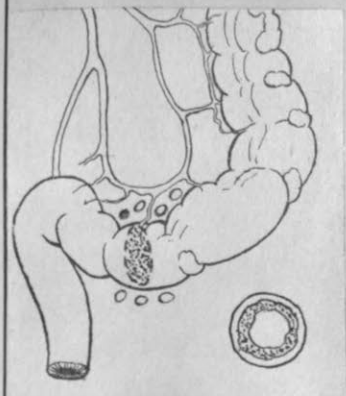
Case 232689. Lower sigmoid.
Inner wall. 8 by 9 cm.
10 glands, negative; 1 gland,
positive.



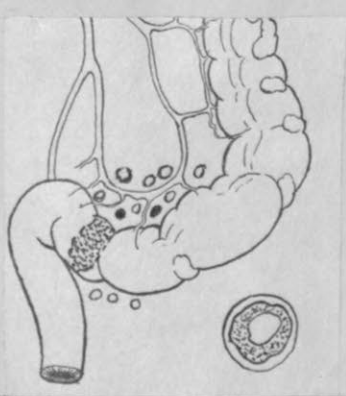
Case 294795. Middle sigmoid.
Posterior wall. 5 by 6 cm.
19 glands, negative;
1 gland, positive.



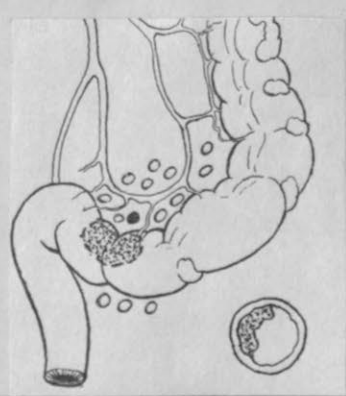
Case 262214. Lower sig-
moid. Encircling.
8 cm. in diameter.



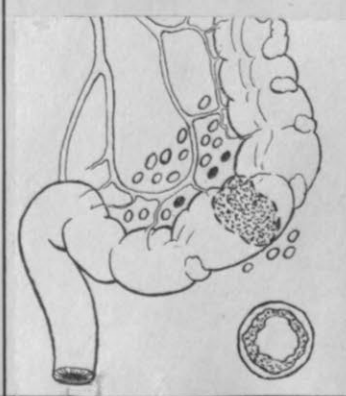
Case 248261. Lower sigmoid.
Encircling. 6 by 8 cm.



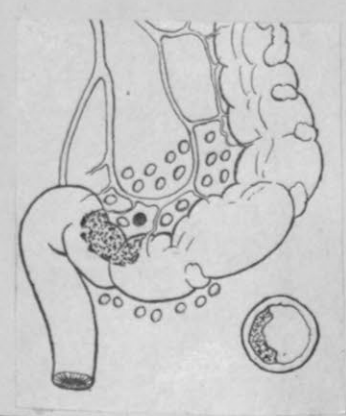
Case 297128. Lower sigmoid.
Inner wall. 6 by 8 cm.



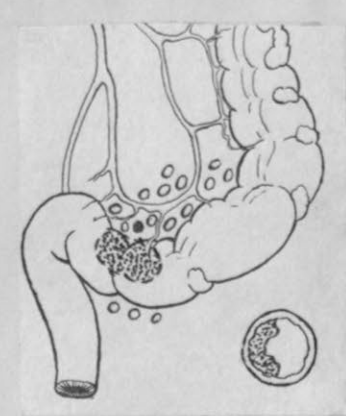
Case 295180. Upper sig-
moid. Encircling.
3 cm. in diameter.



Case 216233. Lower sigmoid.
Inner wall. 4 by 6 cm.



Case 212591. Lower sigmoid.
Inner wall. 5 by 9 cm.



Case 321367. Middle sig-
moid. Posterior wall.
5 by 5 cm. 11 glands, neg-
ative; 2 glands, positive.

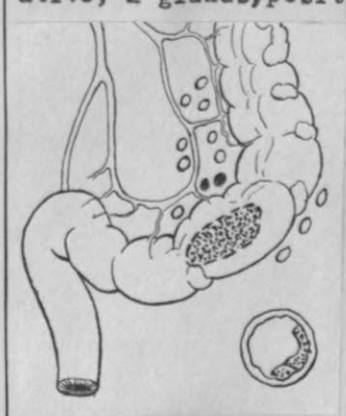

Plate XXVIII. Group II. (Legend Plate XXVI).

Mr J. Hayes

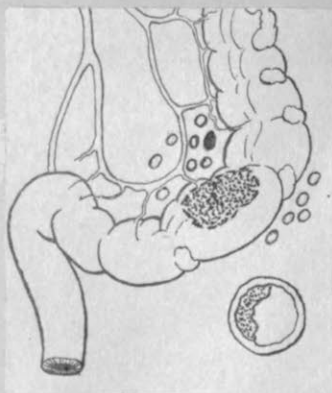Thesis

Mar 1921

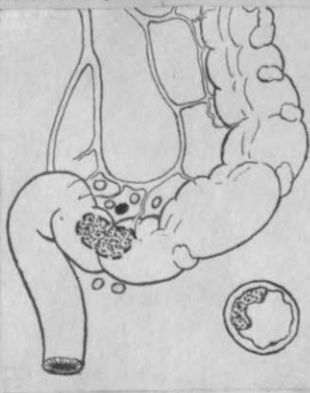No 3489

PHOTOGRAPHED

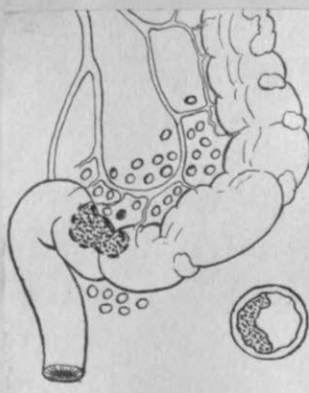Case 225884. Upper sigmoid. Inner wall. 6 by 8 cm.



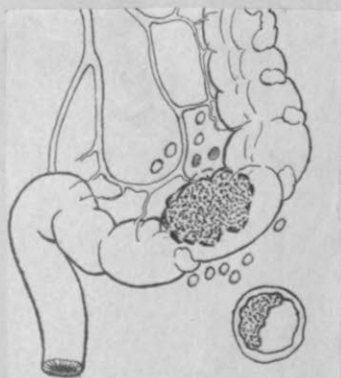
Case 289884. Lower sigmoid. Posterior wall. 6 cm. in diameter.



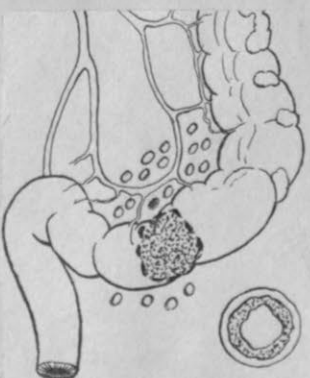
Case 213582. Lower sigmoid. Inner wall. 8 by 10 cm.



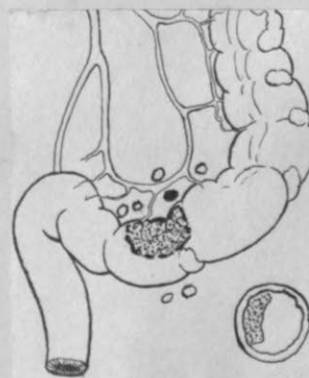Case 215439. Upper sigmoid. Inner wall. 12 cm. in diameter.



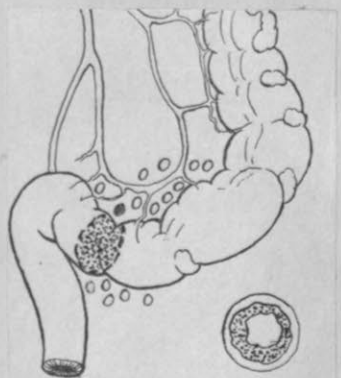
Case 168215. Middle sigmoid flexure. Encircling. 5 by 8 cm.



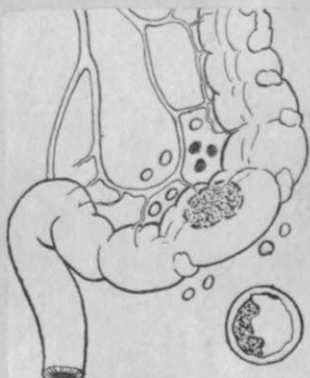Case 212495. Middle sigmoid. Anterior wall. 4 by 7 cm.



Case 228847. Lower sigmoid. Encircling. 4 by 6 cm.



Case 208521. Upper sigmoid. Inner wall. 10 cm. in diameter.



Case 212612. Upper sigmoid. Anterior wall. 5 by 8 cm.

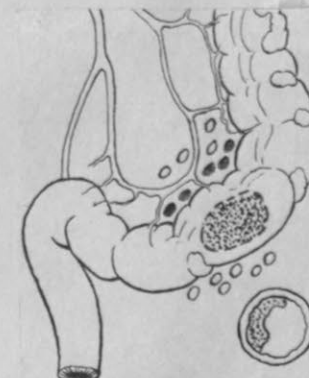

Plate XXIX. Group II. (Legend Plate XXVI).

W. J. Hayes
Thesis

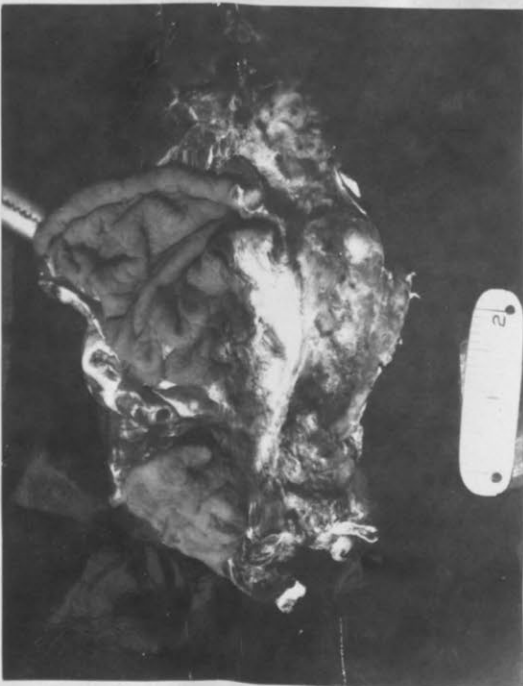
Mar. 26, 1921

No. 3490.

PHOTOGRAPHED

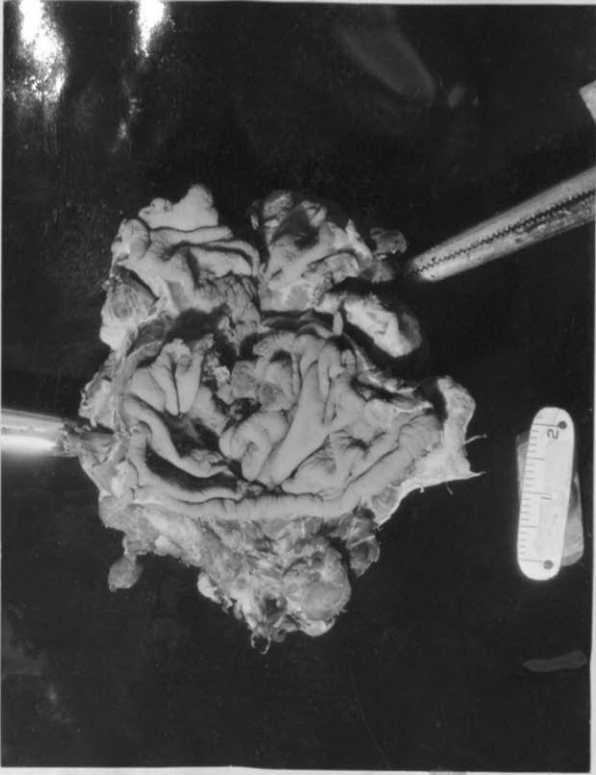

Plate XXX. Group II. Case 262214



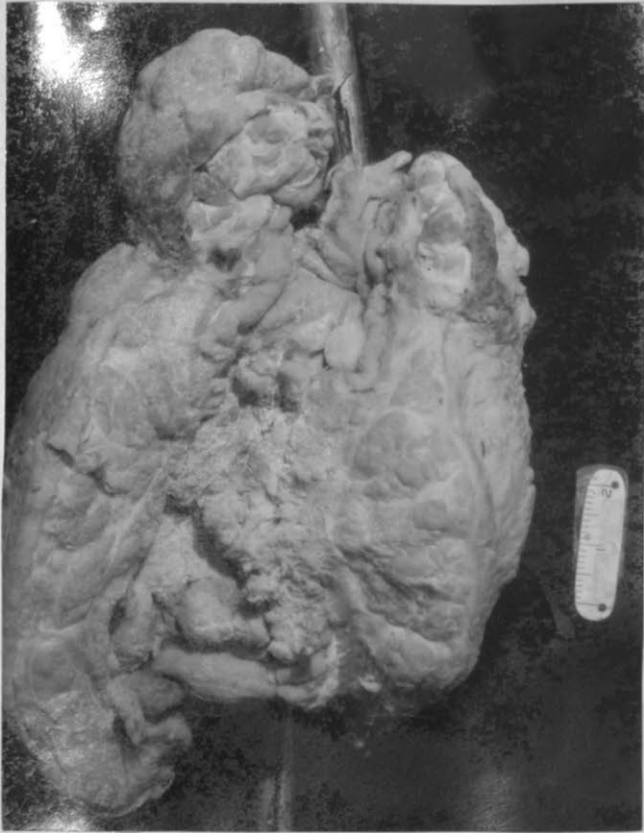
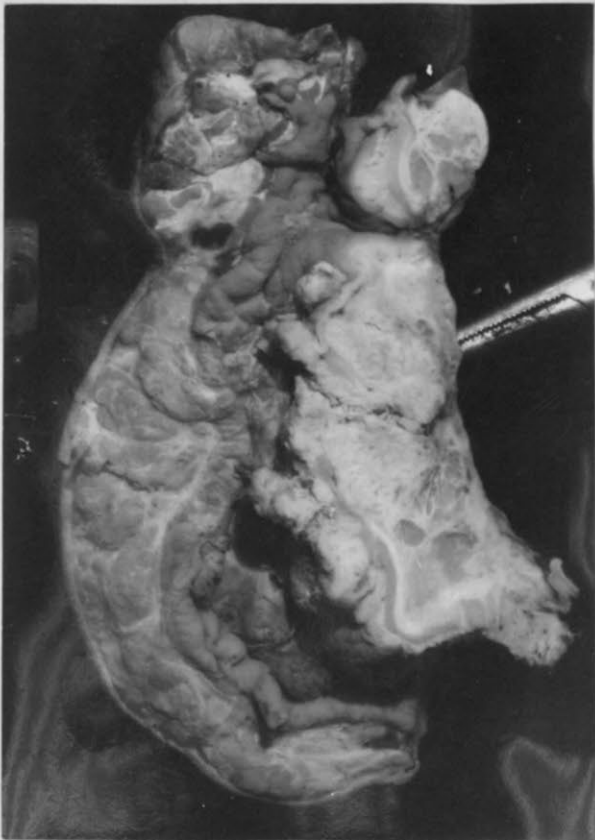

Plate XXXI. Group II. Case 289884



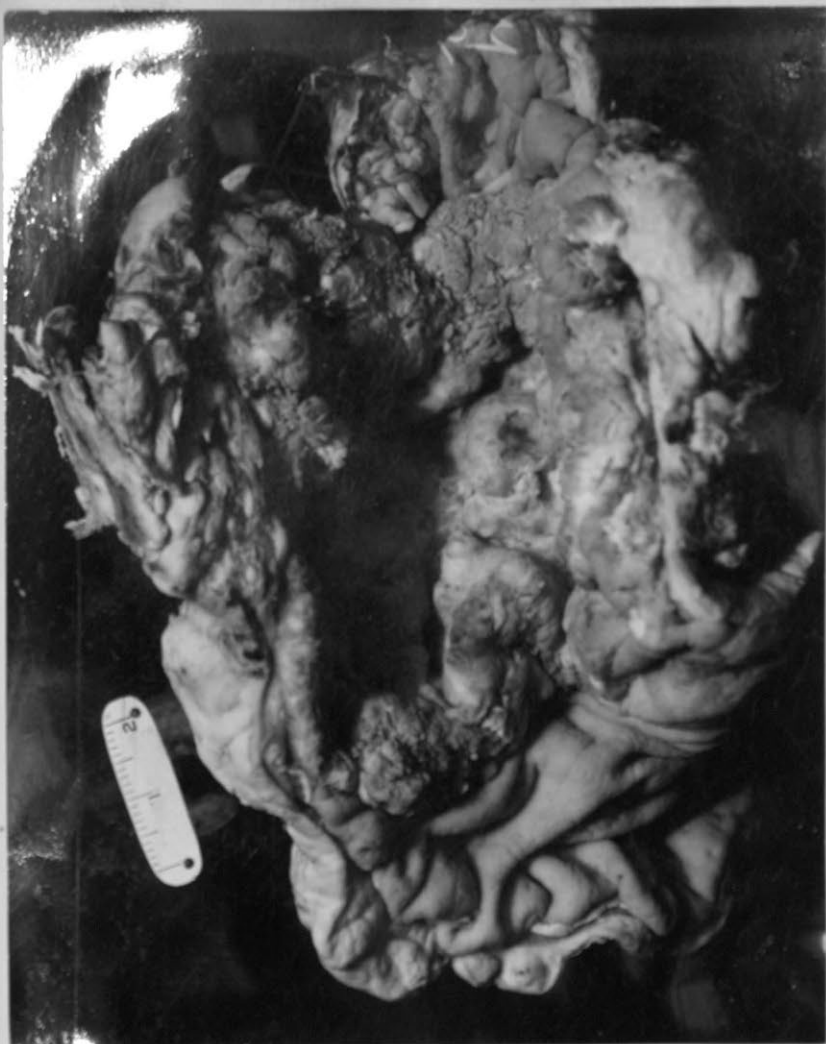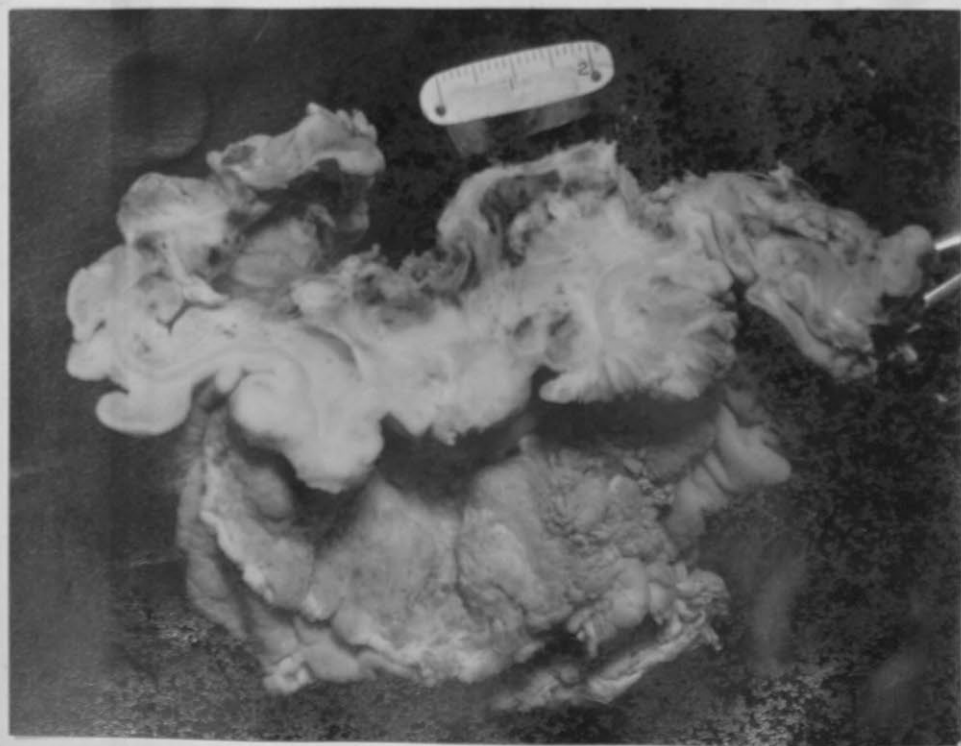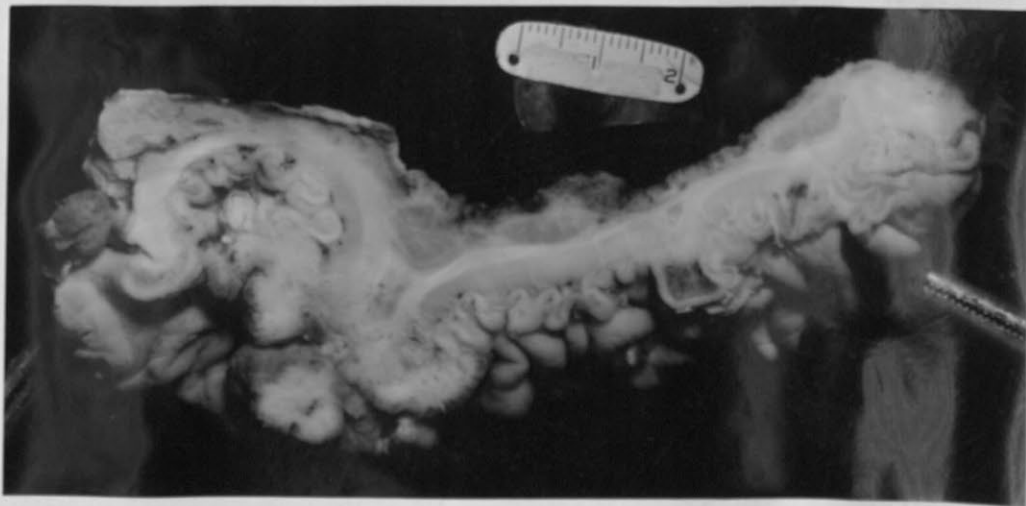


Plate XXXII. Group II.
Case 293388. *Carcinoma of the*



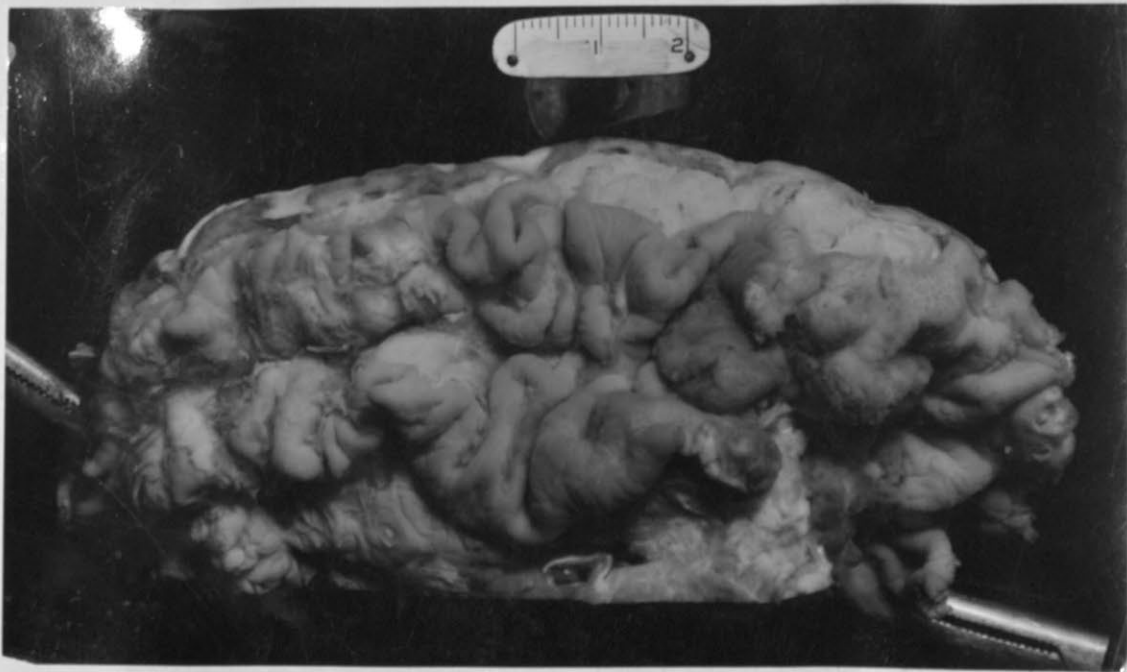

Plate XXXIII. Group II.
Case 321367.



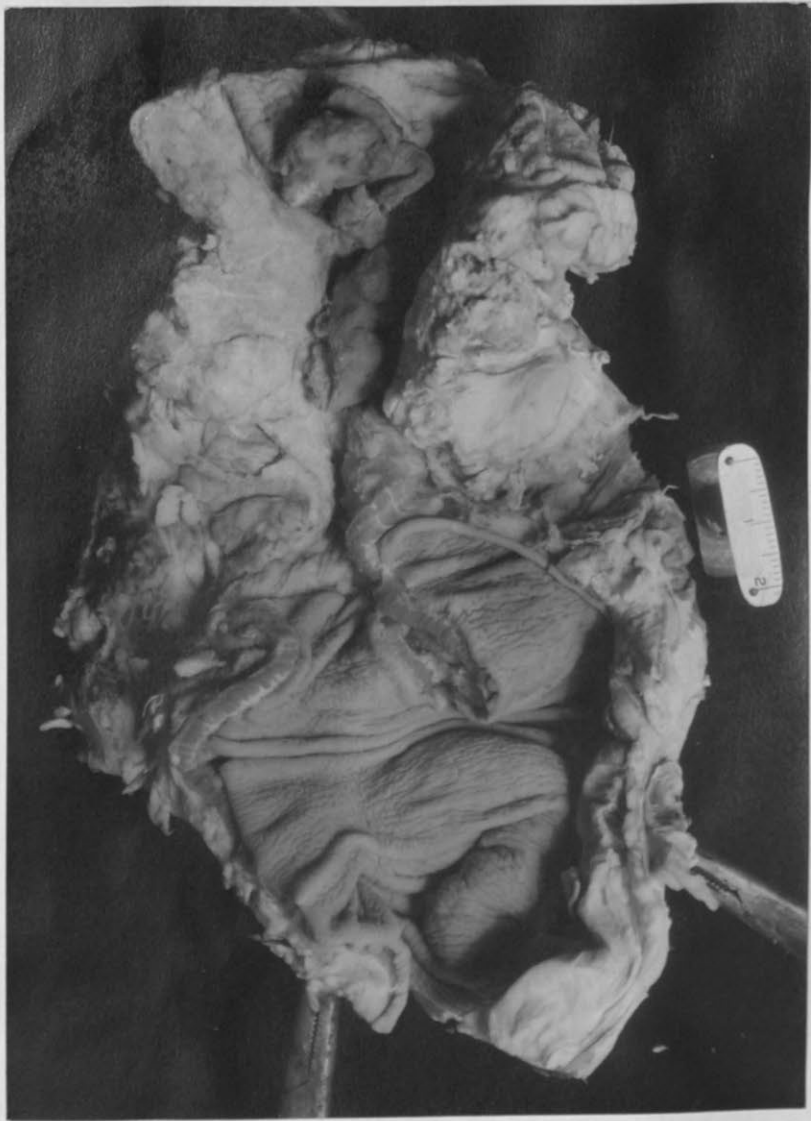
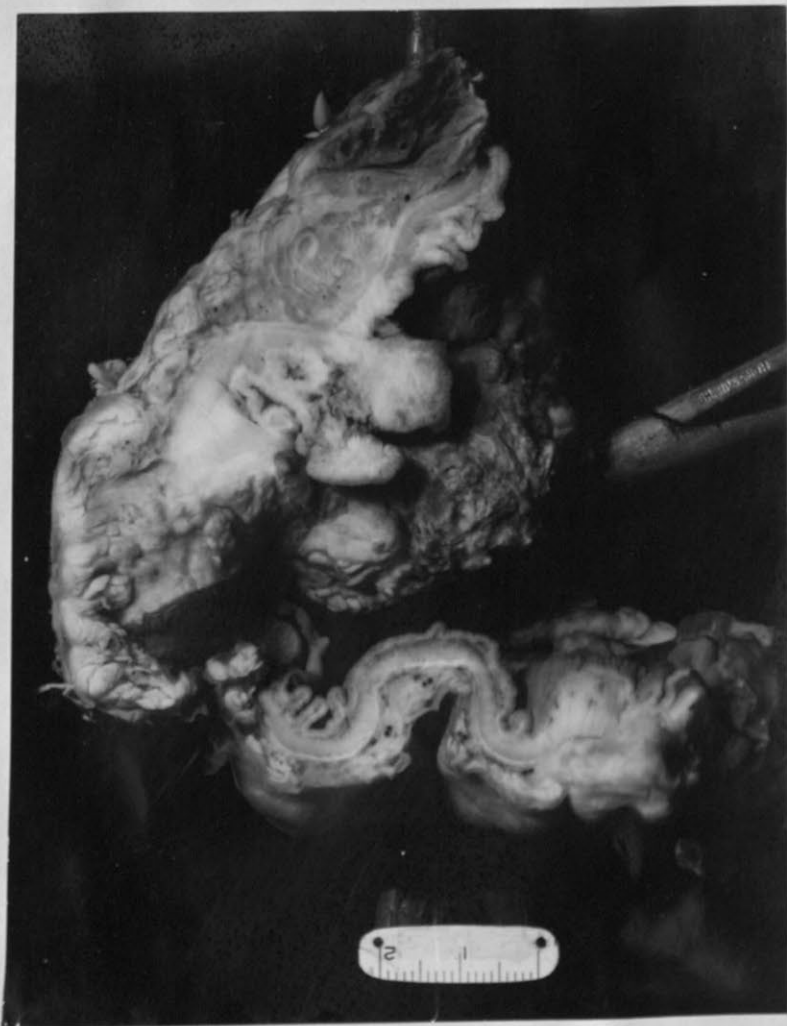

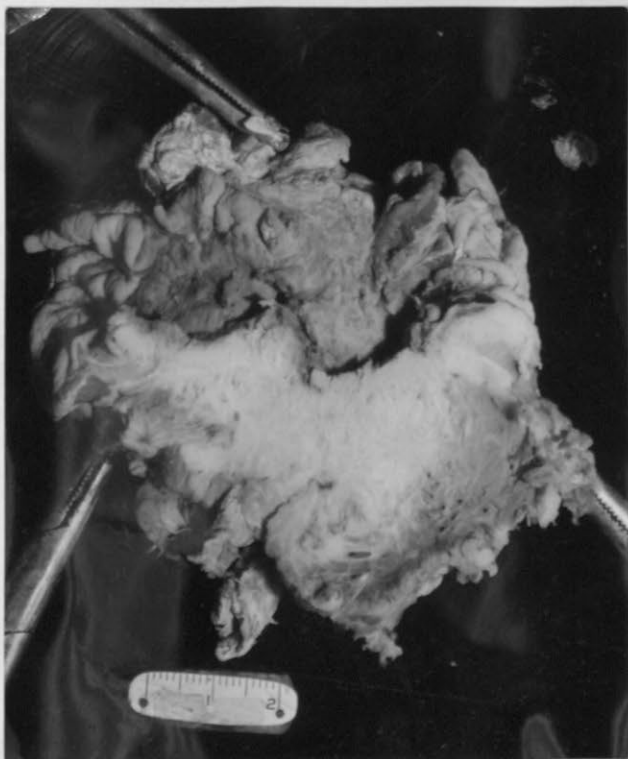
Plate XXXIV. Group II. Case 248261.



b. Plate XXXIV. Group II. Case 248261.

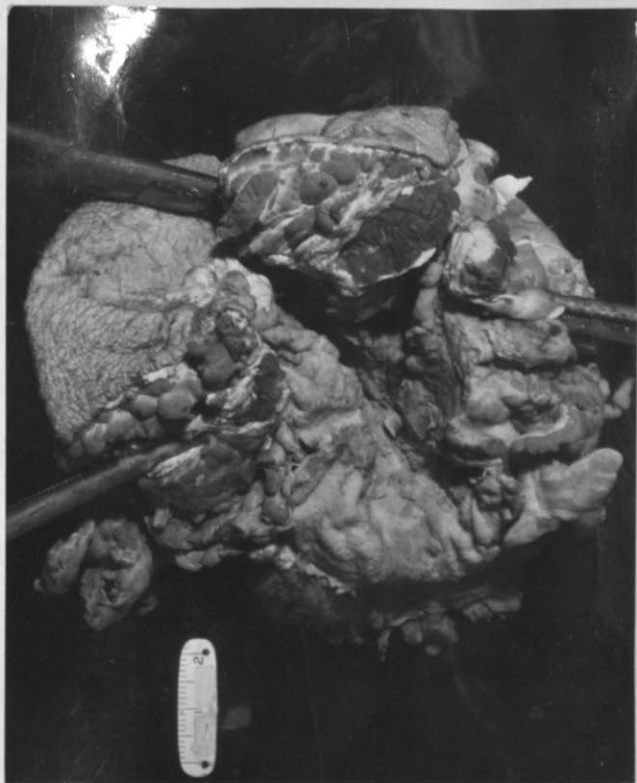

Plate XXXV. Group II.
Case 225884.



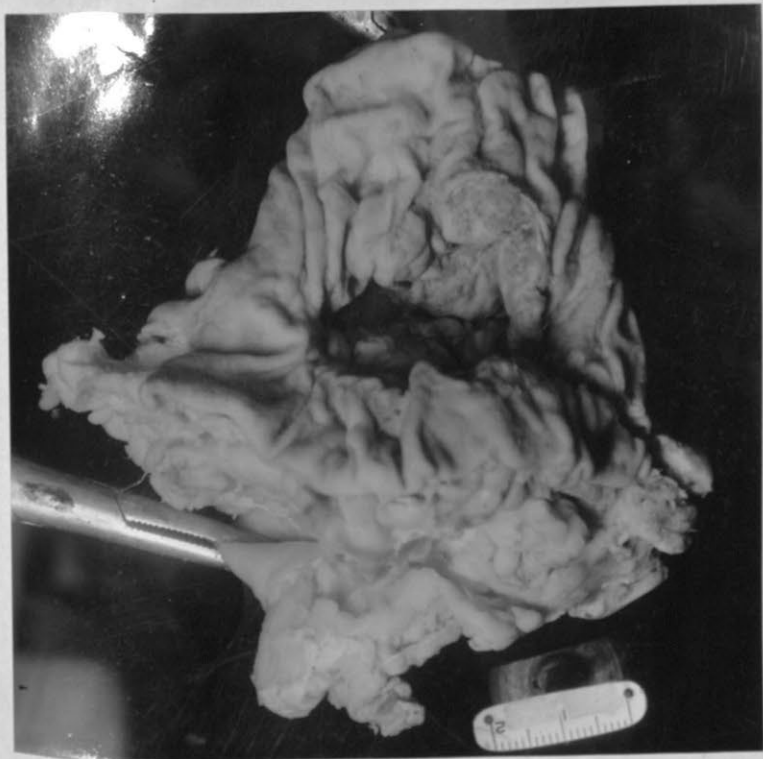
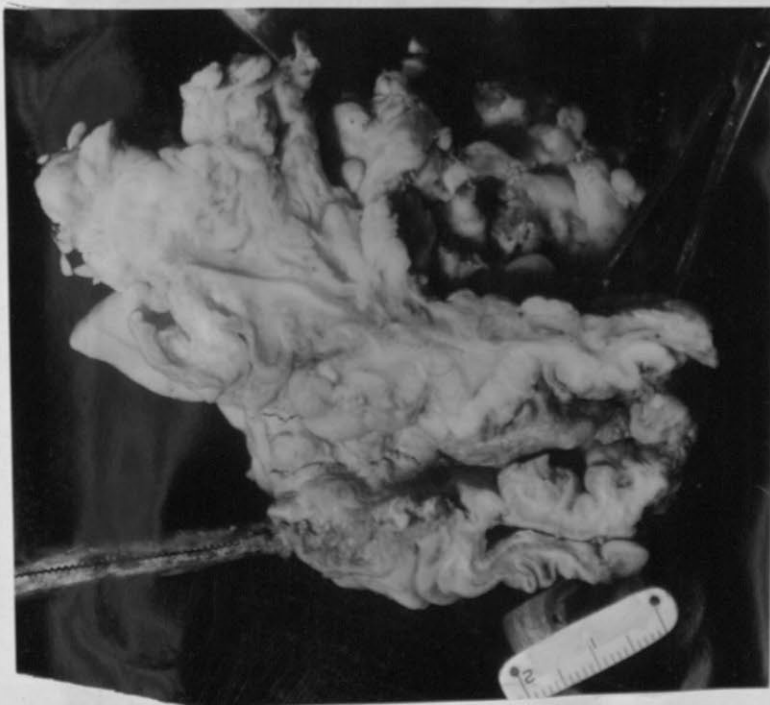

Plate XXXVI. Group II.
Case 68010.



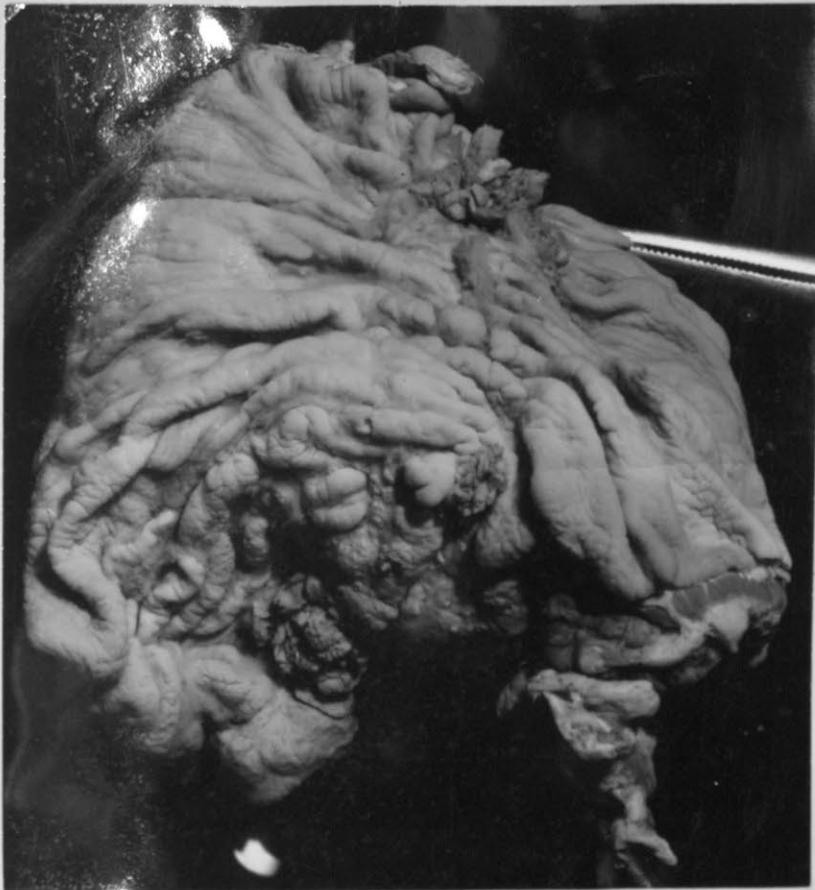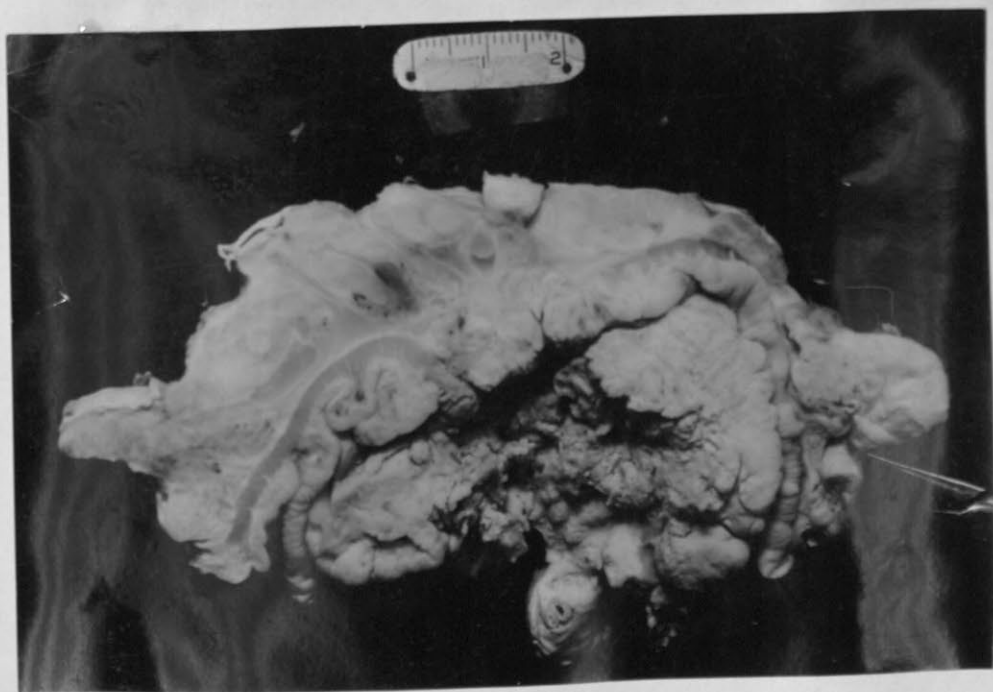


Plate XXXVII. Group II.
Case 232689.



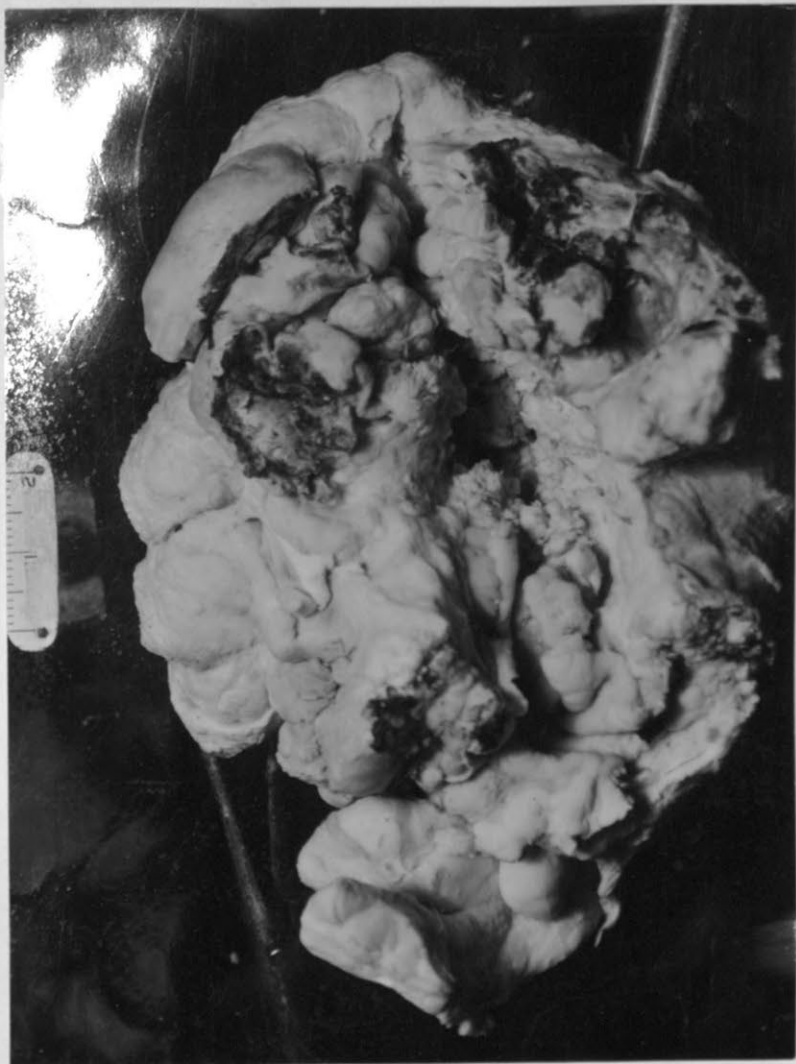

Plate XXXVIII. Group II.
Case 228847.



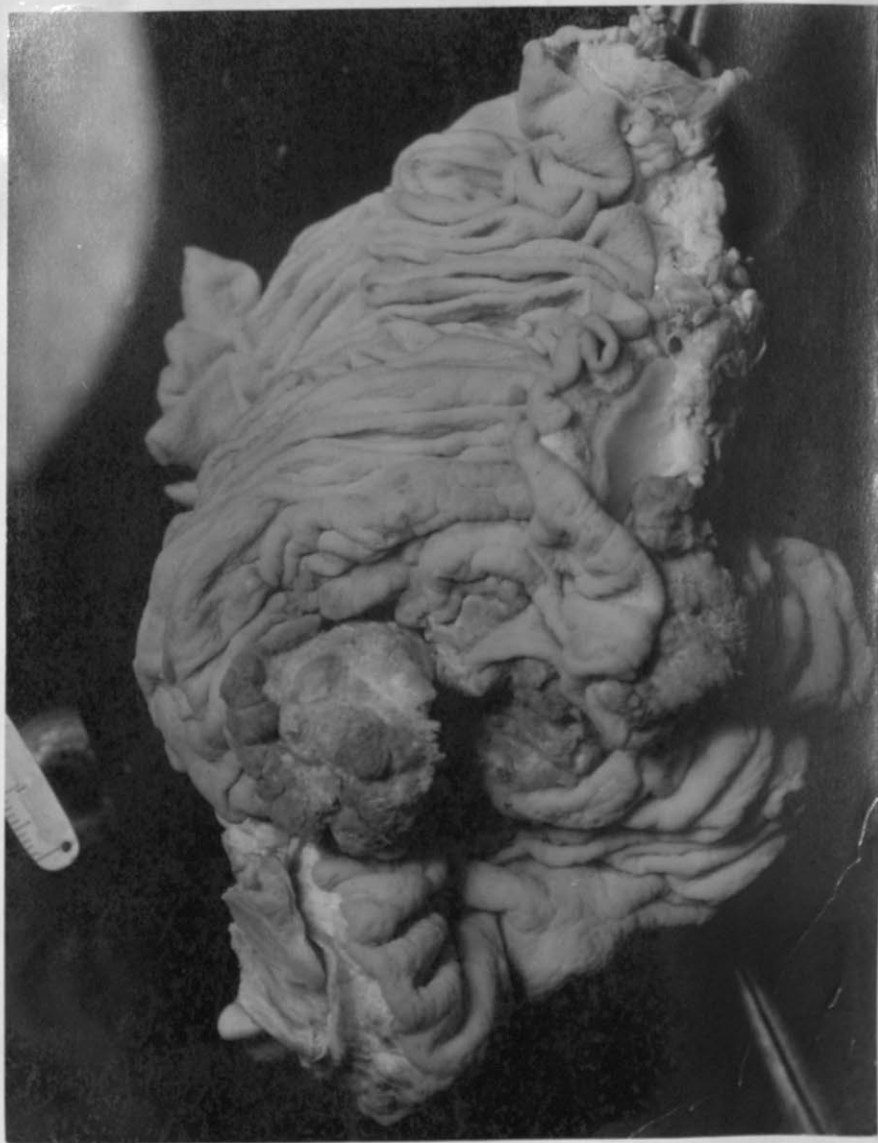
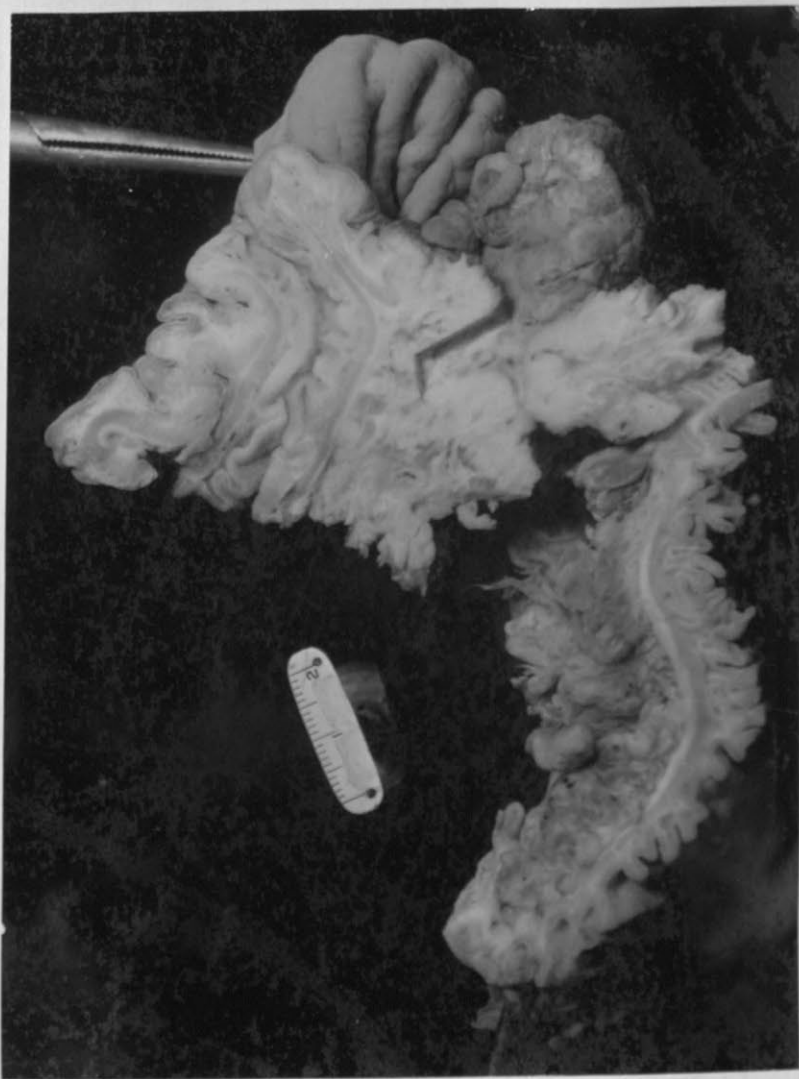

Plate XXXIX. Group II. Case 290052.



b. Plate XXXIX. Group II. Case 290052.

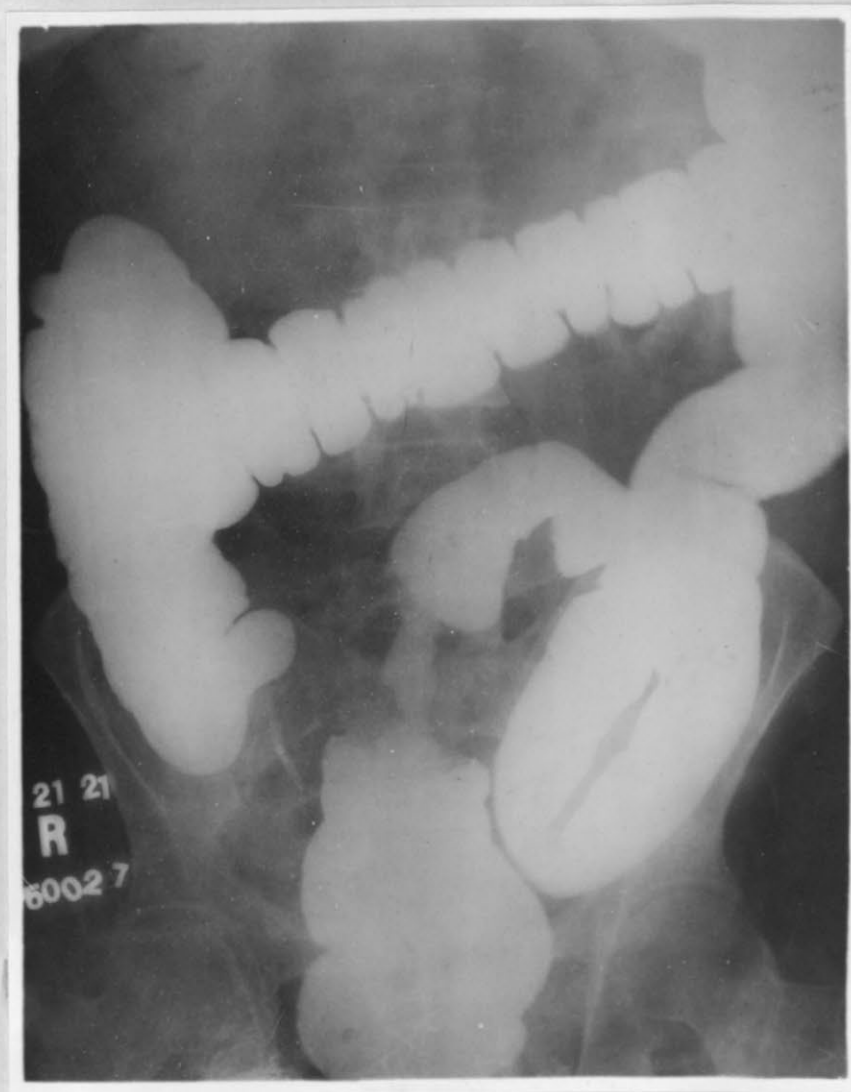


Plate XL. Group II. Case
350027.
Filling defect in Carcinoma
of the Recto-sigmoid.

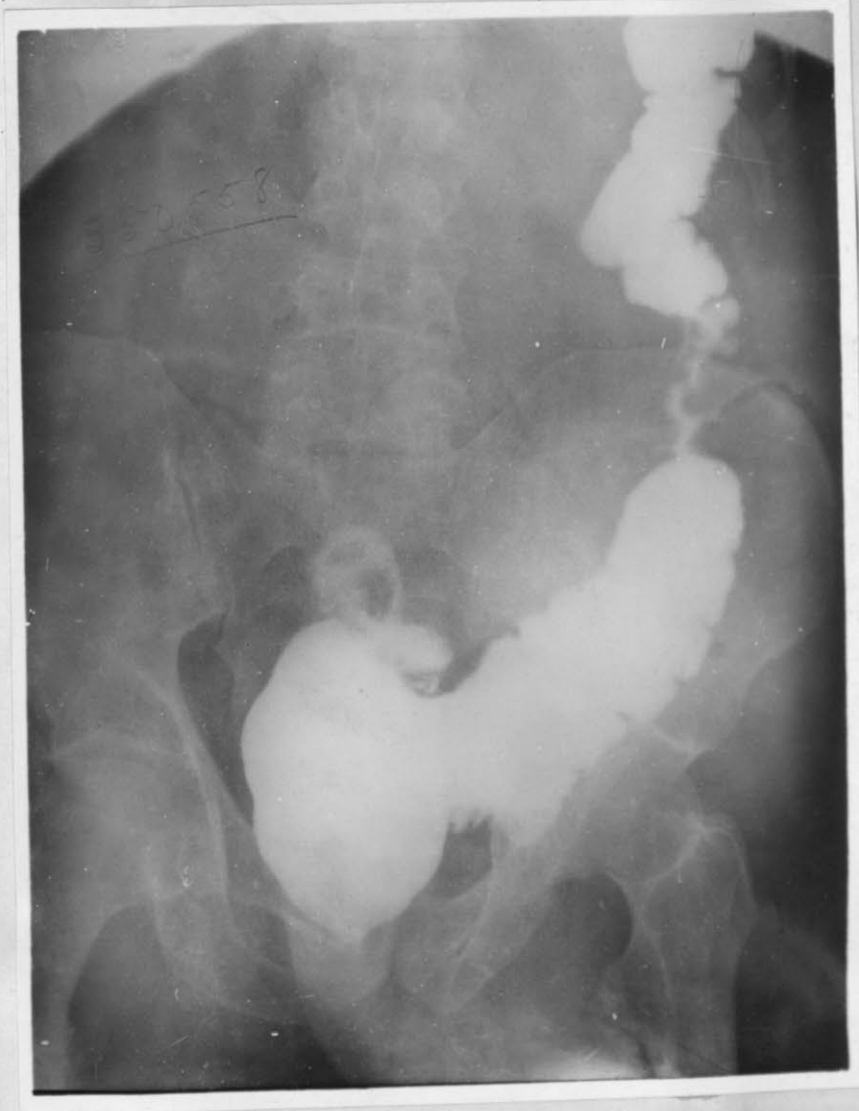

Plate XLI. Group II. Case 350558.

Filling defect in Carcinoma of the
Descending Colon.

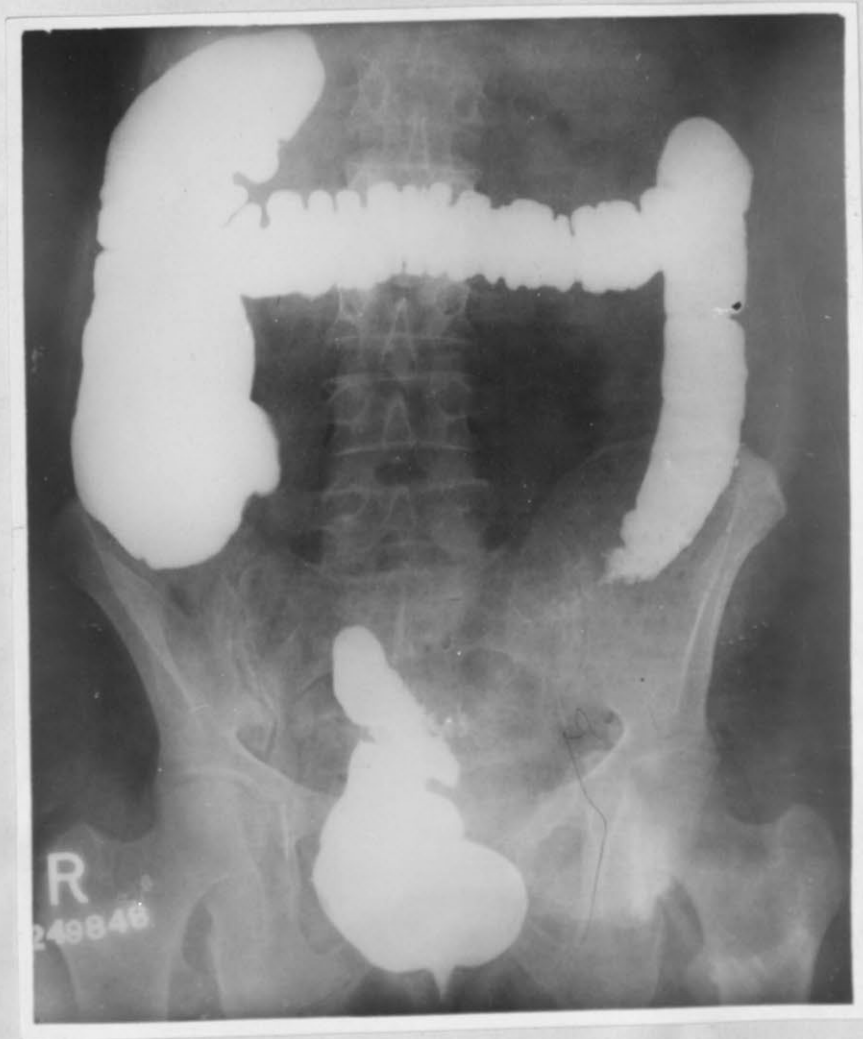

Plate XLII. Group II. Case 249848.

Filling defect in Carcinoma of Sig-
moid Flexure.

Group III. A- Cases of colloid carcinoma of the large intestine with no metastatic involvement of the regional lymph glands.

There were eight cases or eight per cent in this group. Five were females and three males. The average age was 40.5 years, and the average duration of symptoms was 5.6 months. The average number of glands per specimen was 13.2. The sex, age, duration of symptoms, date of operation, and number of glands found is shown in Table IV (page 73).

It has been stated by Hauser and others that colloid carcinoma does not metastasize but it is usually confined to its original location. A study of this group would tend to bear out this conclusion. Of six cases in the series of one hundred, which show no visible glands, two come in this group of eight, and, clinically most of the cases of this group show very mild malignancy. As will be seen later this is a marked contrast to the conditions which exist in the next group.

Group III. B- Cases of colloid carcinoma of the large intestine with metastasis involvement of the regional lymph glands.

There were eight cases or eight per cent in this group. The average age was 51.5 years, and the average duration of symptoms was 16.1 months. The average number of glands per specimen was 12.5. The average number of glands involved was 4.5 per specimen. The sex, age, duration of symptoms, date of recurrence, and the number of glands found, and number of glands involved in each specimen are shown in Table V (page 74).

Group III. A.

Cases of colloid carcinoma of the large intestine with no metastatic involvement of the lymph glands.

Case No.	Sex	Age	Duration of symp- toms in months.	Date of Opera- tion.	Recurrence	Total no.of glands.	No.glands not in- volved.	Glands invol- ved.
100279	M	29	3	2-14-14	-----	25	25	0
223299	F	57	11	3-1-18	-----	16	16	0
245378	F	56	5	9-25-18	-----	11	11	0
263828	F	50	1	4-14-19	-----	8	8	0
209714	F	50	4	10-6-17	-----	15	15	0
243782	F	38	11	1--3--19	-----	31	31	0
339496	M	64	6	11-5--20	-----	0	0	0
321874	M	21	4	6-2--20	-----	0	0	0

Average 40.5 5.6.

Total 106
Average 13.2

Group III. B.

Cases of colloid carcinoma of the large intestine with metastatic involvement of lymph glands.

Case No.	Sex	Age	Duration of symptoms in months.	Date of Operation.	Recurrence	Total no. of glands.	No. glands not involved.	Glands involved.
209414	M	54	12	10-5--17	?	15	2	13
68010	M	56	12	8-1--12	$1\frac{1}{2}$ yrs. later	13	10	3
232689	M	49	24	5--31-18	4-4-19	11	10	1
143179	M	62	6	10--16-15	3-1-16	14	4	10
208521	M	57	9	10--2--15	-----	12	9	3
315878	F	31	30	5-25--20	1--4--21	15	14	1
187084	F	51	24	10--3--18	2-25--19	18	11	7
329174	F	52	18	8--2--20	6--2--19	7	6	1

51.5 16.1

These cases of group III have all appeared before in Groups I and II. This last group studied, in many ways, is the most interesting group of the series. As stated above there were fourteen hundred and six glands found for the entire series of one hundred specimens. Out of this fourteen hundred and six glands found, there were but ninety-five in all that showed metastatic involvement. Of these ninety-five glands which showed metastatic involvement, thirty-nine or forty-one percent fall in this group. In other words, forty-one percent of all the metastatic glands found in the series, are found in eight percent of the entire number of cases.

In going over the clinical histories, quite definite evidence of recurrence within one and one-half years, was established in nineteen cases of the series of one-hundred. Of these nineteen recurrences, five fall in this group or 26.3 percent of the total number of recurrences during one and one-half years time, fall in this group which is made up of eight percent of the total number of cases.

Case 187084., which belongs to this group is especially interesting. March 8, 1917, patient had a resection of stomach for carcinoma of pylorus. October 13, 1918, she had a resection of the transverse colon for carcinoma. February 25th, 1919, she had a recurrence in abdominal wall, which was resected as clean as possible. June 2, 1919, she died of what was apparently an extensive carcinomatosis.

Broders expressed an opinion that once colloid carcinoma began to metastasize, it was difficult to control. A study of these last two groups would tend to support that opinion. It may be seen from tables IV and V that the duration of symptoms is comparatively short in Group III A, while in Group III B, it is very long in most cases. Plate XLIII (page 78) shows extensive colloid carcinoma in a lymph gland.

As stated above, Clogg believes that carcinoma of the large intestine is frequently a local disease. MacCarty and Broders have called attention to the fact that when we have cell differentiation in carcinoma metastasis, the carcinoma tends to limit itself. Plate XLIV (page 79) shows extensive metastasis in a lymph gland with advanced cell differentiation. The tendency to gland formation is evidence of cell differentiation. A marked contrast to this is shown in Plate XLV (page 80). Here we find very little cell differentiation but a marked destruction of tissue. Under the high power the large one-eyed cells, undifferentiated carcinomatous cells are seen with an occasional mitotic figure. Case 143179, represented in this last plate proved to be a highly malignant growth clinically. The patient was operated on October 10th, 1915 for carcinoma of the transverse colon after showing symptoms for only six months. At operation the stomach and ileum were adherent. He died March, 1916, evidently from metastasis, although no autopsy was performed. Out of fourteen glands found locally, ten showed metastatic involvement, the highest proportion of involved glands shown in any of this series.

As suggested above metastasis may occur in the liver with no local metastasis. Case 203854, Plate XLVI (page 81) shows carcinoma in the liver while not a gland visible to the naked eye could be found locally. One other case showed metastasis in the liver with no local metastasis, but in this case there were a marked number of large inflammatory glands found.

Many glands found in this series, proved on microscopic examination to be nearly normal lymph glands. Plate XLVII (page 82) is nearly a normal lymph gland. Only a small amount of cellular infiltration can be seen. Most of the germ centers are almost entirely intact. Plate XLVIII (page 83) shows a marked contrast to this. Here we have a highly inflammatory process, with marked cellular infiltration, large dilated sinuses full of lymph, and the germ centers partly destroyed.

Plate XLIX (page 84) shows a beginning metastatic involvement of a large lymph gland. It may be noticed that the involvement takes place first near the periphery of the gland through the lymph sinuses. This fact has been called to our attention by Billroth, MacCarty and Blackford, Zender, and McVay.

Frequently it is easy to mistake the lower cut off ends of the normal glands of the intestine for highly differentiated carcinoma metastasis. Plate L (page 85) shows the normal cut off ends of the glands of the intestine in the lower part of the picture, while a carcinomatous growth is shown in the upper part of the picture. Notice the regularly arranged columnar epithelial cells of the normal glands in contrast to the crowded irregularly arranged cells of the carcinoma.

Our attention has been called, many times, to the fact that of all the alimentary tract the large intestine gives the lowest degree of malignancy. A study of this series seems to bear out this conclusion. MacCarty and Blackford found fifty-two percent of two-hundred cases showing metastatic glandular involvement in carcinoma of the stomach. McVay in his study of glandular involvement in carcinoma of the rectum, found that forty-seven percent of cases showed glandular involvement. In this series sixty-three percent showed no metastasis. The average number of involved glands in this series was also much smaller than either the series of MacCarty and Blackford in their work on the stomach or that of McVay in his work on the rectum.

In the one hundred cases of this series, the sigmoid flexure was involved forty-two times, the descending colon twenty-one times, splenic flexure seven times, the transverse colon sixteen times, the hepatic flexure nine times, and the ascending colon five times.

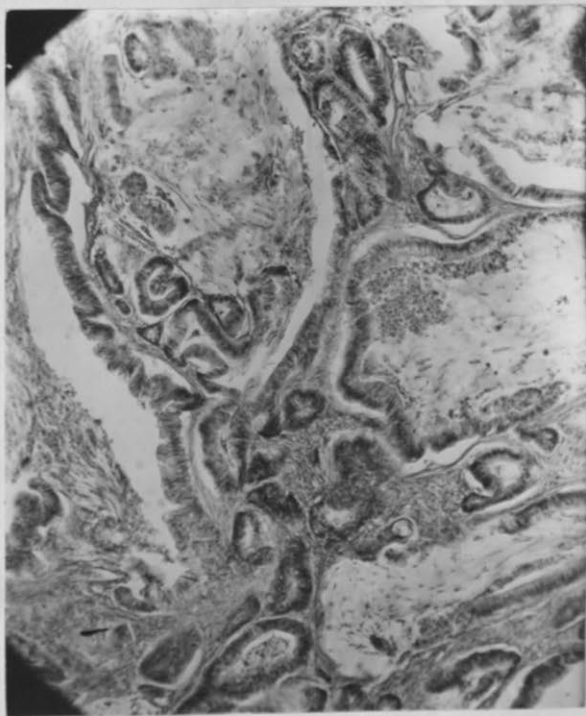


Plate XLIII. Case 232689.

Showing colloid carcinoma
in a lymph gland.

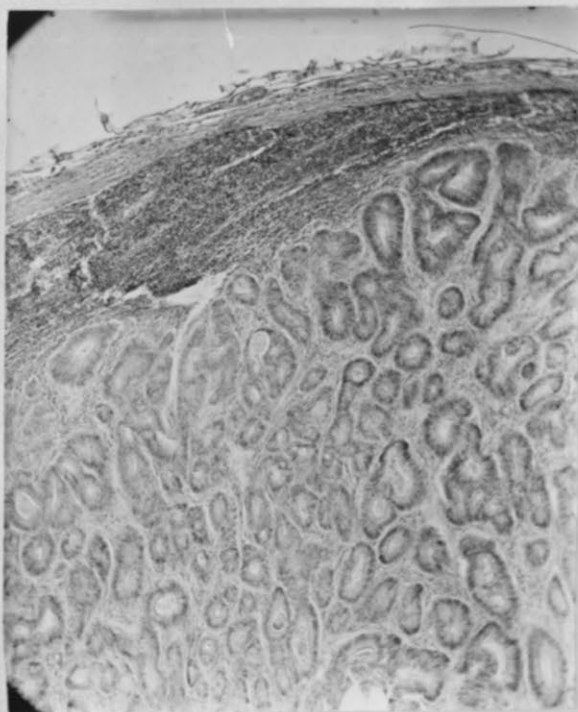


Plate XLIV. Case 248261.

Showing extensive carcinomatous involvement of a lymph gland. Here we see quite a marked tendency toward cell differentiation.

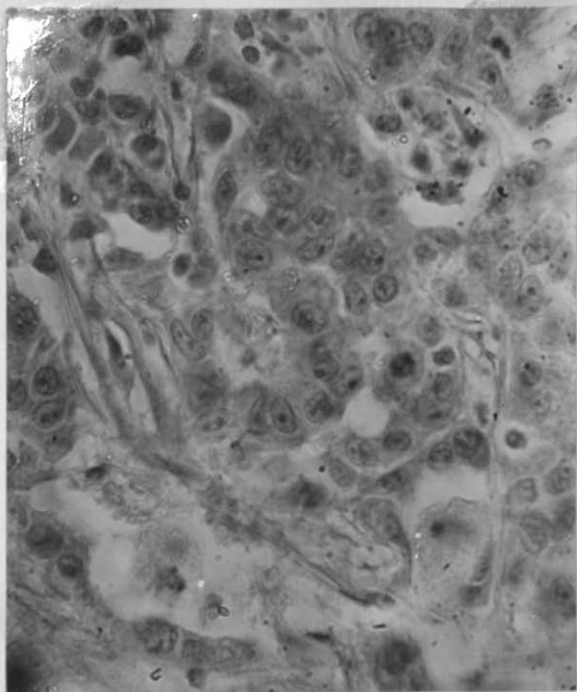
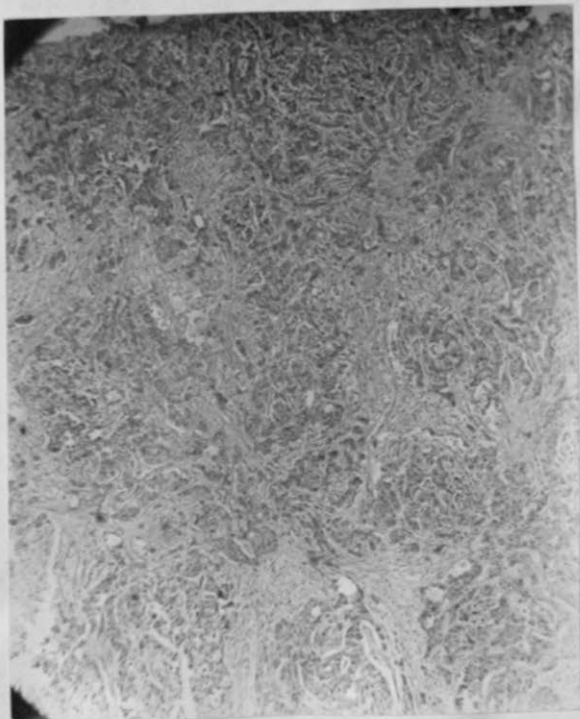


Plate XLV. Case 143179.
Lower picture shows metastasis
in a lymph gland with very little
or no tendency toward cell differ-
entiation. The picture above
shows the large "one-eyed" car-
cinoma cells, some mitotic figures.



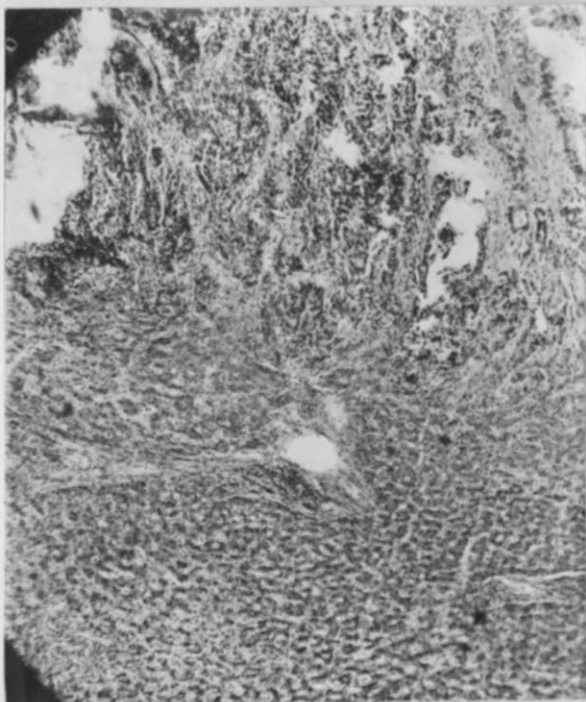


Plate XLVI. Case 203854. Showing metastasis in the liver. In this case there was no local metastasis.

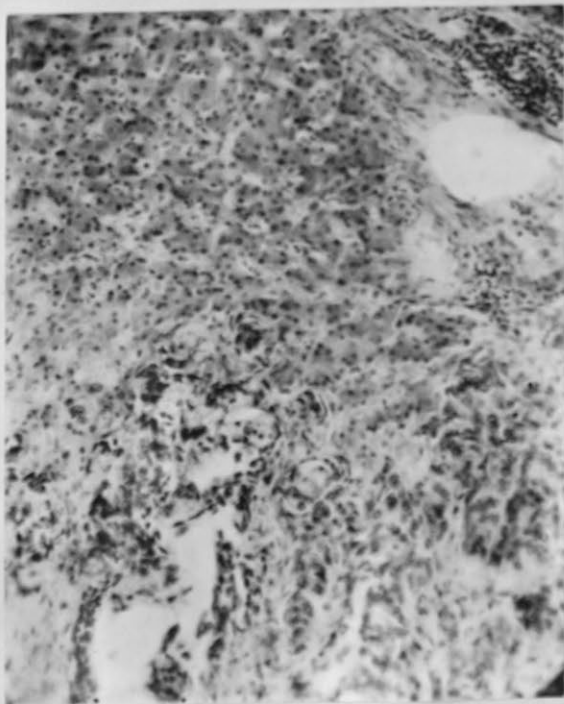

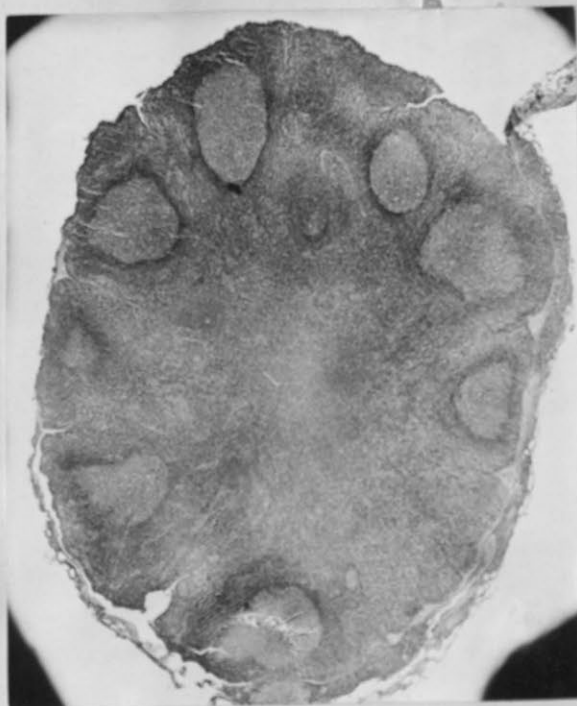


Plate XLVII. Case 263828.
Showing a lymph gland with
very little change from its
normal condition. Compare with
Plate XLVIII (page 83).

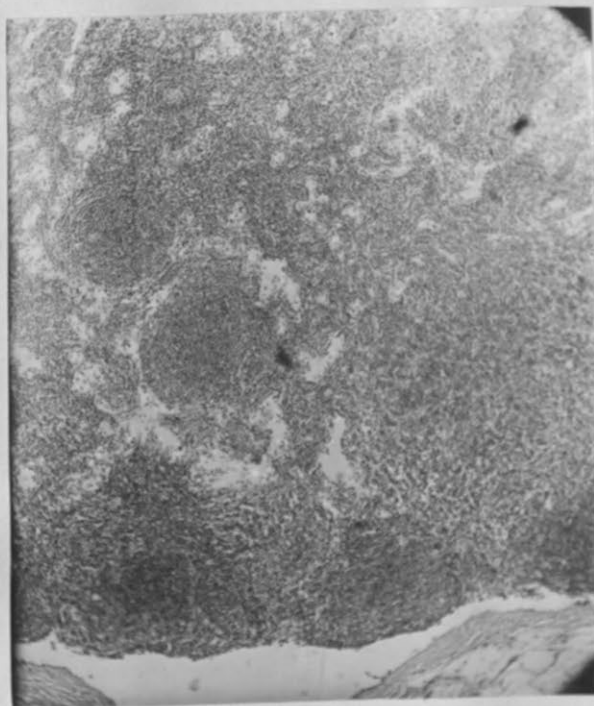


Plate XLVIII. Case 289835.
Showing section of large inflammatory lymph gland. The lymph spaces are large and filled with lymph. There is also a marked cellular infiltration and a marked destruction of the germ centers. Compare with Plate XLVII (page 82).

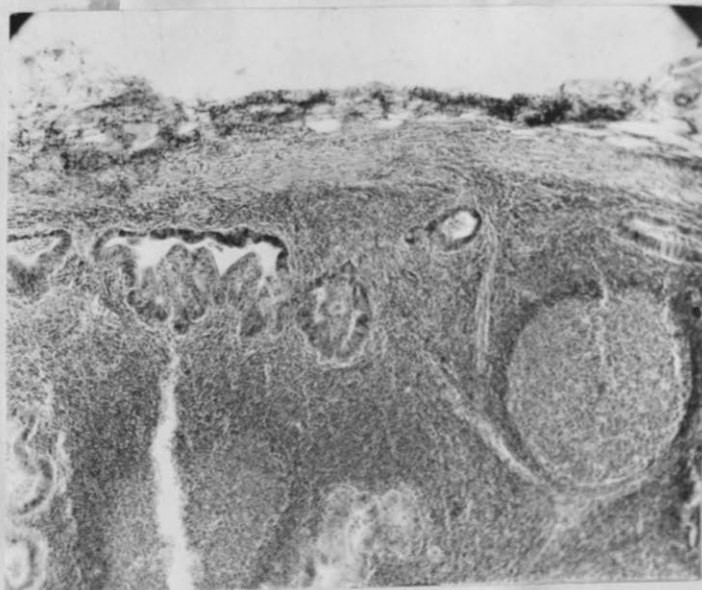

Plate XLIX. Case 167084.
Showing early metastasis in
a lymph gland.

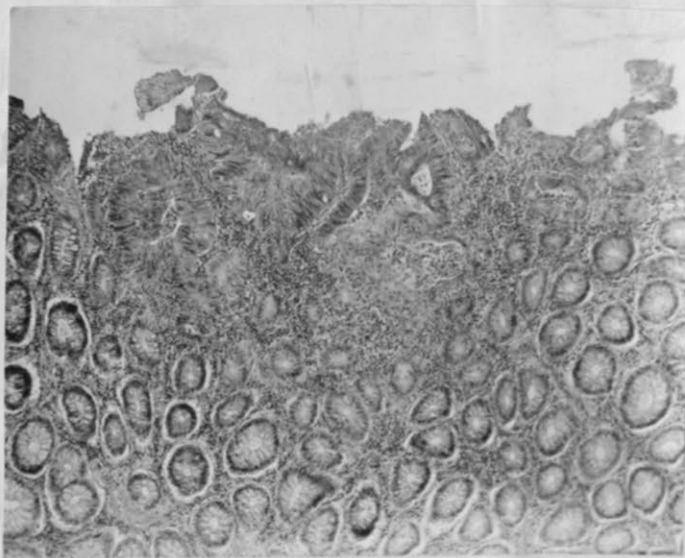


Plate L. Case 157681.
Showing the cut off ends of
normal glands in lower part
of picture and carcinoma in
the upper and central parts.

On page fifty-seven, drawings made at the time the dissection of these specimens was done, were referred to. Rather these are copies of drawings made at that time and are shown in Plates LXI to LXIX inclusive (pages 88--96). These were taken as representative specimens of the series and an attempt was made especially to bring out the fact that the size or number of glands was no criterion to metastatic involvement. This fact was suggested by Kocker, Lynch, MacCarty and Blackford, and McVay. These drawings show the intestine opened on the side opposite the growth, or in cases of annular carcinoma, the opening was made through the carcinoma. The gland bearing tissue posterior to the growth was frequently cut in the middle and turned out to the sides, so that no glands are represented posterior to the growth itself. The glands are numbered in position as they were removed from the specimen, and in each case the actual size of the gland is represented as nearly as it was possible to do so. No. I. represents a section from the growth in each case. The glands posterior to the intestine which showed no involvement are marked as dotted circles, and as circles with cross lines when they did show metastatic involvement. The glands to the sides of the intestine are shown as clear circles when they were not involved and in solid black when they were involved. In these drawings it may be seen that many very large glands show no metastatic involvement, while some very small glands which might easily escape palpation, show marked involvement. Compare plates LXI, LXII and LXVIII (pages 88,89, and 95) with LXIV and LXIX (pages 91 and 96). In the former we have a very large number of large inflammatory glands, which show no metastatic involvement, but to the naked eye or the sense of touch they seem to be practically indistinguishable from the involved glands. Plate LXIV (page 91) shows a large number of glands involved, and practically all of these glands are too small to palpate in the

abdomen under ordinary conditions. There were no glands found at the time of operation, yet the growth was extensive, piercing the intestinal wall and involving the bladder and ileum. This case fell in Group III B, and proved to be one of the most malignant. Plate LXIX (page 96) shows many large inflammatory glands and a very few carcinomatous glands. As may be seen from the drawing, the size or position of the gland has very little to do with determining whether it shows metastasis or not. The five plates above mentioned were selected with no thought of the case number, or the clinical history of the patient, but it so happened that on investigation of the histories, the two cases showing metastasis lived but a short time, while the other three when last heard from were feeling well and had gained from fifteen to twenty-eight pounds. Plates LXIII, LXV and LXVI, (pages 90, 92, and 93) show some unusually large glands with metastatic involvement but they seemed to be a marked exception in this series.

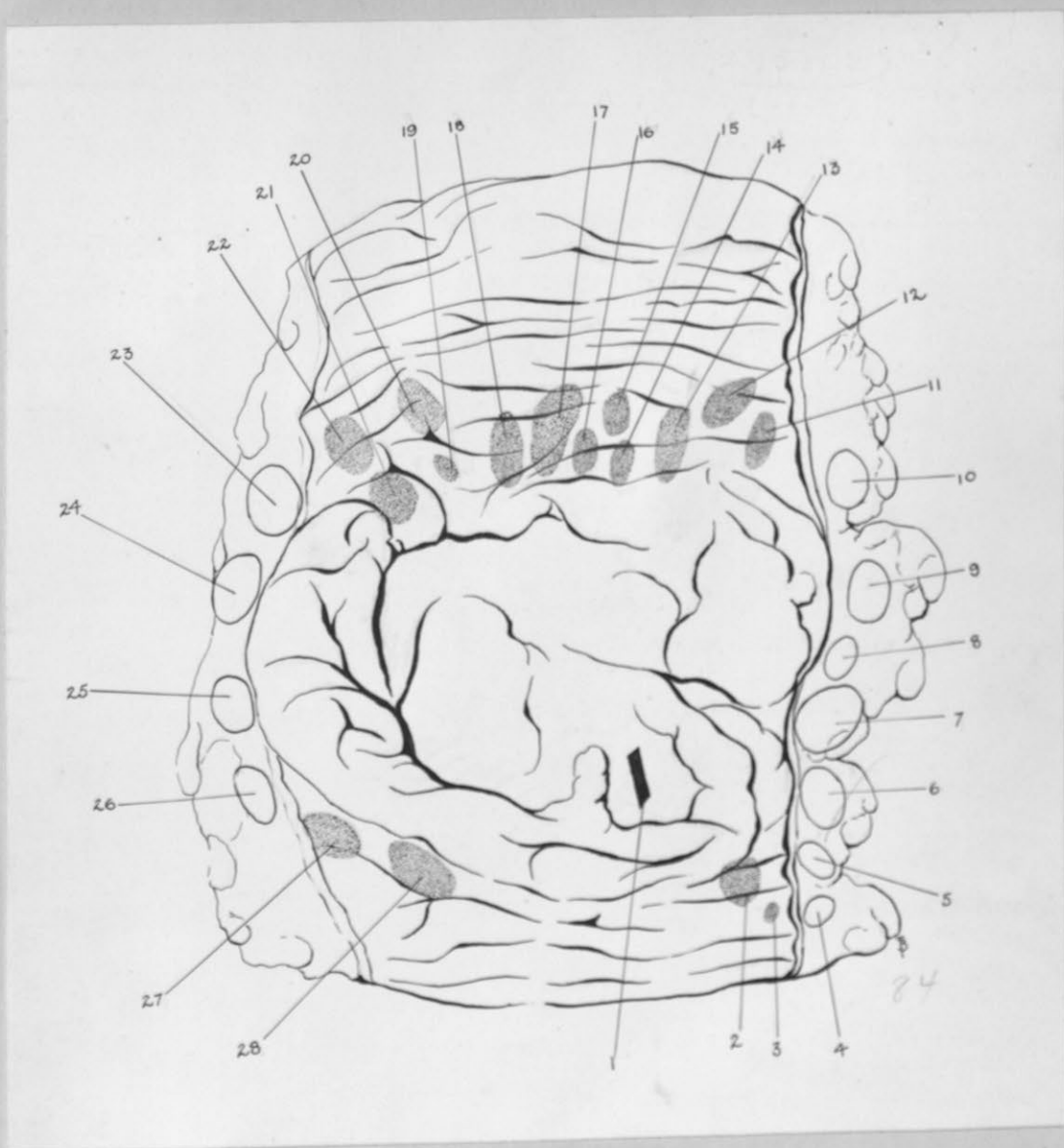


Plate LXI. Case 245802. Drawing showing size and position of glands and their relation to growth. Dotted circles represent glands which show no involvement behind the intestine; clear circles those not behind the intestine, showing no involvement. Circles with cross lines represent glands which show involvement behind the intestine. Solid black circles represent glands showing involvement not behind the intestine.

Mr. J. Hayes
Mar. 23, 1915
No. 3502

PHOTOGRAPHED

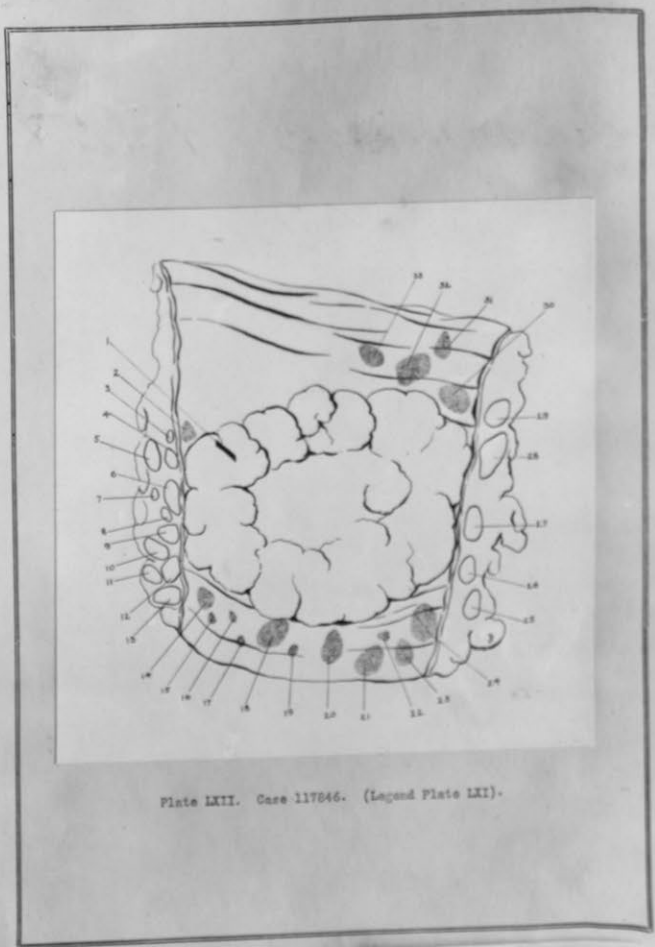


Plate LXII. Case 117846. (Legend Plate LXI).

TOP

Figure No. 3500.
 Author Dr. W. Dages.
 Title Thesis.
 Date Mar. 1921. 7.3.
 Received by EDITORIAL DEPT.
 MAYO CLINIC
 ROCHESTER, MINNESOTA

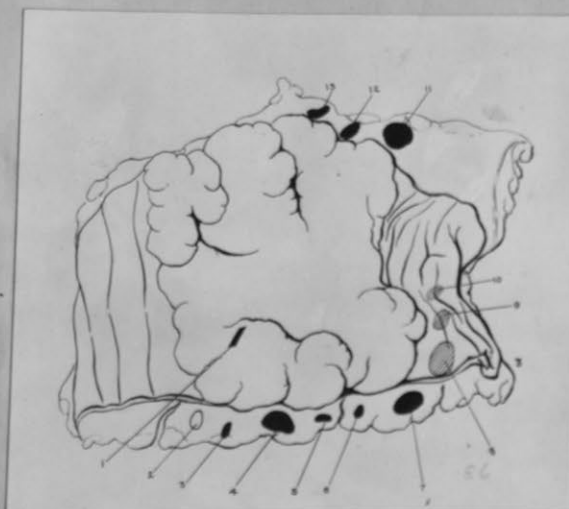


Plate LXIII. Case 143179. (Legend Plate LII).

7-86

TOP
 Figure No. 3494.
 Author Dr. J. Hayes.
 Title Thesis.
 Date Mar. 1921. T.B.
 Return to EDITORIAL DEPT.
 MAYO CLINIC
 ROCHESTER, MINNESOTA

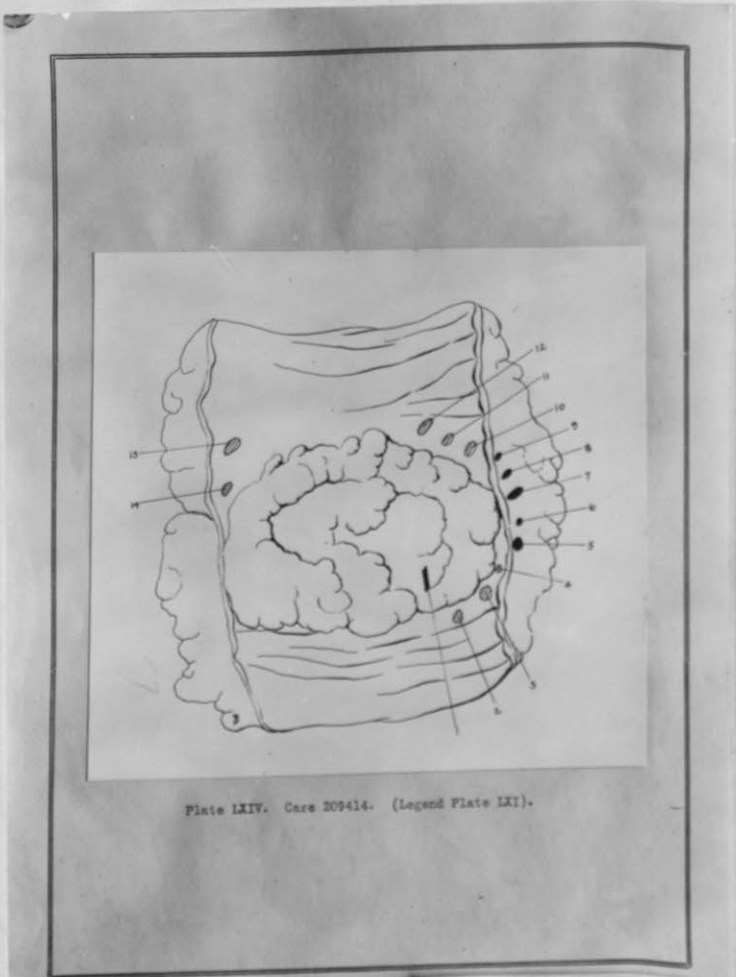


Plate LXIV. Case 209414. (Legend Plate LXI).

1-27

TOP

Figure No. 3495.

Author Dr. J. Hayes.

Title Thesis.

Date Mar. 1921. T.B.

Revised by EDITORIAL DEPT.
MAYO CLINIC
ROCHESTER, MINNESOTA

see w

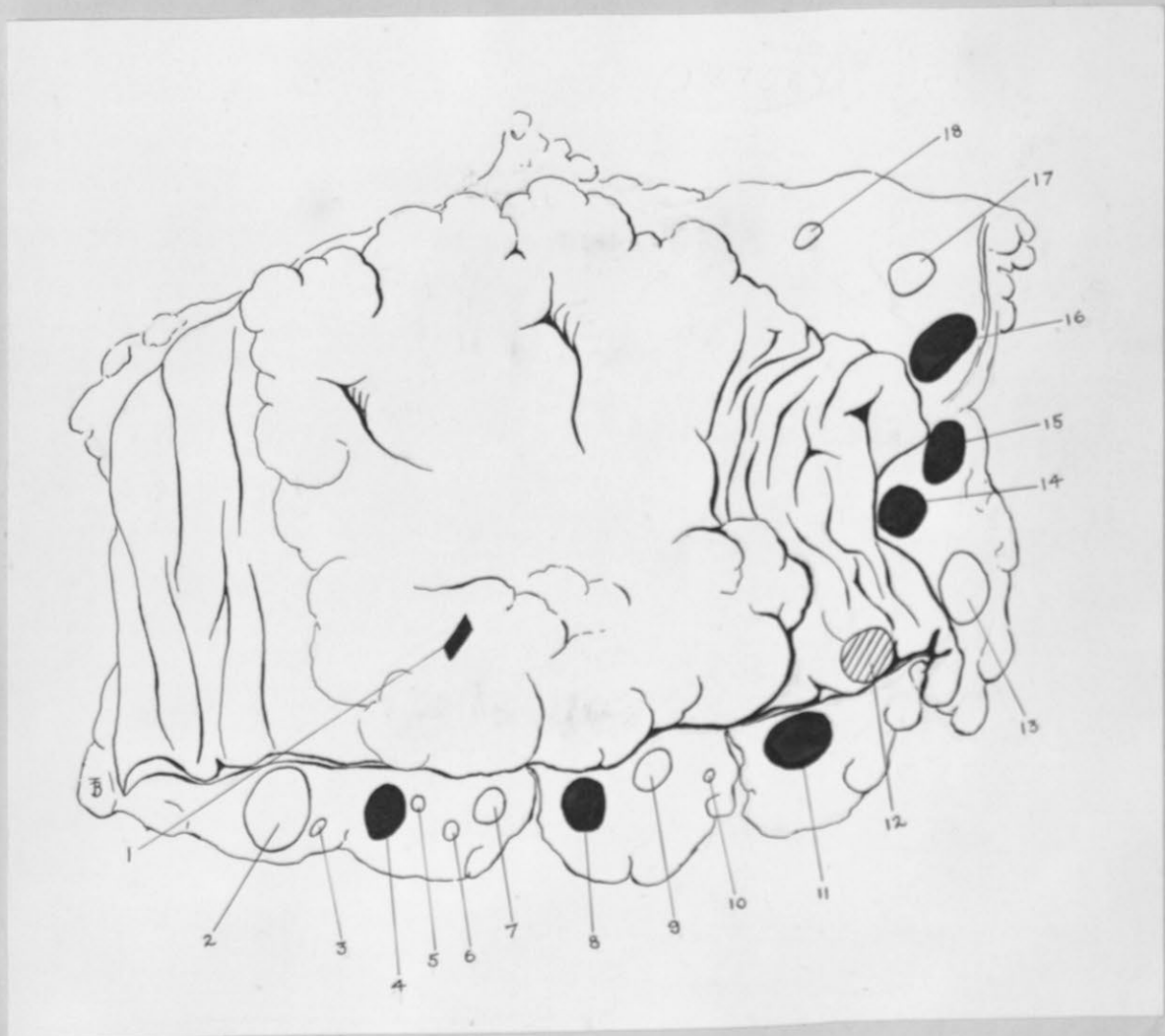


Plate LXV. Case 187084. (Legend Plate LXI).

Mr J. Hayes

Mar 23, 1921

No. 3497

PHOTOGRAPHED

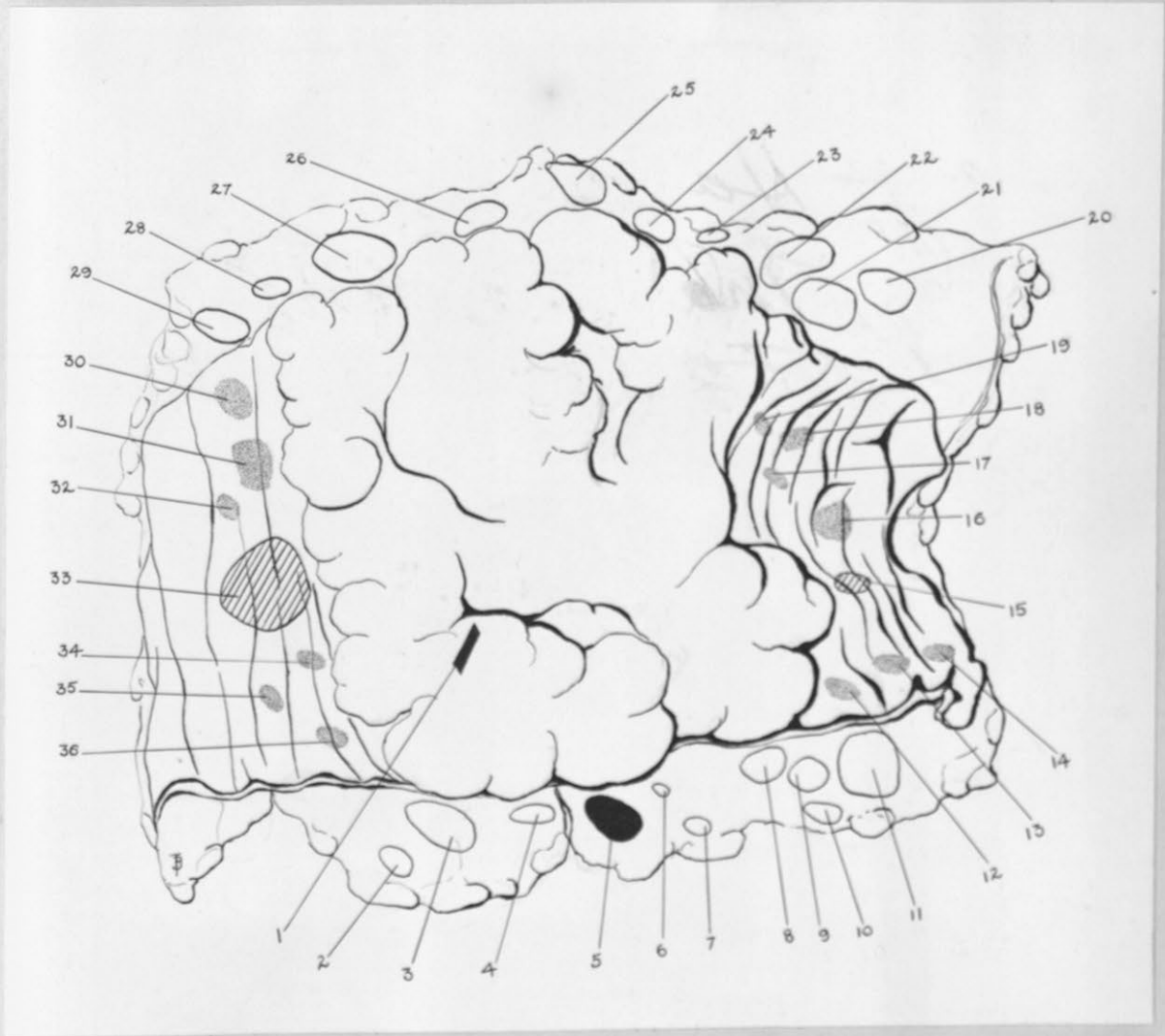


Plate LXVI. Case 187449. (Legend Plate LXI).

Dr J. Hayes.

Mar 23, 1921.

No. 3498.

PHOTOGRAPHED

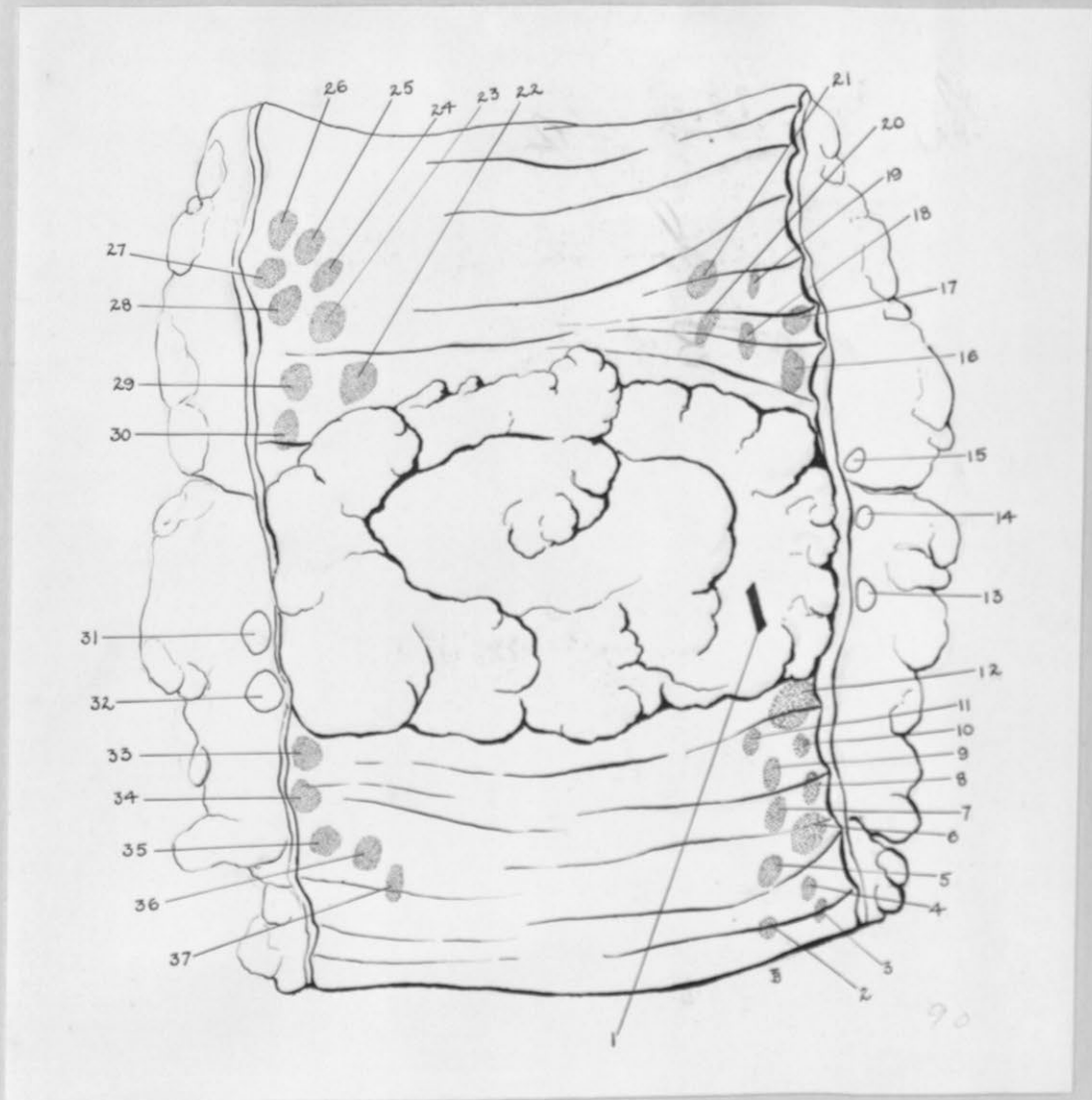


Plate LXVII. Case 197535. (Legend Plate LXI).

W. J. Hayes
Mar 23 1921
No. #3501

PHOTOGRAPHED

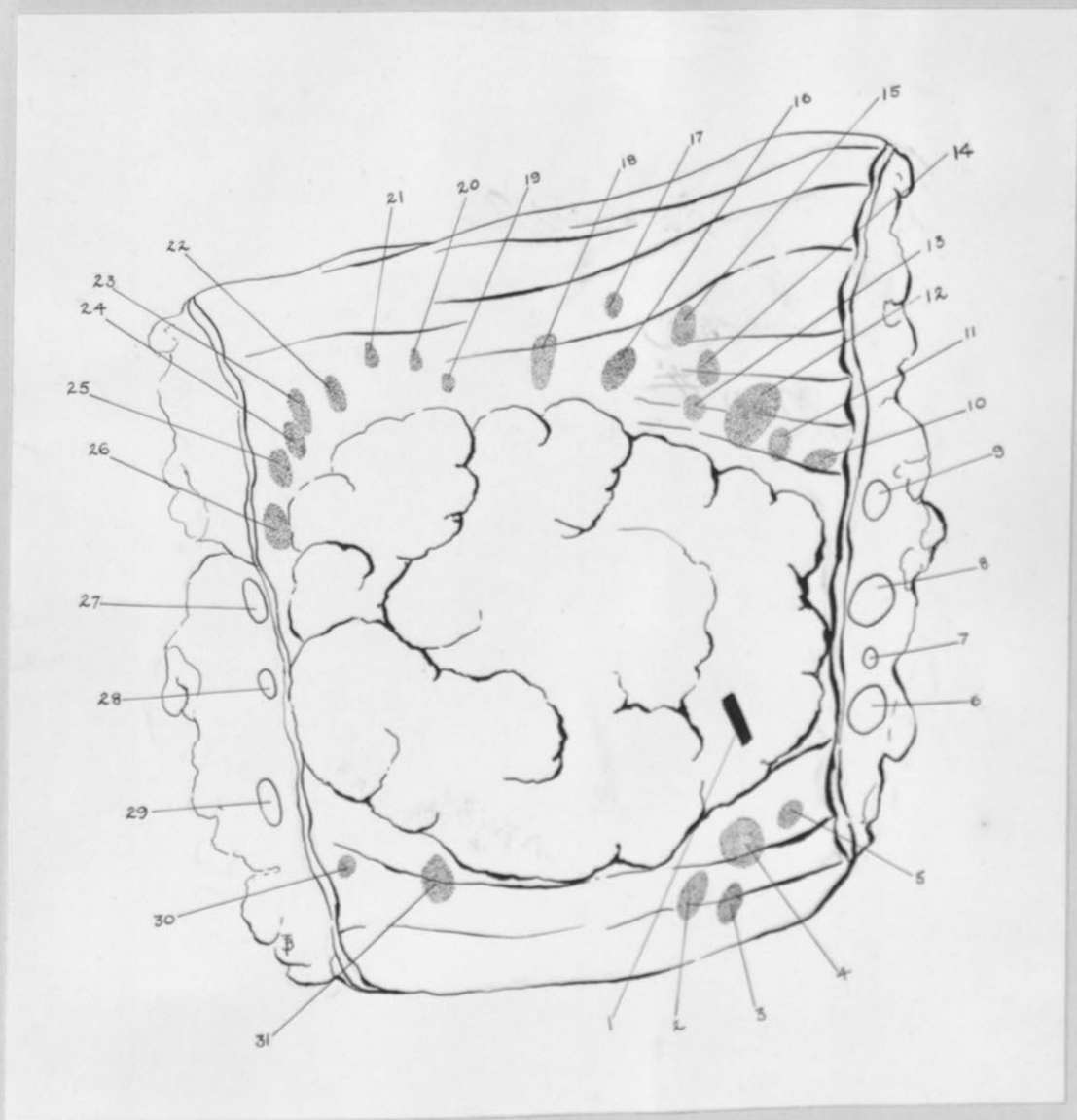


Plate LXVIII. Case 243782. (Legend Plate LXI).

Mr. J. Hayes
Mar 23-1921
no # 3496

PHOTOGRAPHED

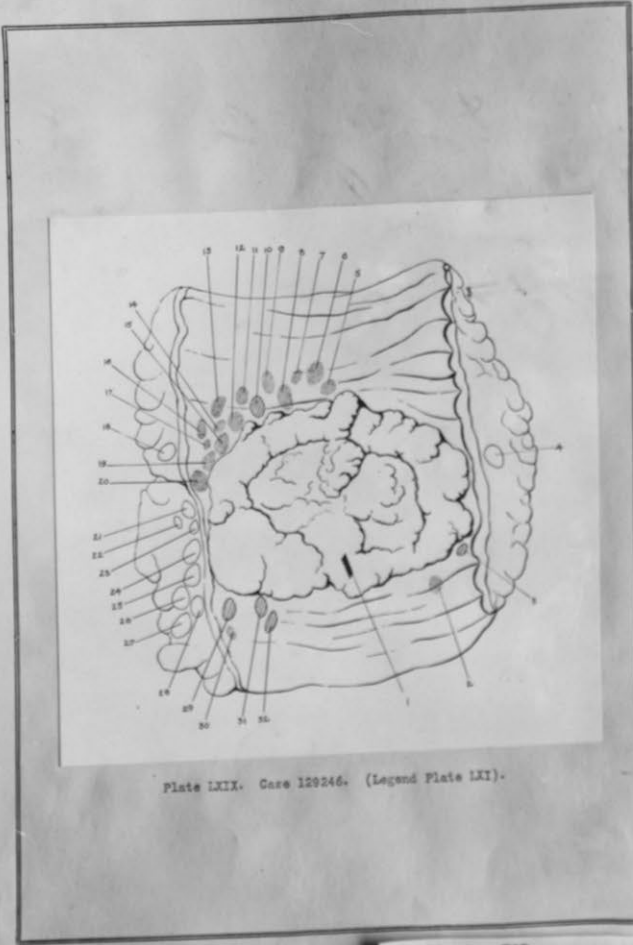


Plate LXIX. Case 129246. (Legend Plate LXI).

72

TOP
 Figure No. 3499.
 Author Dr. J. Hayes.
 Title Thesis.
 Date Mar. 1921. 7.3.
 Return to EDITORIAL DEPT.
 MAYO CLINIC
 ROCHESTER, MINNESOTA

CHAPTER IV.

Summary and Conclusions.

As stated above, one hundred specimens were studied in this series. These specimens were carcinomatous growths removed from different parts of the large intestine. Only that part of the large intestine beginning with the ascending colon and ending with the terminal portion of the sigmoid flexure were studied. Fourteen hundred and six local glands were obtained for microscopic study. Of this number only ninety-five glands showed metastatic involvement. Of these ninety-five carcinomatous glands, thirty-nine, or forty-one percent of the entire number falls in Group III B, which is made up of only eight cases of colloid carcinoma. Sixty-three percent of the cases showed no local metastasis, while thirty-seven percent showed one or more glands involved.

If one were to draw conclusions from this study, the facts obtained would suggest the following conclusions:

1. Carcinoma of the large intestine metastasizes less frequently than that of any other part of the gastro-intestinal tract.
2. Carcinoma of the large intestine occurs most frequently in the sixth decade, but it is quite common from the third decade on.
3. It occurs about equally in both sexes.
4. Of the parts of the large intestine here studied it occurs most frequently in the sigmoid flexure and in the other parts in the following order: descending colon, transverse colon, hepatic flexure, splenic flexure, and ascending colon, the last being the least involved.

5. Annular carcinoma is present in nearly twenty-five percent.

6. Annular constrictions , due perhaps to degeneration and resulting scar tissue, are present frequently, giving the appearance of annular carcinoma.

7. No definite conclusion could be arrived at as to the relative frequency of origin of the growth on the different walls of the intestine because of the marked inflammatory process which complicated many of the growths.

8. A combined study of the clinical histories and appearance of the growths suggest the following conditions as the usual cause for the patient seeking medical aid:

a. Protuberant growths from one wall of the intestine into the lumen, producing obstruction.

b. The formation of annular carcinoma, as described by McArthur, producing constriction and consequent obstruction.

c. Ulceration of the growths in the lumen of the intestine, causing tenesmus and local pain and giving blood and mucus in the stool.

d. Extension of the growth through the wall of the intestine, and into other organs, complicated by secondary infection, resulting in pain and partial obstruction.

e. The weight of the tumor mass, causing distortion of the parts with consequent pain and interference with the normal peristalsis of the bowel.

f. Degeneration and formation of scar tissue producing constriction and consequent obstruction.

9. Carcinomata with no local metastasis usually give protuberant growths into the lumen rather than penetrating the walls of the intestine.

10. Carcinomata with local metastasis usually extend into the wall of the intestine rather than into the lumen.

11. Adenocarcinoma is present in every carcinoma which originates in the large intestine.

12. Colloid carcinoma occurs in about sixteen percent of the cases.

13. Colloid carcinoma does metastasize and is frequently present in the most highly malignant cases.

14. Colloid carcinoma seems to appear in two distinct classes, those with short duration of symptoms or the mildly malignant type, and those with long duration of symptoms, or the very highly malignant type.

15. Colloid carcinoma is very difficult to control after it begins to metastasize.

16. The highest percentage of recurrences is found among the second type of colloid carcinoma.

17. A very high percentage of local metastatic glands are present in this second type of colloid carcinoma.

18. Carcinoma of the large intestine frequently shows marked cell differentiation, and tends to limit itself.

19. Cases showing little or no cell differentiation in the local metastatic glands are frequently shown clinically to be more malignant than those that do show cell differentiation.

20. Metastasis may occur in the liver with no sign of local metastasis.

21. Lymph glands may be almost normal in consistency yet be palpable and plainly visible to the naked eye.

22. Lymph glands may be only inflammatory, yet have such a marked cellular infiltration and lymphedema, as to simulate large carcinomatous glands, both in size and consistency.

23. Carcinoma usually enters the lymph gland through the lymph sinus at the periphery of the gland, and in early involvement cannot be detected except by systematic microscopic examination.

24. The lower cut off ends of the glands in the intestinal wall may be mistaken for highly differentiated carcinoma.

25. Very small glands, too small to palpate under ordinary conditions in the abdomen may be carcinomatous.

26. Local metastatic glands are usually at the point of greatest extension of the growth, but there are frequent exceptions to this.

27. With many of the more mildly malignant cases, which show no metastasis, the local glands are larger and more numerous than in the more highly malignant cases.

28. In a few cases there are no local glands large enough to be visible to the naked eye.

29. Very few growths show more than two or three metastatic glands, while there may be a great number of large inflammatory glands in this same specimen.

30. Cases showing a large number of involved glands locally, usually show a high degree of malignancy, clinically.

31. The size of the growth is no criterion on which to determine the presence or absence of metastasis.

32. Only by a systematic microscopic examination can we rule out local metastasis in carcinoma of the large intestine.

Bibliography

1. Aaron, C.D. Report of a case of carcinoma of the splenic flexure of the colon, treated with the neoformans vaccine. *Med. Rec.*, 1920, lxxviii, 572.
2. Allin, E.W. Carcinoma of the colon. *Canad. Med. Assn. Jour.*, 1920, No.11. 1021-26.
3. Armstrong, George E. Cancer of the large bowel. *Canad. Jour. Med. and Surg.*, 1918, xliii, no. 4., 94-102.
4. Balfour, D.C. The utility of the rubber tube in intestinal surgery. *Surg. Gyn. and Obst.*, Aug. 1920, 184.
5. Barker, A.E.J. A clinical lecture on the removal of tumors of the large intestine. *Lancet, Lond.*, 1909, i, 1231-1235.
6. Bartels, P. Das lymphgefasssystem. Jena, Fischer, 1919, 223-224.
7. Bastinnelli, R. and Korte. Cancer of the large intestine (Abstr.) *Brit. M.J., Lond.*, 1913, 11, 388.
8. Bazy Cancer du cōlon transverse; extirpation; guérison, en quatre séances opératoires. *Bull. et mem. Soc. de chir. de Par.*, 1906, n.s., xxxii, 1029-1033.
9. Bevan, A.D. Carcinoma of the splenic flexure. *Surg. Clin. Chicago*, 1920, iv, no. 2, 311--319 April.
Bevan Surgery of cancer of large intestine. *Jour. Amer. Med. Assn.*, 1920, lxxv, no. 5, 283-286.
10. Billroth, T. Neue Beobachtungen über die feinere struktur pathologisch veränderten lymphdrüsen *Virchow's Archiv.*, 1861, xxi, 423-443.
11. Bird, F.D. A method of removing carcinoma of the ascending colon. *Lancet, Lond.*, 1906, 440.
12. Brill, N.E. Primary carcinoma of the duodenum, *Amer. Jour. Med. Science*, 1904, cxxvii, 824.
13. Broders, A.C. Personal communication.
14. Bryant, Quoted by Nothnagel.
15. Casper, M. Carcinoma of the colon; report of a case including a brief literary review. *Amer. Jour. Surg.*, 1918, xxxii, 267-275.

16. Chaliier, A. Cancer de l' angle droit du colon guéri depuis sept ans et demi par l'opération en trois temps: 1 degré anus caecal; 2 degrés enterectomie; three degrés fermeture de l'anús caecal. Lyon méd., 1912, cxix, 956.
17. Cheatle, G.L. The spread of cancer in the lower part of the large intestine. Brit. Med. Jour., 1914, i, 303, 2 pl.
18. Cheney, W.F. The diagnosis of cancer of the intestines, Amer. Jour. Med. Sciences, 1910, n.s., cxxxix, 211-221.
19. Clar Quoted by Nothnagel.
20. Clazy Lancet. 1908, ii, 1007.
21. Coffey, R.C. What shall we do with far advanced cancer of the large bowel? Med. Rec., 1908, lxxiii, 253-259.
22. Cullen, T.S. A malignant intestinal growth requiring the removal of an unusual number of abdominal structures. Surg. Gynec. and Obstetrics, 1911, xii, 184.
23. Cushing, H.W. The operative treatment of carcinoma of the large intestine causing dangerous intestinal obstruction. Ann. Surg., Phila., 1906, xlv, 261-274.
24. Custom and Vander Veer, Quoted by Sherill.
25. Cole, F.P. The intramural spread of rectal carcinoma. Brit. Med. Jour., 1913, i, 431-433.
26. DeBovis, Le cancer du gros intestine, rectum excepte. Rev. de Chir., 1900, xxii, 673.
27. Delamere, G. Poirer, P. Cuneo, B. The lymphatics. Trans. by C.H. Leaf, Chicago, Keener, 1904, 3-110-186-191.
28. Delore, Cancer sténosant de l'intestine grêle; double résection intestinal. Lyon Méd., 1909, cxiii, 878.
29. Douglas, John Resection of colon for carcinoma. Ann. Surg., 1917, lxvi, 229, August.
30. Drueck, Chas. J. Cancer of the rectum and colon--its symptoms and differential diagnosis. Interstate Med. Jour., 1918, xxv, no.1, 64--72.
31. Farrant, C. A case of carcinoma of the descending colon in a man aged 27. Brit. M.J. Lond., 1913, i, 1322.
32. Gerard, Quoted by Nothnagel
33. Grant, W.W. Carcinoma of descending colon. Surg. Gynec. and Obst., Chicago, 1906, ii, 289-292(Discussion)332.

34. Handley, W.S. The surgery of the lymphatic system. Brit. Med. Jour., 1910, 922-928.
35. Hartwell, J.A. Carcinoma of the splenic flexure of the colon. Ann. of Surg., 1917, lxvi, 339-361.
36. Hauser, Quoted by Nothnagel.
37. Heimann, G. Quoted by Nothnagel.
38. Hemmeter, John C. Diseases of the intestines. ii. Phila. Blakeston's Son and Co., 1902.
39. Horsley, J.S. Carcinoma of the bowel and of the appendix in the young. Jour. Amer. Med. Assn., 1909, lii, 1471-1473.
40. Jameson, J.H. and Dobson, J.F. Lancet. 1907, i, 1137.
41. Joans, A.F. Neoplasms of the colon. Report of sixteen cases. Jour. Amer. Med. Assn., 1906, xlvii, 825-832. Discussion, 835-838.
42. Judd, E.S. Carcinoma of the small intestines. The Jour. Lancet. April 1, 1919, xxxix, 159-169.
43. Keith, Arthur Intestinal stasis. Brit. Jour. Surg. 1914-1916, ii, 576.
44. Kiebel and Mall; Human Embryology. ii, 397. Phila. Lippincott, 1912.
45. Knowlton, A.B. Tumor of the cecum and ascending colon; removal and recovery. Jour. Amer. Med. Assn., 1906, xlvi, 1611.
46. Lane, W.A. The operative treatment of cancer of the large bowel. Clin. Jour., Lond., 1907-1908, xxxi, 401-408.
47. Leichtenstern Quoted by Nothnagel.
48. Lubarch Quoted by Nothnagel.
49. Lund, F.B. Adenocarcinoma of the sigmoid flexure. Boston M. and S.J. 1906, 341.
50. Lynch, J.M. The early diagnosis of cancer of the rectum. Am. J. Surg. 1915, xxix, 274-276.
51. MacCarty, W.C. and Blackford, J.M. Involvement of regional lymphatic glands in carcinoma of the stomach. Ann. of Surg., 1912, 811-843.
- MacCarty, W.C. Facts versus speculation in the professional conception of cancer. Texas State J.M., 1915, xi, 165-169.

52. McArthur, L.L. Carcinoma of the rectum. Surg. Gynec. and Obst. 1915, xxi, 495-497.
53. Makins, G.H., Wallace, C., Sargent, P. Multiple tumors of the large intestine. Proc. Roy. Soc. Med., Lond., 1911-12, v, surgery sect., 137-149.
54. Mayo, W.J. Relation of the development of the gastro-intestinal tract to abdominal surgery. J. A.M.A. Feb. 7, 1920, lxxiv, 367-372.
- Resection of the first portion of the large intestine and the resulting effect on its function. J. A.M.A. Aug. 8, 1914, lxxiii, 446-449.
- Carcinoma of the gastro-intestinal tract. Jour. Lancet. Jan. 15, 1912-1913.
- Tumors of the caecum. Jour. Minn. M.A. and Northwestern Lancet. Dec. 15, 1909.
- Resection for the relief of obstruction. J. A.M.A. Sept. 14, 1907. xlv, 903-906.
- The relation of cancer to the prolongation of life. Surg. Gynec. and Obst., Jan. 1920, 22-26.
- The radical operation for carcinoma of rectum and recto-sigmoid. Amer. Jour. of Surg. Sept. 1916.
- Grafting and traumatic dissemination of carcinoma in the course of operations for malignant diseases. J. A.M.A. Oct. 28, 1916. lxxvii, 1279-1284.
- Some of the disputed problems associated with surgery of the large intestine. Amer. Jour. Med. Sciences. Feb. 1913, cxlv, 157.
55. Maydl Quoted by Nothnagel.
56. McVay, J.R. The lymph glandular involvement in carcinoma of the rectum. Not yet published.
57. Mikulicz Quoted by Lynch.
58. MacCollum Quoted by Nothnagel.
59. Michaux, P. Cancer du gros intestin. Bull. et mem. Soc. de chir. de Par., 1908, n.s. xxxiv, 209.
60. Minot, C.S. Human Embryology.

61. Moynihan, B.G.A. Mimicry of malignant disease of the large intestine. Brit. M.J., Lond., 1906, ii, 1817, Edinb. M.J., 1907, n.s. xxi, 228-236. 3 pl.
62. Mummery, P.L. The symptoms and diagnosis of cancer of the large intestine. International Clin., Phila., 1908, 18 s, ii, 155-163.
63. Nothnagel, Herman Diseases of the intestines and peritoneum. Edited with additions by Rolleston, Humphry, D. Phila. Saunders, W.B. and Co., 1904.
64. Paul, F.F. Personal experiences on surgery of the large bowel. Brit. M.J., 1912, ii, 172, 181.
65. Peterman (Ueber carcinoma coli) Deutsche med. wehnschr., 1908, xxxix, 531.
66. Piersol, G.A. Textbook human anatomy, 5th edition, Phila., Lippincott, 1916, 1679, 1614.
67. Sherill, J.G. Carcinoma of the intestine. N.Y. Med. Jour. Jan. xci, 331.
68. Stöhr Quoted by Piersol.
69. Symmers, D. Metastases of tumors. Amer. Jour. Med. Sciences, 1917, xliv, 225-240.
70. Treves Cited by Minot.
71. Turner, G.G. A new method of restoring the continuity of the bowel in cases of excision of a growth low down in the sigmoid flexure. Lancet, Lond., 1908, i, 1512.
72. Vance, A.M. Intestinal carcinoma. International Clinics, Phila., 1911, 21, s., iv, 178-182.
73. Wallis, F.C. Three lectures on carcinoma of the rectum. Clin. J. Lond., 1910-11, xxxviii, 209-230-254.
74. Welsh, D.A. On the surgical pathology of the large intestine, with special reference to carcinoma. Edinb. M.J., 1912, n.s., viii, 103-110.
75. Wheeler, H.A. A study of the anus, rectum and sigmoid. Jour. Indiana M.A., 1918, xi, 442-445.
76. Zuppenger Quoted by Nothnagel.
77. Zehnder Uber Krebsentwicklung in Lymphdrüsen. Virchow's Archiv., 1890, cxix, 261-270.