



A Story of Three Blind Mice: Characterization of Retinopathy of Hurler's Disease



Luna Liu

Advisor: Linda McLoon, Department of Ophthalmology

Hurler's Disease is a rare but fatal multisystem disorder.

Hurler's Disease or Mucopolysaccharidosis I (MPS I) is one of eleven lysosomal storage disorders classified as the mucopolysaccharidoses, where the breakdown of long sugar chains or glycosaminoglycans (GAGs) is hindered.

In Hurler's, a variety of mutations result in a deficiency of the enzyme alpha-L-iduronidase leading to the accumulation of GAGs in virtually all cells of the body. Progressive accumulation of GAGs causes physical and mental diseases including bone deformities, mental retardation, and heart problems. Severity and prognosis varies, but without treatment, most children die before the age of 10¹.

Treatment does not stop progression of the disease in the eye.

There is no cure for Hurler's. However, therapies offer an increase in life-expectancy. Treatment to slow the progression of the disease exists in the forms of hematopoietic stem cell transplant (HSCT), enzyme-replacement therapy (ERT), and gene therapy. The success and risk of these treatments are variable. HSCT uses a bone-marrow or umbilical blood transplant, a highly-risky and complicated procedure with a reduced chance of success. ERT offers a less risky treatment; however, with ERT neurological manifestations are not alleviated since injected enzyme cannot penetrate the blood-brain barrier.

Although these therapies are able to stop and even reverse the disease in some tissues, the prognosis for ocular conditions is variable. In clinical trials, treating ocular conditions results are variable and often minimal¹⁻⁴. Treatment therapies appear to offer only a temporary relief of ocular problems; the disease still progresses in the eye.

Study of retinopathy of Hurler's and effectiveness of treatment modalities is essential in preventing vision loss.

Currently, it is unclear why eye problems due to Hurler's Disease become worse even with treatment. One possibility is that the treatment comes too late and thus is unable to reverse the permanent damage.

Besides the timing of treatment, categorization of treatment types effective in protection of the eye is also needed.

Mouse model was studied for visual function, specific abnormalities in the retina, and success of two different modalities of treatment in the prevention of vision loss.

Histological Sections: Eye sections from both treated and untreated Hurler mice, mice heterozygous for the mutation, and controls were stained for histological assessment of the retina generally and retinal ganglion cells specifically, neurons within the eye that transmit visual information to the brain.

Optomotor Testing: Mice (Hurler and heterozygous) treated with a bone-marrow transplant and intranasal therapy were tested for vision loss using an optomotor device, Fig.1 and compared to controls. The ability to track the rotating stripes with a head turn indicates functional vision in the eye.




Figure 1. Optomotor device set-up. Mice were placed on a suspended stage with a rotating optomotor drum, with alternating white and black stripes. The drum was rotated in both a clockwise and counter-clockwise direction. A video camera mounted above the drum allowed for monitoring. Visual ability was tested by counting the number of head-tracking movements.

Hurler mice showed large variations in retinal morphology -from normal in appearance to extremely abnormal.

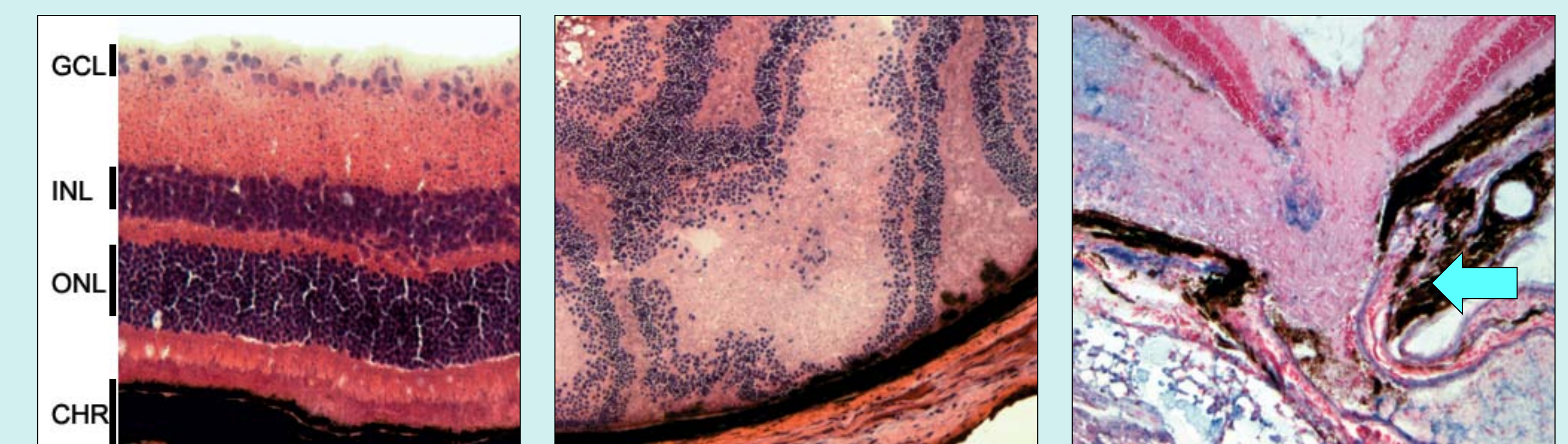

Figure 2. Hurler's Retinal Morphology. a) Wild-type mouse retina. b) Hurler retina showing a disorganization of retinal layers and GAG deposits. c) Hurler retina where optic nerve fails to exit the eye.

Intranasal treatment may have protective effects on vision in the treatment of Hurler's disease.

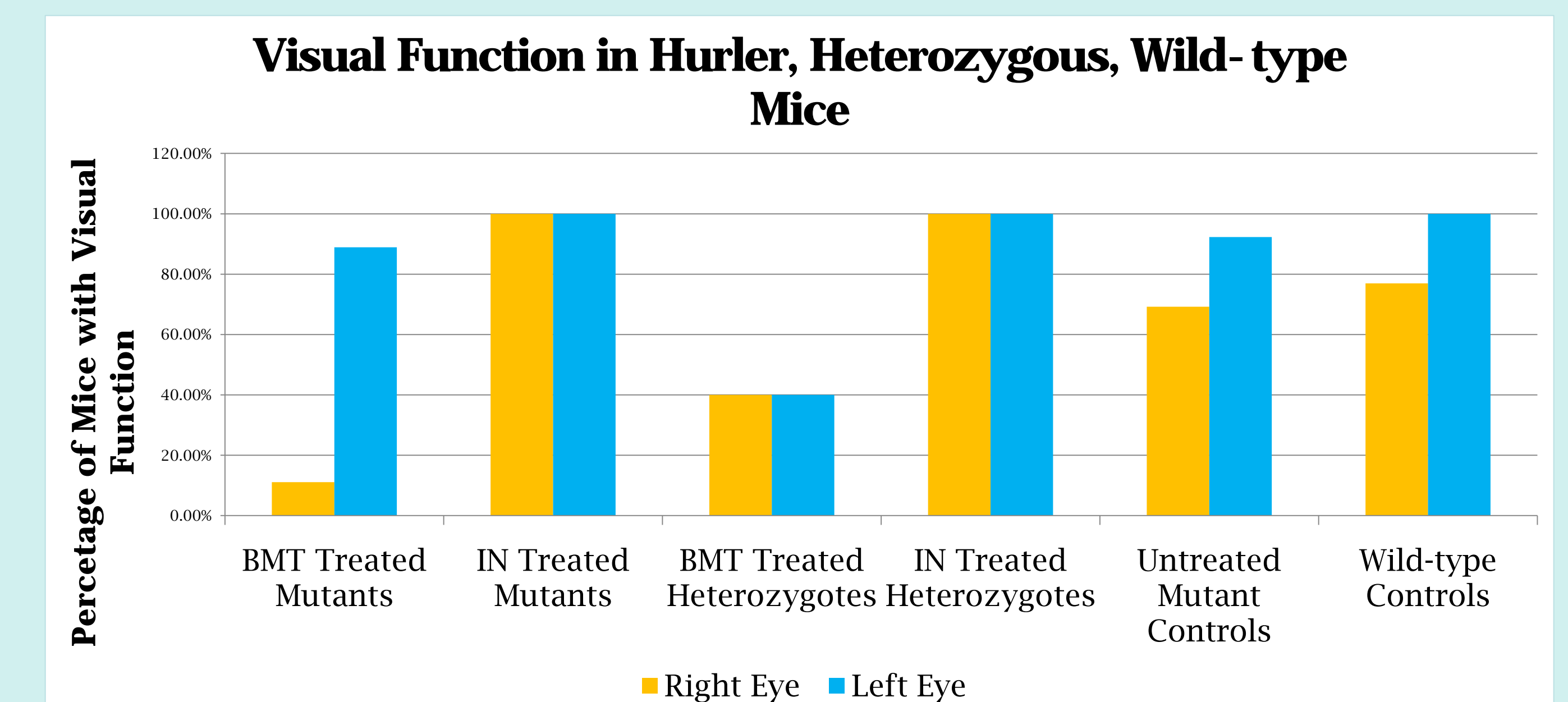


Figure 3. Percentage of visual function in mice. Approximately 25% of Hurler mice were unilaterally blind. Visual function was preserved in the intranasal treatment group, while Hurler mice subjected to a hematopoietic stem cell transplantation treatment experienced vision loss.

Conclusions

Hurler mouse retinas are abnormal; abnormalities ranged from severe, in which the optic nerve fails to exit the eye and ganglion cell loss, to milder irregularities such as GAGs deposits and disorganization of the retinal layers. Intranasal treatment may have protective effects on vision in the treatment of Hurler's disease.

- 1) Muenzer J, Fisher A. Advances in the treatment of mucopolysaccharidosis Type I. N Engl J Med 2004;350:1932-1934.
- 2) Pitz S, Ogun O, Arash L, Miebach E, Beck M. Does enzyme replacement therapy influence the ocular changes in type VI mucopolysaccharidosis? Graefes Arch Clin Exp Ophthalmol 2009;247:975-980.
- 3) Pitz S, Ogun O, Bajbouj M, Arash L, Schulze-Frenking G, Beck M. Ocular changes in patients with mucopolysaccharidosis I receiving enzyme replacement therapy: a 4-year experience. Arch Ophthalmol 2007;125:1353-1356.
- 4) Schumacher RG, Brzezinska R, Schulze-Frenking G, Pitz S. Sonographic ocular findings in patients with mucopolysaccharidoses I, II, and VI. Pediatr Radiol 2008;38:543-550.